

## Stereological Analysis of the Dental Pulp in Patients with Advanced Periodontitis

Zahra Heidari,<sup>1</sup> Eshagh Ali Saberi,<sup>2</sup> Hamidreza Mahmoudzadeh-Sagheb,<sup>1</sup> Narges Farhad-Mollashahi,<sup>2</sup> Firouz Zadfatah\*<sup>2</sup>

1. Genetic of Non-communicable Diseases Research Center, Department of Histology, Zahedan University of Medical Sciences, Zahedan, Iran
2. Department of Endodontics, School of Dentistry, Zahedan University of Medical Sciences, Zahedan, Iran

Article information	Abstract
<p>Article history: Received: 9 May 2012 Accepted: 11 Jun 2012 Available online: 19 May 2013 ZJRMS 2013; 15(7): 44-49</p> <p>Keywords: Stereology Dental pulp Periodontitis Patients</p> <p>*Corresponding author at: Department of Endodontics, School of Dentistry, Zahedan University of Medical Sciences, Zahedan, Iran. E-mail: Firozadfatah@gmail.com</p>	<p><b>Background:</b> The adverse effects of periodontitis on dental pulp have long been argued. The purpose of this study was to investigate stereological indices of dental pulp in patients with advanced periodontitis compared with healthy people.</p> <p><b>Materials and Methods:</b> In this case-control study, 15 single-rooted permanent teeth of patients with advanced periodontal diseases and that of people with healthy periodontium, as control group, were investigated. All teeth were intact, and without filling and decay. After tissue processing, longitudinal serial sections of the tooth were prepared and stained by Masson's trichrome. A grid containing organized points superimposed on the images of each section randomly. Then, the points hit with each subject were counted. The volume of pulp and its components in both groups were estimated, using Cavalieri's principle. Data were analyzed using Mann-Whitney <i>U</i> test. The significance level was considered as <math>p &lt; 0.05</math>.</p> <p><b>Results:</b> No significant difference was observed between the groups in terms of inflammation and calcification intensity (<math>p &lt; 0.05</math>). Microscopic evaluations of tissue sections showed significant increase in predentin thickness in periodontitis group than control group (<math>p &lt; 0.05</math>). In addition, statistically significant reduction was observed in periodontitis group with respect to pulp absolute volume, volume density, odontoblastic layer absolute volume, collagen fibers absolute volume, and absolute pulp blood vessels volume, compared with control group (<math>p &lt; 0.05</math>).</p> <p><b>Conclusion:</b> Results showed periodontal disease affects stereological parameters of pulp. Because of reduction of pulp volume and narrowing of root canal, precise diagnostic and therapeutic considerations are recommended during treatment of those teeth.</p> <p>Copyright © 2013 Zahedan University of Medical Sciences. All rights reserved.</p>

## Introduction

Morphological and functional relationships between dental pulp and periodontium cause interference with the disease processes between these two tissues [1]. The main paths of communication between these tissues are the apical foramen, lateral and secondary canals, and open dentinal tubules, vascular and lymphatic pathways [2, 3].

Periodontitis is an infectious disease that leads to the destruction of the dental supporting tissues and cause tooth loss [4].

The effects of periodontal disease on the pulp are still a matter for debate [3]. Some studies have reported that there is no relationship between the extent of the pulp in periodontitis and healthy states. In a study histology of dental pulp in people with extensive range of periodontal destruction was reported as normal [5-7]. Hattler et al. showed that no pulp disease was observed in periodontal disease rat model [8].

The idea of association or development of pulp disease by periodontal disease was introduced by Colyer and Cahn [9]. Seltzer and Bender reported that the pulps of teeth with chronic periodontal disease had shown different degrees of fibrosis and mineralization [10]. Lateral canals exposed to the oral cavity by periodontal

disease may transport toxins to the pulp, causing degenerative changes and inflammation in the pulp [11]. Extensive periodontal treatments such as deep curettage can cause necrosis of the pulp [12]. Santly said that if the thickness of remained dentine between the pulp and the irritated region is 2 mm, it is less likely to destruction of the pulp of tooth [13]. Nemeč et al., have stated that dental canals with periodontal disease are narrower than teeth without periodontitis [14]. Ghoddosi et al. showed that increased periodontal pocket depth caused atrophied pulp vessels and homogenous increase in the dental pulp calcification [12]. It was found out that decrease in periodontal attachment had significant correlation with the presence of calcification in the pulp [15]. Several studies have reported that periodontal disease causes inflammation, fibrosis, calcification, degenerative changes, pulp necrosis, and root surface resorption [2, 3, 16, 17].

The difference in the results is probably stemmed from periodontal diagnostic criteria, pulp fixation difficulties, and lack of control group and haven't a specific histologic criteria for describing the mentioned evidence [2, 14]. Stereology is applicable for obtaining information and performing quantitative analysis based on evidence from

two-dimensional sections [18, 19]. It seems that using this method, the changes in the pulps, caused by different diseases, can be expressed quantitatively, precisely, and unbiased [19].

Previous studies have investigated the changes in the pulp with advanced periodontal disease qualitatively and reported different and debatable results. This study aims to precisely evaluate the changes in the pulp tissue in the teeth with advanced periodontitis, using a stereological method.

## Materials and Methods

In this case-control study, a total of 15 teeth, with advanced periodontitis, were collected from the case subjects (7 females and 8 males with average age of  $38.9 \pm 2.29$ ), referring to the Department of Periodontics of the Zahedan Dental Faculty. A number of 15 teeth were also collected as control group from the Department of Oral and Maxillofacial Surgery of the same faculty. The processes of teeth and tissue preparation, staining, and stereological analysis were carried out in Department of Histology of the Zahedan University of Medical Sciences (ZAUMS).

This study was approved by Ethics Committee of ZAUMS (No. 90-1056). The informed consent forms were signed by all participants, giving permission to obtain their removed teeth for this study.

All teeth were single-rooted and both groups were matched by gender and age. The case group included teeth with advanced periodontitis and hopeless prognosis. The control groups consisted of teeth without periodontal involvement, removed for the purpose of orthodontic or prosthetic treatments.

The exclusion criteria included: smoking, systematic diseases (such as rickets, diabetes, and hypertension), long-term use of any medication, previous periodontal treatment (like scaling or root planning), pregnancy, and dental history including trauma (bruxism or clenching).

Before removing the tooth, the physical examination of the mouth and radiography were performed, and only the teeth with natural crowns and without restoration and caries were included into the study.

The teeth were removed under deep anesthesia, and then the pulp was exposed by making a deep hole in pulp chamber. Teeth were immediately put in 10% formaldehyde solution for full fixation for at least 10 days. Then, they were cleaned and embedded in 5% nitric acid for the purpose of decalcification for about 45 days. To verify full decalcification, teeth radiography was performed. The samples were dehydrated, cleared and impregnated using Leica, TP 1010 tissue processor.

In order to perform stereological estimation, serial sections of the given tissue were prepared. For this, digital microtome (Leica Biosystems Nussloch GmbH; Model: RM 2255; Germany) was used. The first section was selected randomly between 0-200 microns. The subsequent 10-15 sections of each tooth were prepared using systematic uniform random sampling, spaced 200

microns from each other. Then, they were stained with Masson's Trichrome [16].

In order to project, the whole section image on the table, a micro projector was used. Point counting using the Cavalieri's principle was employed to estimate the volume of dental pulp. A grid was randomly placed on the projected image of the tissue (Fig. 1), and the number of points hit with different structures of the pulp was counted. The following formula was deployed to estimate the volume of collagen fibers, blood vessels, dentin, pulp, and odontoblastic layer [18, 20].

$$\text{estV} = \frac{\sum_{i=1}^m P_i \cdot a_i / p_i \cdot \bar{t}}{M^2}$$

Where estV is estimation of the volume,  $\sum P$  is the sum of the number of points landing within the profiles,  $a/p$  is the area associated with each point,  $t$  is the distance between sections and  $M$  is the magnification [20].

Then an estimate of the volume density,  $V_v$ , of the components in the reference space (dental pulp) was obtained using:  $\text{estV}_v = P(\text{part})/P(\text{ref})$  where  $P(\text{part})$  and  $P(\text{ref})$  are the number of test points falling in all structure profiles and in the reference space, respectively.

To evaluate the degree of calcification and inflammation of the section before or after previous selected section, each sample was stained using hematoxylin-eosin. Then, the structure of the pulp was examined using an optical microscope. Yaltirik et al. categorized the inflammation into three degrees, namely mild, moderate, and severe [21]. Histological calcification were divided into single, multifocal, and diffuse categories and compared in two groups [9].

The mean and standard error of absolute and volume density of different parts of the dental pulp in two groups were calculated. The stereological indices of the patient and control groups were compared with non-parametric Man-Whitney  $U$ -test using SPSS-16. In case of  $p < 0.05$ , the difference between groups was considered significant.

## Results

The comparison between stereological parameters of the pulp of tooth in advanced periodontitis group and control. Quantitative parameters of dental pulp in advanced periodontitis and control groups are presented in table 1. The stereological investigation revealed a significant reduction in the absolute volume of pulp ( $p < 0.01$ ) and volume density of pulp to surrounding dentin in periodontitis group ( $p < 0.001$ ) compared with control group. This acceleration is confirmed when increased predentin thickness is evident.

In two cases from advanced periodontitis group, a mild inflammation was seen. Figure 2 shows the histological status of the pulp of tooth with advanced periodontal disease. In this figure, venous hyperemia and moderate infiltration of inflammatory cells are evident.

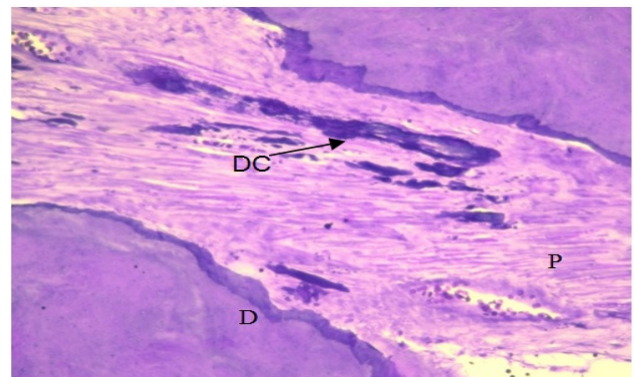
**Table 1.** Quantitative parameters of dental pulp in advanced periodontitis and control groups

Stereological parameters		Groups	Advanced periodontitis (Mean±SD)	Control (Mean±SD)	p-Value
Pulp tissue	Total volume(mm <sup>3</sup> )		4.3±0.65	14.4±2.54	0.002
	Volume density/ Dentin volume (%)		6.9±0.87	16.9±2.4	0.001
Odontoblastic layer	Total volume(mm <sup>3</sup> )		0.57±0.09	1.9±0.31	0.001
	Volume density (%)		13.9±1.27	14.4±0.87	0.756
Collagen fibers	Total volume(mm <sup>3</sup> )		0.23±0.03	0.9±0.18	0.003
	Volume density (%)		5.7±0.44	6.2±0.70	0.514
Blood vessels	Total volume(mm <sup>3</sup> )		0.12±0.02	0.35±0.07	0.009
	Volume density (%)		2.9±0.32	2.5±0.28	0.320
Dentin	Total volume(mm <sup>3</sup> )		63.7±6.22	82.4±11.06	0.331


No significant difference was observed between advanced periodontitis group and control group in terms of the degree of pulp inflammation.

One case of denticle and two cases of diffuse calcification were seen in the periodontitis group. There was no statistically significant difference between the groups in terms of calcification. Figure 3 illustrates diffuse calcification in a tooth with advanced periodontitis.

In microscopic study of the tissue sections, increased thickness of predentin in periodontitis group, compared with control group, was significant. In Figures 4 and 5, thickened predentin (P) layer and odontoblastic (O) layer are observed.



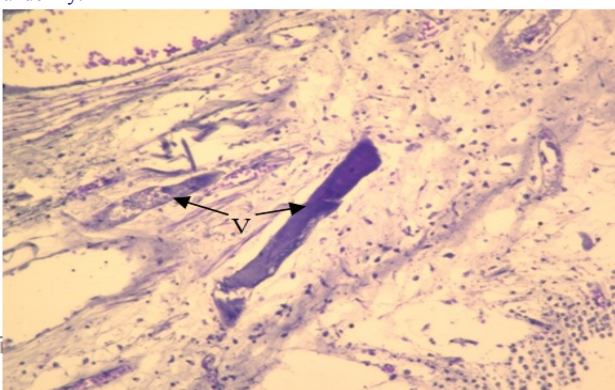
**Figure 3.** Diffused calcification (DC) pulp (P) and dentin (D) in advanced periodontitis. (H&E, Mag: 100)



**Figure 1.** An organized point's grid superimposed on dental pulp randomly.



**Figure 4.** Dental pulp in advanced periodontitis, thick predentin and odontoblastic layer (OL). (Masson's trichrome, Mag: 100)



**Figure 2.** Dental pulp in advanced periodontitis. Congestion of vessels (V) and moderate inflammatory cells infiltration is seen (H&E, Mag: 100)



**Figure 5.** Dental pulp in advanced periodontitis, thick predentin (P) and odontoblastic layer (OL). (Masson's trichrome, Mag: 400)

## Discussion

In this study, a decline was seen in the total volume of the pulp in periodontitis group, accompanied with respective reduction of its components. Due to the increased degree of dentinogenesis, the thickness of predentin in periodontitis group was higher. In addition, the level of inflammation and calcification rose in periodontitis group. Several studies have been conducted on pulpal histology of the teeth with periodontal disease [6, 7, 11]. Lack of a matched control group is among the disadvantages of these studies. Therefore, sex and age matching can demonstrate whether pulpal changes are due to periodontal disease, aging, and/or technical difficulties caused by fixation and the process of pulpal tissue preparation [6, 22]. Czarnecki et al. showed that previous periodontal treatment history may cause changes in pulpal tissue [6]. Therefore, selecting matched subjects for case and control groups is remarkably important.

Several techniques have been used to fix dental pulps. Langeland [23] in his studies had immediately embedded the removed tooth in formalin which is inadequate for pulpal fixation [23]. Schilder, Czarnecki, and Torabinejad in their investigations on pulpal fixation, have resected the apex-end of the tooth and embedded it in formalin. In this technique, epical tissue of the pulp is destructed [6]. Other researchers such as Ghoddusi et al. [12] made some incisions throughout the tooth with a clasp for better penetration of fixative substance into the pulp. In the present study, pulp was carefully and partially exposed, using bur under water-air spray, for better penetration of fixative into the tooth while the total volume of the pulp was preserved.

The relationship and effect of periodontal diseases on pulpal tissue is a matter of debate by researchers. Some of them like Maur et al., reject the relationship between pulpal and periodontal diseases and attribute pulpal degeneration to systematic reasons [5]. In contrast, some others such as Rubach, Seltzer, and Langeland maintain that periodontal disease is associated with pulpal disease, even as the main cause, and can lead to inflammation, fibrosis, calcification, necrosis degenerative changes, and even root surface resorption [16, 24, 25].

Haith, Langeland, and Qoddosi confirmed the effect of periodontal diseases on the pulp status [17, 23, 26], but studies by Schilder, Czarnecki, Massler, Mazur, and Torabinejad do not support the impact of periodontal diseases on the pulp [5, 6, 7]. The difference in the results may be due to diagnostic criteria for periodontal diseases, pulp fixation-related problems, and lack of control group and certain histologic criteria for describing the observations [2, 14]. Stereology is among statistical and mathematical techniques, by which 3-dimensional structural information can be obtained from 2D sections (or tissue incisions). Therefore, researchers can attain significant quantitative structural information such as volume and/or cells number, using this technique. Quantitative data in biologic studies where the effects of different therapeutic methods on a specific tissue, organ, or cell are investigated is central [27].

The stereological technique, used in this study, is based on Cavalieri's principle which is employed in histologic and pathologic investigations for obtaining precise and not-biased estimation of anatomic and pathologic structures. The previous studies have investigated pulpal changes of the teeth with advanced periodontal diseases qualitatively, leading to different and debatable results. Therefore, in the present case-control study, we evaluated this subject quantitatively using stereological technique.

In the present research, mild to moderate pulpal inflammation was observed in one-fifth of the samples. Seltzer and Bender reported pulpal inflammation in 37% of cases which was almost in consistent with our findings.

In the present study, microscopic investigation into tissue sections revealed a significant increase in predentin thickness in periodontitis group compared with control group. In addition, absolute volume of the pulp, volume density of the pulp to surrounding dentine, absolute volume of odontoblastic layer, absolute volume of collagen fibers, and volume of blood vessels of the pulp experienced a significant reduction in the periodontitis group. In contrast, volume density of odontoblastic layer, blood vessels, and collagen fibers did not significantly change compared with total volume of the pulp. Therefore, the observed reduction of absolute volume is due to the significant decline in the volume of the pulp caused by dentinogenesis acceleration and narrowing of canal. Acceleration of dentinogenesis is confirmed when increased predentin thickness is evident.

Lovschall et al. have shown that intact pulps frequently add to dentinal wall in response to external stimulations and changes in internal environment of the oral cavity [28]. Moreover, Lantelme and Seltzer et al. have stated that periodontal diseases along with bending and abrasive stresses are among the factors that cause change in internal structure of the tooth [24, 29]. In the present study, the periodontitis group had narrower pulpal cavity than control group, and significant reduction in the absolute and volume density of the pulp was observed.

Bender and Seltzer [10], Lantelme et al. [29], and Nemeč et al. [14] in their studies have stated that the canals of the teeth with periodontal disease are narrower than intact teeth. This is in consistent with our findings.

In a study by Ghoddosi et al. on 32 single-rooted teeth with periodontal disease it was determined that increased periodontal pocket depth caused tangible increase in the number of inflammatory cells. In addition, increased periodontal pocket depth led pulp vessels becoming atrophied and caused homogenous increase in calcification of dental pulp [12]. In this study as well the degree of inflammation and calcification was higher in periodontitis group. However, this difference was not statistically significant.

Sheikh-Rezaei et al., investigated the histopathological changes of the pulp in the patients with advanced periodontitis and concluded that increased pocket depth led to pathologic changes in the pulp and enhanced degrees of fibrosis, calcification, inflammation, and necrosis [9].

In the present study as well, greater degrees of calcification and inflammation were observed in periodontitis group. However, absolute volume of collagen fibers experienced a reduction in periodontitis group, while volume density did show significant change. In effect, decreased absolute volume of collagen fibers is due to significant decline in pulp volume caused by so much dentinogenesis in the periodontitis group. The above study has been done qualitatively. Detailed and quantitative investigation into the components of dental pulp by means of stereological technique is the strength of the present study. In fact, some researchers like Lovschall and Hilmann have reported that increased fibrosis in aged teeth is to some extent due to canal narrowing without losing fibrosis tissue, leading to its superficial accumulation [28, 30]. Thus, the fibrosis observed in periodontitis group previous studies may be due to decreased pulp volume and compressed-like collagen fibers.

Mogharehebed et al., in a histological investigation into 42 periodontitis anterior teeth, with 2-8 mm attachment loss and without caries, restoration, and root canal treatment, found 13 cases (31%) with natural pulp and 29 cases (69%) with a type of pulpal involvements. They concluded that advanced periodontal disease might lead to inflammation, osteitis, and degenerative atrophic changes in the pulp. These cases were observed in the present study; however, the difference was not significant [31].

In conclusion, it can be said that advanced periodontal disease most often affects dental pulp. However, pathologic changes in the pulp are not necessarily indicator of severity of PDL infection and destruction. According to the previous reports, the presence of severe periodontal involvements may only cause mild changes in dental pulp [6, 24]. The condition of dental pulp is probably more associated with advanced periodontal disease duration than its severity [32]. In general, pulpal changes can risk root treatment of these teeth. Therefore, during periodontal treatment, curing pulpal damages should be also taken into consideration, if needed.

Based on the present study, periodontal disease impacts stereological indicators. In addition, regarding the

significant reduction of the pulp volume and narrowing of root canal, precise diagnostic and therapeutic considerations are suggested for performing treatment on these teeth. Moreover, stereological examination of other factors, affecting the pulp of tooth, such as age, diabetes, and other chronic disease is recommended. Given that the tissue of pulp is surrounded by dentine and enamel, improvement of dental fixation methods with no damage to the structure of the pulp requires more investigation and attempts.

### Acknowledgements

The authors of this article appreciate the Vice Chancellor of Research and Technology of Zahedan University of Medical Sciences for great assistance and facilities to develop the project, and also thank the experts of Department of Histology of Zahedan University of medical sciences for their technical cooperation. This article is extracted from thesis of a university research dissertation (residency thesis of Dr. Firouz Zadfatih, in department of endodontics of Zahedan University of Medical Sciences (No. 110-T).

### Authors' Contributions

Z Heidari and H Mahmoudzadeh-Sagheb conceived and co-designed the study, supervised all the experimental design, analyzed the results, and drafted the manuscript. EA Saberi and N Farhad-Molashai contributed in study design, supervised the sample collection of periodontitis patients and healthy controls and participated in the interpretation of the results. F Zadfatih contributed in literature review, sample collection, histological procedure and drafted the manuscript. All authors read, modified and approved the final version of the manuscript.

### Conflict of Interest

The authors declare no conflict of interest.

### Funding/Support

Vice Chancellor of Research and Technology and Department of Histology of ZAUMS.

### References

1. Deva V, Vatuman M, Manolea H. Modifications of the dental pulp in marginal periodontitis. *Electronmicroscopical contributions*. Rom J Morph Embryol 2006; 47(1): 67-71.
2. Hargreaves K, Goodis H. Seltzer and Bender's dental pulp. 4<sup>th</sup> ed. Chicago: Quintessence Press; 2002.
3. Cohen S, Hargreaves KM, editors. Pathways of the pulp. 10<sup>th</sup> ed. New York: Mosby; 2011.
4. Newman MG, Takei HH, Klokkevold PR, editors. Carranza's clinical periodontology. 10<sup>th</sup> ed. Missouri: WB Saunders; 2006.
5. Mazur B, Massler M. Influence of periodontal disease on the dental pulp. *Oral Surg Oral Med Oral Pathol* 1964; 17: 592-603.
6. Czarnecki RT, Schilder HA. Histological evaluation of the human pulp in teeth with varying degrees of periodontal disease. *J Endod* 1979; 5(8): 242-253.
7. Torabinejad M, Kiger RD. A histologic evaluation of dental pulp tissue of a patient with periodontal disease. *Oral Surg Oral Med Oral Pathol* 1985; 59(2): 198-200.
8. Hattler AB, Snyder DE, Listgarten M and Kemp W. The lack of pulpal pathosis in rice rats with the periodontal syndrome. *Oral Surg Oral Med Oral Pathol* 1979; 44(6): 939-948.
9. Sheykhrezaee MS, Eshghyar N, Khoshkhounejad AA and Khoshkhounejad M. Evaluation of histopathologic changes of dental pulp in advanced periodontal disease. *Acta Medica Iranica* 2007; 45(1): 51-57.
10. Bender IB, Seltzer S. The effect of periodontal disease on the pulp. *Oral Surg Oral Med Oral Pathol Oral Radiol Endod* 1977; 33(3): 458-74.
11. Seltzer S, Bender IB, Zions M. Interrelationship of the pulp and periodontal disease. *Oral Surg Oral Med Oral Pathol* 1963; 16: 1474-78.

12. Ghoddusi J, Bidar M, Salehinejad J and Hafez MT. Histological evaluation of pulpal status in patients with periodontal diseases. *J Mashhad Dent Sch* 2004; 27(3): 150-154.
13. Walton R, Torabinejad M. Principles and practice of endodontics. 4<sup>th</sup> ed. Philadelphia: WB Saunders; 2008: 442.
14. Nemeč A, Pavlicu Z, Stiblar-Martincic D, et al. Histological evaluation of the pulp in teeth from dogs with naturally occurring periodontal disease. *J Vet Dent* 2007; 24(4): 212-223.
15. Seyedmajidi M, Khosravi M, Bijani A and Babak M. Histopathological effect of advanced periodontal disease on the dental pulp. *Shiraz Univ Dent* 2011; 12(3): 233-238.
16. Langeland K, Rodrigues H, Dowden W. Periodontal disease, bacteria, and pulpal histopathology. *Oral Surg* 1974; 37(2): 257-270.
17. Ghoddusi J. Ultrastructural changes in feline dental pulp with periodontal disease. *Microsc Res Tech* 2003; 61(5): 423-427.
18. Noori-Mugahi SM, Mahmoudzadeh-Sagheb HR, Heidari Z. Applied method and terminology of histotechnology, stereology & morphometry. 3<sup>rd</sup> ed. Tehran: Tehran University of Medical Sciences; 2009: 221.
19. Noori- Mugahi SMH, Heidari Z, Mahmoudzadeh-Sagheb HR, et al. Stereological essentials. 1<sup>st</sup> ed. Tehran: Tehran University of Medical Sciences; 2010: 65.
20. Heidari Z, Mahmoudzadeh-Sagheb HR, Kohan F. A quantitative and qualitative study of rat testis following administration of methadone and buprenorphine. *Int J High Risk Behav Addict* 2012; 1(1): 12-5.
21. Yaltric M, Ozbas H, Bilgic B and Issever H. Reactions of connective tissue to mineral trioxide aggregate and amalgam. *J Endod* 2004; 30(2):95-99.
22. Belk CE, Gatmann JL. Perspectives, controversies and directives on pulpal-periodontal relationships. *J Can Dent Assoc* 1990; 56(11): 1013-1017.
23. Langeland K, Langeland LK. Histologic study of 155 impacted teeth. *Odontol Tidskr* 1965; 73(5): 527-549.
24. Seltzer S, Bender IB. The dental pulp; biologic considerations in dental procedures 3<sup>rd</sup> ed. St. Louis: Ishiyaku Euro America; 1990: 78-128, 303-360.
25. Rubach WC, Milchell DF. Periodontal disease, accessory canals and pulp pathosis. *J Periodontol* 1965; 36: 34-38.
26. Haitt WH. Pulpal periodontal disease. *J Periodontol* 1977; 48(9): 598-609.
27. Altunkaynak BZ, Ozbek E, Altunkaynak ME. A stereological and histological analysis of spleen on obese female rats, fed with high fat diet. *Saudi Med J* 2007; 28(3): 353-357.
28. Lovschall H, Fejeskow O, Josphen K. Age-related odontogenic changes in the pulpodentinal morphology of rat molars. *Arch Oral Bio* 2002; 47(5): 361-367.
29. Lantelme RL, Handelman SL, Herbison RJ. Dentin formation in periodontally diseased teeth. *J Dent Res* 1976; 55(1): 48-51.
30. Hilmann G, Geurtsen W. Light-microscopical investigation of the distribution of extracellular matrix molecules and calcifications in human dental pulp of various ages. *Cell Tissue Res* 1997; 289(1): 145-154.
31. Mogharehabet A, Karimi H. Effect of advanced periodontal disease on pulpal status. *J Isfahan Dent Sch* 2006; 2(1): 32-35.
32. Bergenholts G, Lindhe J. Effect of experimentally induced marginal periodontitis and periodontal scalling on the dental pulp. *J Clin Periodontol* 1978; 5(1): 59-73.

**Please cite this article as:** Heidari Z, Saberi EA, Mahmoudzadeh-Sageb H, Farhad-Mollashahi N, Zadfatāh F. Stereological analysis of the dental pulp in patients with advanced periodontitis. *Zahedan J Res Med Sci (ZJRMS)* 2013; 15(7): 44-49.