

Tanaffos (2007) 6(3), 75-78

©2007 NRITLD, National Research Institute of Tuberculosis and Lung Disease, Iran

A 28-Year-Old Man with Chronic Cough and Dyspnea

Jafar Aslani¹, **Seyed Mohammad Reza Hashemian**², **Sima Salami**², **Hale Frootan**², **Samine Noroozi**², **Zohreh Mohammad Taheri**², **Seyed Davood Mansoori**^{2,3}

¹ Department of Internal Medicine, Division of Pulmonary Disease, Baqiyatallah Medical Sciences University, ² Department of Internal Medicine, Division of Infectious Disease and Clinical Immunology, ³ Lung Transplantation Research Center, NRITLD, Shahid Beheshti University M.C., Tehran-Iran.

WHAT IS YOUR DIAGNOSIS?

A 28 year - old man presented with productive cough and mild dyspnea for the past seven years, which have been aggravated in recent months. He was single and lives with his parents (who are first maternal cousins) and his brother and three sisters. He does not have any major medical or surgical history. He does not have any history of transfusion, allergy, or drug abuse. He had smoked one pack of cigarette per 2.5 years but quit three years ago. His work was crafting gold jewelry and also building construction since the age of twenty. There was no important family history. Clinical exam was entirely normal and the results of pulmonary function tests (PFT) and chest plethysmography (performed twice) were normal.

Blood leukocyte count, differential, hemoglobin, platelet, biochemistry, electrolytes, renal and liver function tests were all in normal limits. PPD was negative. Echocardiography was normal. CT of the paranasal sinuses was normal. Chest x- ray (Figure 1) and lung HRCT (Figure 2) were performed. (Tanaffos 2007; 6(3): 75-78)

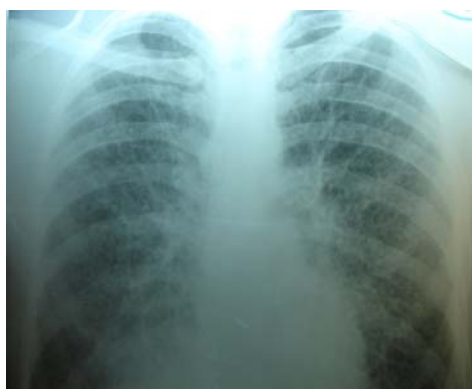

Figure 1. CXR of patient

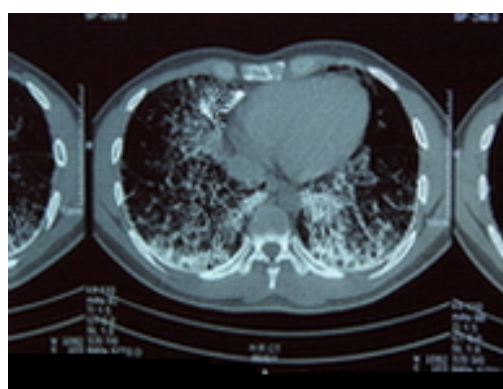


Figure 2. CT- Scan of patient

Correspondence to: Mansoori SD

Address: NRITLD, Shaheed Bahonar Ave, Darabad, TEHRAN 19569, P.O:19575/154, IRAN

Email address: dmansouree@yahoo.com