

# *Cone Beam Tomography (CBCT) as a Diagnostic Tool to Assess the Relationship between the Inferior Alveolar Nerve and Roots of Mandibular Wisdom Teeth*

**Feras Yabroudi - BDS, MSc, PhD**

Oral and Maxillofacial Surgeon, Assistant Professor Department of Oral & Maxillofacial Surgery, Nicolas & Asp University College, Dubai Healthcare City, Dubai – UAE - dr\_feras\_yab@hotmail.com

**Steen Sindet-Pedersen - DDS, Dr. Med. Sci**

Oral And Maxillofacial Surgeon, Professor Department of Oral & Maxillofacial Surgery, Nicolas & Asp University College, Dubai Healthcare City, Dubai – UAE

## ABSTRACT

This study was undertaken to evaluate the relationship between the mandibular third molar and the mandibular canal by cone-beam computed tomography with coronal and sagittal reconstruction before mandibular third molar surgery.

**Materials & Methods:** Forty seven mandibular third molars in 30 patients were found in close association with the mandibular canal during a panoramic radiographic assessment. The 3-dimensional relationship between the mandibular third molar and the mandibular canal was evaluated in each case by using cone- beam computed tomography.

**Results:** Of the Forty seven wisdom teeth in close relationship with the mandibular canal, eight mandibular canals were buccal to the third molars, eleven were lingual, 21 were inferior, and seven were between the roots. CBCT was more accurate than panoramic radiographs in demonstrating the presence or absence of cortical bone separating the root and the nerve.

**Conclusion:** Cone Beam Computed Tomography provides useful information regarding the 3-dimensional relationship between the mandibular third molar and the mandibular canal. Thus it can be used for risk assessment and planning of the surgical procedure.

## KEYWORDS

Cone beam CT, Panoramic radiography, Third molar surgery, Inferior nerve injury, Third molar position.

## INTRODUCTION

The removal of mandibular third molars may cause dysesthesia or loss of sensation due to damage to the inferior alveolar nerve during the operation.<sup>3</sup> Several factors are considered to be associated with nerve damage.<sup>1-3</sup> It is known that the risk dramatically increases when there is direct contact between the nerve and the roots of the third molar,<sup>3,4</sup> i.e. no cortical bone lamella separating the two. Thus, it is important to evaluate the anatomic relationship between the mandibular canal and the roots of third molars when surgery to be considered.

Panoramic radiographs are most commonly used for this purpose,<sup>5</sup> and many researchers have reported imaging features suggestive of an intimate relationship between the 2 structures.<sup>5</sup> Sedaghatfar et al.<sup>5</sup> recently reported a retrospective study that showed the following 4 panoramic features were significantly associated with inferior alveolar nerve exposure following third molar removal:

1. Darkening of the root
2. Interruption of the white line of the mandibular canal wall
3. Diversion of the mandibular canal
4. Narrowing of the root

Due to the fact that panoramic radiographs only produce a two-dimensional image of a three-dimensional relationship between the structures it has been recommended that when the panoramic image is suggestive of an intimate relationship between the impacted tooth and the mandibular canal, conventional CT-scan should be used as an additional investigation to demonstrate the three-dimensional relationship between the two structures.<sup>4,6-8</sup>

However, one of the disadvantage of conventional CT is the much higher radiation dose that the patient receives compared with panoramic radiography<sup>14</sup> (Table 1).<sup>4,6-9</sup>

**(Table 1)** Comparison of the effective dose of different radiographic sources and as a percentage of the annual per capita background X-ray dose

Radiographic source	Effective dose (ISv)		Dose as a % annual background radiation
	ICRP 1990	ICRP 2005	
Cone beam computed tomography CBCT <sup>28,30</sup>	7.2 – 435.5		0.2 – 12.1
Conventional computed tomography Conventional CT31	1400 (max)	1320 (mand)	38.9% 36.7%
<b>Conventional Radiography</b>			
Panoramic <sup>29</sup>	6.3		0.2%
Periapical <sup>31</sup>	5		0.14%
Maxillary occlusal <sup>31</sup>	7		0.2%
Cosmic radiation on board an aircraft flying a round trip between Paris & Tokyo <sup>32</sup>	150		4.2%

**ICRP:** The International Commission on Radiological Protection issued its last basic recommendations in 1990 and 2005

Other disadvantages include limited access to CT-scans and the relatively high costs of the procedure. Following the recent introduction of maxillofacial cone beam CT (CBCT), three-dimensional imaging is becoming more readily available for use in dental applications. The major advantages of cone-beam CT include high spatial resolution and low radiation dose compared to conventional CT.<sup>10</sup> Applying CBCT as a diagnostic tool in areas such as dental implantology, endodontics, dentoalveolar pathology and evaluation of anatomical relationship between wisdom teeth and the inferior alveolar nerve have been reported.<sup>10-14</sup>

## MATERIALS & METHODS

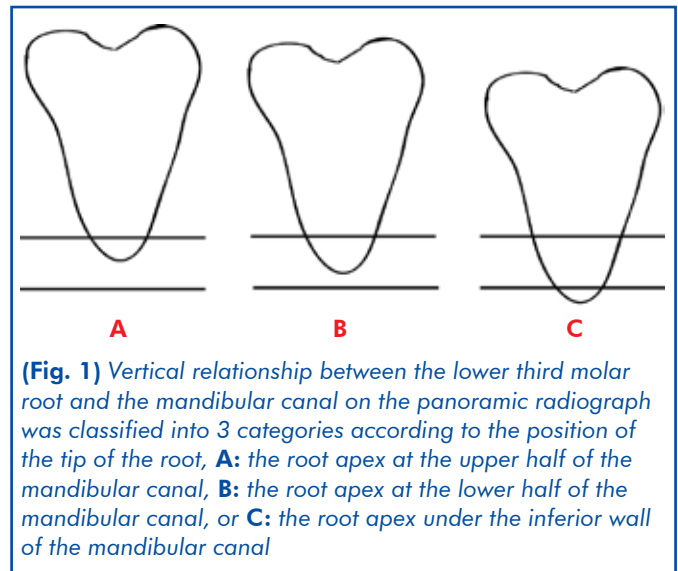
Thirty patients (21 women and 9 men, 18-35 years of age) (47 mandibular wisdom teeth) with preoperative panoramic radiographs suggesting close relationship with the Inferior Alveolar Nerve (IAN). The Panoramic radiographs were taken with Kodak 8000C and the cone-beam computed tomographs (CBCT) were taken using a Kodak 9500C 3D cone beam system. The exposure factors were set at 120kV, and the slice thickness of contiguous sections was 1mm.

The surgical procedures involve where to remove bone, how to section the crowns and the root sockets, direction of removal of roots as well as identification of areas involving high risk of damaging the IAN were determined and made the basis for planning the surgical procedure, in this way aiming at minimizing the risk of iatrogenic nerve lesions.

### Evaluation of the panoramic radiographs and computed tomographs

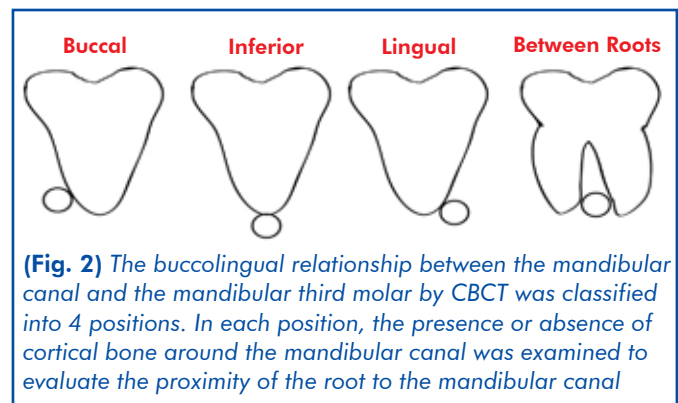
Vertical relationship between the lower third molar root

and the mandibular canal on the panoramic radiograph was classified into 3 categories according to the position of the tip of the root, **A**) the root apex at the upper half of the mandibular canal, **B**) the root apex at the lower half of the mandibular canal, or **C**) the root apex under the inferior wall of the mandibular canal (**Fig. 1**).



The panoramic radiographs were also evaluated with respect to presence or absence of cortical bone separating the nerve and the root.

The positional relationship between the mandibular canal and the impacted third molar revealed through the computed tomograph was classified in terms of the position into 1 of the 4 following categories: Buccal, inferior, lingual, or between roots. The root of the lower third molar was considered to be in contact with the neurovascular bundle in the mandibular canal when loss of the cortical lining of the mandibular canal was observed on the axial and coronal computed tomographs (**Fig. 2**).



## RESULTS

Panoramic radiographs suggested 47 teeth 21 women and 9 men, 18-35 years of age with close relationship with IDN Vertical relationship between the mandibular

third molar root and the mandibular canal in these teeth was 20(42.55%) with type A, 18(38.29%) with type B and 9(19.14%) were type A, B, and C (Fig. 1), respectively.

Locations of the mandibular canal in relation to the mandibular third molars as demonstrated by CBCT in the included cases were:

8(17.02%) mandibular canals were in the buccal position, 21(44.68%) were in the inferior position, 11(23.4%) were lingual, and 7(14.89%) were between the roots (Fig. 2). The mandibular canal was in contact with the root surface of 12 teeth (i.e., there was no cortical bone separating the mandibular canal and the root (Table 2). There was an obvious difference between the two radiographic methods ability to detect presence of cortical bone between the root and the IAN, CBCT giving more accurate information.

**(Table 2)** Comparison of panoramic radiographs and CBCT with respect to ability to identify presence or absence of cortical bone separating the root and the IAN

N= 47	+ Cortical separation	- Cortical separation	Uncertain
OPG	20	10	17
CBCT	35	12	0
Difference between OPG & CBCT	15	2	17

Chi square testing demonstrates significant differences ( $p=.000$ ) in detection of cortical bone separating the nerve and the root between CBCT and OPG

**CASE REPORTS**

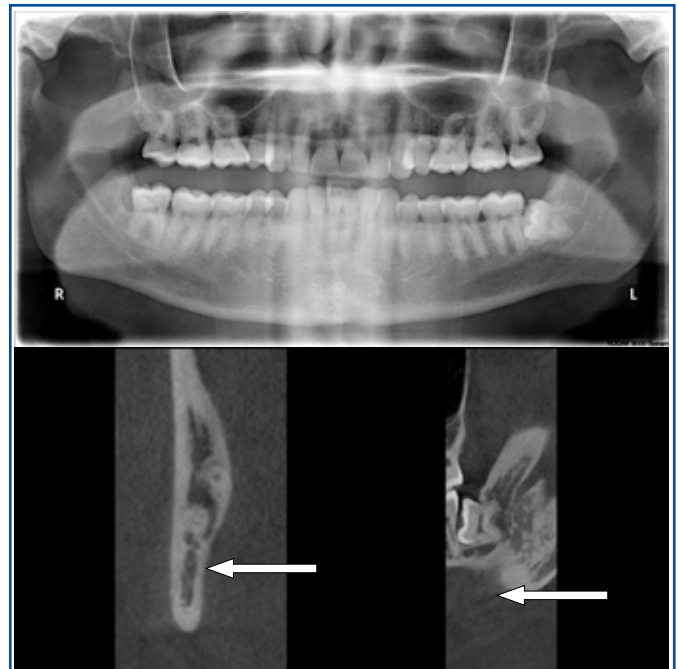
**CASE 1 (Between Roots)**

A left lower third molar root was located under the inferior wall of the mandibular canal.

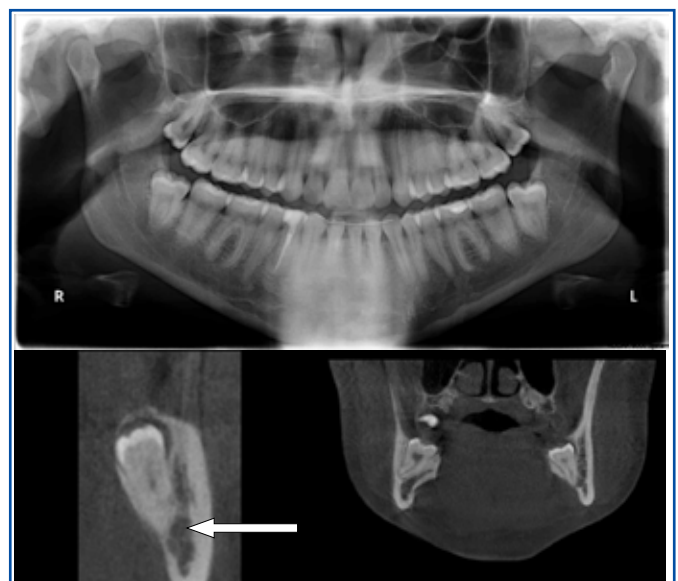The white line of the cortical bone of the mandibular canal and the black line of the periodontal membrane space were not clearly seen on a panoramic radiograph. The cortical bone surrounding the mandibular canal was not present on the computed tomograph. The inferior alveolar nerve was exposed in the surgical field during the procedure, however, the patient had normal sensory function in the IAN and mental nerve following the procedure. (Fig. 3)

**CASE 2 (Buccle Position)**

In this patient, a left lower third molar root was located in the upper half of the mandibular canal, and the white line of the cortical bone of the mandibular canal and the black line of the periodontal membrane space were clearly seen on a panoramic radiograph (Fig. 4A). CBCT revealed that the mandibular canal was located at the buccal aspect of the root, and the white lines of the mandibular canal were clearly seen; moreover, there was a space between the root and the mandibular



(Fig. 3) A: The cranial and caudal borders and periodontal membrane space of the left lower third molar are not clearly seen on the panoramic radiograph. B: Axial and C: coronal computed tomographs reveal that the mandibular canal is located between the buccal and the lingual roots; also there is no cortical bone around the IAN



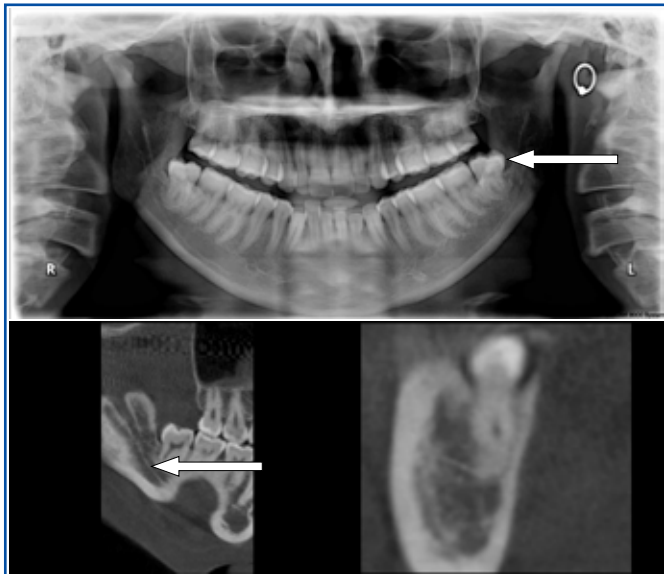(Fig. 4) A: The panoramic radiograph with collimation on the left molar area reveals that the root apex is superimposed on the cranial border of the mandibular canal and B,C: On the computed tomographs clearly showed buccal position of the mandibular canal in coronal views

canal. However, the lingual cortical bone was very thin (Fig. 4B,C). No nerve injuries were present after the procedure.

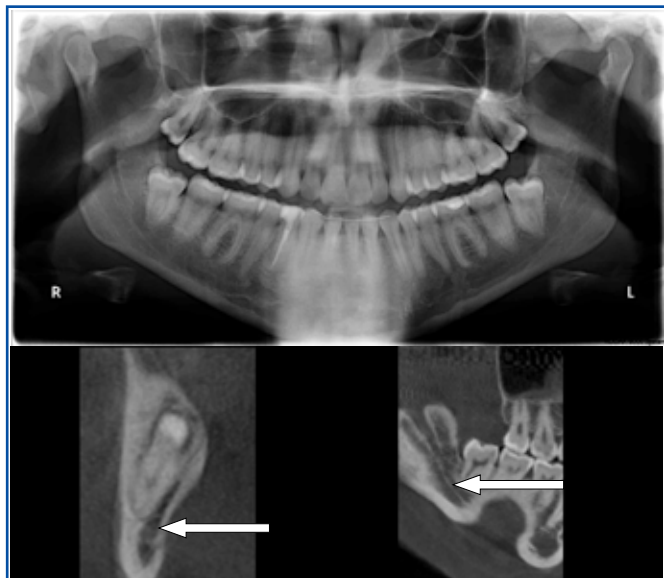
**CASE 3 (Inferior Position)**

A right lower third molar root was located above the inferior wall of the mandibular canal.

The white line of the cortical bone of the mandibular canal and the black line of the periodontal membrane space were not clearly seen on a panoramic radiograph. The cortical bone surrounding the mandibular canal was not present on the computed tomograph. The inferior alveolar nerve was not exposed in the surgical field during the procedure, however, the patient had normal sensory function in the IAN and mental nerve following the procedure. (Fig. 5)



(Fig. 5) A: The panoramic radiograph with collimation on the right molar area reveals that the root apex is superimposed on the cranial border of the mandibular canal and B,C: on the computed tomographs clearly showed inferior position of the mandibular canal in coronal views



(Fig. 6) A: The panoramic radiograph with collimation on the right molar area reveals that the root apex is superimposed on the cranial border of the mandibular canal and B,C: on the computed tomographs clearly showed lingual position of the mandibular canal in coronal views

#### CASE 4 (Lingual Position)

A right lower third molar root was located in the upper half under of the mandibular canal.

The white line of the cortical bone of the mandibular canal and the black line of the periodontal membrane space were clearly seen on a panoramic radiograph. The cortical bone surrounding the mandibular canal was not present on the computed tomograph. The inferior alveolar nerve was not exposed in the surgical field during the procedure, however, the patient had normal sensory function in the IAN and mental nerve following the procedure. (Fig. 6)

#### DISCUSSION

Dysesthesia and paraesthesia caused by inferior alveolar nerve injury during the surgical removal of mandibular third molars often disappears within a few months; however, it can be very distressing, if it is permanent.<sup>3</sup> The risk of development of postoperative dysesthesia increase if the mandibular canal and the tooth root are in proximity. The incidence of inferior alveolar nerve injury after surgical removal of mandibular third molars has been reported to be between 0.4% and 5.2%.<sup>1,3,6,21,23-25</sup>

In general, a panoramic radiograph can help to determine the location of the mandibular canal; however, this technique provides limited information because it only provide a 2-dimensional image so sufficient diagnostic information related to the actual 3-dimensional anatomy is lacking with this method (eg, the presence or absence of cortical bone around the mandibular canal, the buccolingual relationship between the mandibular canal and the lower third molar, and the detailed shape of the root might not be clearly evident on a panoramic radiograph).

Although panoramic images cannot provide three dimensional information, numerous clinical studies<sup>4-6,16-19</sup> have been performed to determine signs predictive of intraoperative neurovascular bundle exposure during surgery or postoperative dysesthesia/paraesthesia.

Rood and Shehab<sup>17</sup> found that diversion of the canal, darkening of the root, and interruption of the white line corresponding to the cortical bone of the mandibular canal on periapical and panoramic radiographs were significant signs related to risk of inferior alveolar nerve injury. Rud<sup>9</sup> and Kipp *et al.*<sup>3</sup> reported similar findings.

Sedaghatfar *et al.*<sup>5</sup>, - in a recently conducted retrospective study, reported the following four features: **1)** darkening of the root, **2)** interruption of the white line of the mandibular canal wall, **3)** diversion of the mandibular canal, and **4)** narrowing of the root were significantly associated with inferior alveolar nerve exposure at surgery. The sensitivity and specificity of



these features ranged from 42% to 75% and 66% to 91%, respectively.<sup>5</sup> However, they did not determine the optimal diagnostic criteria for panoramic images in predicting exposure. Bell *et al.*<sup>18</sup> reported that the sensitivity and specificity of panoramic images in predicting exposure were 66% and 74% on average, respectively. They also reported that these values varied widely among observers and emphasized the need for further standardization of diagnostic criteria. To our knowledge, there have been few studies that clearly defining diagnostic criteria for panoramic images in predicting neurovascular bundle exposure and evaluated the accuracy of such criteria.

Computed Tomography provides surgeons with useful and relevant anatomical information, due to the high resolution of CT.<sup>2-4</sup> The usefulness of conventional CT in evaluating the topographic relationship between the mandibular canal and the third molars has been reported.<sup>4,6-8</sup> However, there are few studies that correlated CT findings with surgical outcome with respect to nerve injuries. Thus, accurate preoperative determination of neurovascular bundle position and its relationship to the roots of wisdom teeth in all 3 dimensions is very useful for predicting potential risk of injuring the inferior alveolar nerve during surgery. Also, this information is very useful when informing the patient about surgical risks and obtaining informed consent experimental studies have confirmed the geometric accuracy of cone-beam CT.<sup>20-22</sup>

Due to the recent development and spread of Cone Beam CT, three-dimensional images are becoming more easily available in dentistry.

CBCT has recently been described for use in various clinical fields such as planning and simulation of dental implant treatment, endodontics, periodontics, and oral surgical procedures.<sup>10-13</sup> However, further investigations will be necessary to validate the clinical usefulness of the technology.

Though CBCT involves relatively small doses of radiation compared to conventional CT, the technology cause relatively high radiation exposure to the salivary gland and skin, which together with the relatively high cost of CBCT,<sup>15,16</sup> In light of these lines CT is not always indicated, and it is therefore necessary to establish criteria for when to choose CBCT as the imaging modality.<sup>15,16</sup> The comparison between cone-beam CT and medical CT is another important concern.

Hashimoto *et al.*<sup>26</sup> reported that cone-beam CT was significantly superior to conventional multidetector CT in visualizing teeth and their surrounding structures. Holberg *et al.*<sup>27</sup> reported the opposite results in their clinical study (74.46 % in CBCt, 42.55 % for OPG in this study). Although direct comparison of these 2 modalities

could determine which is superior in predicting neurovascular bundle exposure at extraction, such a clinical study might not be performed because patients would receive a significant radiation exposure.

## CONCLUSION

This study confirmed the clinical usefulness of cone-beam CT for our preoperative evaluation and our planning of the way of surgical procedure of impacted mandibular third molars with close relationship to the mandibular canal. It also showed that CBCT is more accurate in demonstrating presence or absence of cortical bone separating the nerve and the root. CBCT should be performed when roots of mandibular wisdomteeth are superimposed onto or below the upper cortical lamella of the mandibular canal.

## ACKNOWLEDGEMENT

*Dr. Donald Ferguson is thanked for his help with statistical evaluation of data.*

## REFERENCES

1. Smith AC, Barry SE, Chiong AY, Hadzakis D, Kha SL, Mok SC, *et al.* Inferior alveolar nerve damage following removal of mandibular third molar teeth. A prospective study using panoramic radiography. *Aust Dent J.* 1997;42:149-52.
2. Valmaseda-Castellón E, Berini-Aytés L, Gay-Escoda C. Inferior alveolar nerve damage after lower third molar surgical extraction: a prospective study of 1117 surgical extractions. *Oral Surg Oral Med Oral Pathol Oral Radiol Endod.* 2001;92:377-83.
3. Kipp DP, Goldstein BH, Weiss WW Jr. Dysesthesia after mandibular third molar surgery: a retrospective study and analysis of 1,377 surgical procedures. *J Am Dent Assoc.* 1980;100:185-92.
4. Monaco G, Montevicchi M, Bonetti GA, Gatto MRA, Checchi L. Reliability of panoramic radiography in evaluating the topographic relationship between the mandibular canal and impacted third molars. *J Am Dent Assoc.* 2004;135:312-8.
5. Sedaghatfar M, August MA, Dodson TB. Panoramic radiographic findings as predictors of inferior alveolar nerve exposure following third molar extraction. *J Oral Maxillofac Surg.* 2005;63:3-7.
6. Maegawa H, Sano K, Kitagawa Y, Ogasawara T, Miyauchi K, Sekine J, *et al.* Preoperative assessment of the relationship between the mandibular third molar and the mandibular canal by axial computed tomography with coronal and sagittal reconstruction. *Oral Surg Oral Med Oral Pathol Oral Radiol Endod.* 2003;96:639-46.
7. Mahasantipiya PM, Savage NW, Monsour PAJ, Wilson RJ. Narrowing of the inferior dental canal in relation to the lower third molars. *Dentomaxillofac Radiol.* 2005;34:154-63.
8. Öhman A, Kivijärvi K, Blombäck U, Flygare L. Preoperative radiographic evaluation of lower third molars with computed tomography. *Dentomaxillofac Radiol.* 2006;35:30-5.
9. Drage NA, Renton T. Inferior alveolar nerve injury related to mandibular third molar surgery: an unusual case presentation. *Oral Surg Oral Med Oral Pathol Oral Radiol Endod.* 2002;93:358-61.
10. Terakado M, Hashimoto K, Arai Y, Honda M, Sekiwa T, Sato H. Diagnostic imaging with newly developed ortho cubic superhigh resolution computed tomography (ortho-CT). *Oral Surg Oral Med Oral Pathol Oral Radiol Endod.* 2000;89:509-18.
11. Nakagawa Y, Kobayashi K, Ishii H, Mishima A, Ishii H, Asada K, *et al.* Preoperative application of limited cone beam computerized tomography as an assessment tool before minor oral msurgery. *Int J Oral Maxillofac Surg.* 2002;31:322-6.
12. Danforth RA, Peck J, Hall P. Cone beam volume tomography: an imaging option for diagnosis of complex mandibular third molar anatomical relationships. *J Calif Dent Assoc.* 2003;31:847-52.

13. Hamada Y, Kondoh T, Noguchi K, Iino M, Isono H, Ishii H, *et al.* Application of limited cone beam computed tomography to clinical assessment of alveolar bone grafting: a preliminary report. *Cleft Palate Craniofac J.* 2005;42:128-37.
14. Lofthag-Hansen S, Huuonen S, Gröndahl K, Gröndahl HG. Limited cone-beam CT and intraoral radiography for the diagnosis of periapical pathology. *Oral Surg Oral Med Oral Pathol Oral Radiol Endod.* In press 2006.
15. Freisfeld M, Drescher D, Kobe D, Schuller H. Assessment of the space for the lower wisdom teeth. Panoramic radiography in comparison with computed tomography. *J Orofac Orthop.* 1998;59:17-28.
16. Aryatawong S, Aryatawong K. Evaluation of the inferior alveolar canal by cross-sectional hypocycloidal tomography. *Implant Dent* 2000;9:339-45.
17. Rood JP, Shehab BA. The radiological prediction of inferior alveolar nerve injury during third molar surgery. *Br J Oral Maxillofac Surg.* 1990;28:20-5.
18. Bell GW, Rodgers JM, Grime RJ, Edwards KL, Hahn MR, Dorman ML, *et al.* The accuracy of dental panoramic tomographs in determining the root morphology of mandibular third molar teeth before surgery. *Oral Surg Oral Med Oral Pathol Oral Radiol Endod.* 2003;95:119-25.
19. Rud J. Third molar surgery: perforation of the inferior dental nerve through the root. *Tandlaegebladet.* 1983;87:659-67.
20. Honda K, Arai Y, Kashima M, Takano Y, Sawada K, Ejima K, *et al.* Evaluation of the usefulness of the limited cone-beam CT (3DX) in the assessment of the thickness of the roof of the glenoid fossa of the temporomandibular joint. *Dentomaxillofac Radiol.* 2004;33:391-5.
21. Alling CC III. Dysesthesia of the lingual and inferior alveolar nerves following third molar surgery. *J Oral Maxillofac Surg.* 1986;44:454-7.
22. Hilgers ML, Scarfe WC, Scheetz JP, Farman AG. Accuracy of linear temporomandibular joint measurements with cone beam computed tomography and digital cephalometric radiography. *Am J Orthod Dentofacial Orthop.* 2005;128:803-11.
23. Wofford DT, Miller RI. Prospective study of dysesthesia following odontectomy of impacted mandibular third molars. *J Oral Maxillofac Surg.* 1987;45:15-9.
24. Guelicher D, Gerlach KL. Incidence, risks, and course of sensibility disturbances after third molar surgery. Study in 1106 patients. *Mund Kiefer Gesichtschir.* 2000;4:99-104.
25. Sisk AL, Hammer WB, Shelton DW, Joy ED Jr. Complications following removal of impacted third molars: the role of the experience of the surgeon. *J Oral Maxillofac Surg.* 1986;44:855-9.
26. Hashimoto K, Arai Y, Iwai K, Araki M, Kawashima S, Terakado M. A comparison of a new limited cone beam computed tomography machine for dental use with a multidetector row helical CT machine. *Oral Surg Oral Med Oral Pathol Oral Radiol Endod.* 2003;95:371-7.
27. Holberg C, Steinhäuser S, Geis P, Rudzki-Janson I. Cone-beam computed tomography in orthodontics: benefits and limitations. *J Orofac Orthop.* 2005;6:434-44.
28. Arai Y, Honda K, Iwai K, Shinoda K. Practical model '3DX' of limited cone-beam X-ray CT for dental use. *International Congress Series.* 2001;1230: 713-8.
29. Ludlow JB, Davies-Ludlow LE, Brooks SL. Dosimetry of two extraoral direct imaging devices: NewTom cone beam CT and Orthophos Plus DS panoramic unit. *Dentomaxillofacial Radiology.* 2003;32: 229-34.
30. Ludlow JB, Davies-Ludlow LE, Brooks SL, Howerton WB. Dosimetry of 3 CBCT devices for oral and maxillofacial radiology: CB Mercuray, NewTom 3 G and i-CAT. *Dentomaxillofacial Radiology.* 2006;35:219-26.
31. Ngan DCS, Kharbanda OP, Geenty JP, Darendeliler MA. Comparison of radiation levels from computed tomography and conventional dental radiographs. *Australian Dental Journal.* 2003;19:67-75.
32. Bottollier-Depois JF, Chau Q, Bouisset P, Kerlau G, Plawinski L, Lebaron-Jacobs L. Assessing exposure to cosmic radiation on board aircraft. *Advanced Space Research.* 2003;32:59-66.