

DIAGNOSTIC CAST – A FORGOTTEN DIAGNOSTIC TOOL

¹SUMA KARTHIGEYAN, MDS

²SEYED ASHARAF ALI, MDS

³MANGALA DEIVANAI, BDS

⁴NIMMI, BDS

ABSTRACT

Dentists are challenged to create solutions for problems that patients present from chipped or missing teeth, a collapsed bite, or teeth that are irregular or misshapen. A clear diagnosis of the condition often is required for a proper treatment planning. The diagnostic cast helps the dentist to evaluate the condition of the patient's oral condition and for the diagnostic purposes. Casts may also be used as education tools for dentists as they explain characteristics of a patient's bite or particular dental needs. They can also show how a restoration will look when the work is complete.

Diagnostic cast is a life-size reproduction of a part or parts of the oral cavity and/or facial structures for the purpose of study and treatment planning (GPT). Accurate diagnostic casts transferred to a semiadjustable articulator are essential for treatment planning in Prosthodontics, Orthodontics and for Orthognathic surgeries.

Significance of mounted diagnostic casts¹

- 1 This permits examination of teeth without interference from cheek, tongue and influence of neuromusculature.
- 2 Articulated diagnostic casts permit a detailed analysis of the occlusal plane and the occlusion, and the diagnostic procedures can be performed for a better diagnosis and treatment planning (Fig 1).
- 3 Curvature of the arch in the edentulous region can be determined so that it will be possible to predict whether the pontic/pontics will act as a lever arm on the abutment teeth.
- 4 Length, inclination, drifting or rotation of the abutment teeth can be accurately gauged to determine preparation designs.
- 5 Occlusal discrepancies can be evaluated and the presence of centric prematurities or excursive interferences can be determined.
- 6 Sometimes patient has to undergo extensive enameloplasty, to meet the treatment goal. In such situations, the patient is informed in advance that additional time will be needed and expense will be greater to avoid doubt or disappointment in treatment.

- 7 Diagnostic waxing can be rehearsed on the casts, and diagnostic waxing procedures allow evaluation of the eventual outcome of the proposed treatment.

IMPRESSIONS FOR DIAGNOSTIC CASTS

Accurate impressions are mandatory for diagnostic casts. Irreversible hydrocolloids are the commonly used impression material but an elastomeric impression may be required when accuracy is critical as in cases of diagnosing occlusal problems or when multiple preoperative casts are required. For making irreversible hydrocolloid impressions, largest tray that fits comfortably in patients mouth should be selected (Fig 2). A greater bulk of impression produces a more accurate impression because bulky impressions have a more favorable surface area / volume ratio and is less susceptible to water loss and dimensional change.²

Impression making

For optimum results the teeth should be cleaned and the mouth thoroughly rinsed. Some drying is necessary, but excessively dried tooth surfaces will cause the adherence of the material. The material is mixed to a homogeneous consistency, loaded into the tray, and its surfaces smoothed using moistened, gloved finger. A small amount of material is wiped into the crevices of the occlusal surfaces and mucobuccal fold before the tray is seated. The tray should be removed quickly 2 to 3 minutes after gelation. Following removal, the impression should be rinsed and disinfected, spraying with a suitable glutaraldehyde. To ensure accuracy, pouring should be completed within 15 minutes of the time the impression is removed from the mouth.

Making a cast without voids and surface irregularities is of paramount importance. A vacuum-mixed ADA Type III or Type IV stone is recommended. After mixing, a small amount of stone is added in one location (e.g., the posterior aspect of one of the molars). Applying small amounts consistently in the same location will minimize bubble formation. While setting, the poured impressions must be stored tray side down. Inverting

¹ Professor & HOD

² Professor

³ Lecturer

⁴ Postgraduate Student Division of Prosthodontics, Rajah Muthiah Dental College & Hospital, Annamalai University, Chidambaram

Received for Publication: January 30, 2014

Revision Accepted: February 17, 2014

Revision Accepted: February 20, 2014

freshly poured impressions results in a cast with a rough and grainy surface. The setting gypsum cast should never be immersed in water to prevent hygroscopic expansion.

Common Errors in impression

Error in the impressions results in inaccuracy in the cast. Common errors are³:

- 1) Voids in the impression.
- 2) Movement during setting of material.
- 3) Impression material dislodged from impression tray.
- 4) Laying alginate on table top with long extension (Fig 3).
- 5) Cast poured impromptly on time.

SELECTION OF ARTICULATORS

A semiadjustable articulator is essential to provide the necessary diagnostic information and it will minimize the need for clinical adjustments during treatment. They are about the same size as the anatomic structures they represent. Therefore, the articulated casts can be positioned with sufficient accuracy so that arcing errors will be minimal.

The selection of articulator must be based on four factors⁴

- 1) Characteristics of the patient's occlusion

Two factors determine mandibular movements are the anterior tooth guidance and the posterior condylar guidance. When a patient has adequate and immediate anterior guidance the function of an articulator is to provide the influence of the posterior determinants. A less complicated articulator system can be successfully used for this patient. When a patient manifest poor anterior guidance resulting from missing or malaligned anterior teeth, the predominant factors of mandibular movement are the posterior determinants. In this case a more complicated articulator system is indicated.

- 2) Extent of the restorative procedures planned

One of the primary reasons for using an articulator is to minimize the need for intraoral adjustment of the restorations being planned. Generally a more extensive treatment plan requires a more sophisticated articulator system. When minor procedures are indicated, it is easier to compensate by using simpler instruments.

- 3) Understanding of the limitation of the articulator system

The dentist must be aware that before a restoration can be permanently placed in a patient's mouth it must meet all the criteria of the optimal functional occlusion. Some of the simple articulators provide only a small part of the information necessary to reach this goal.

Indications of each articulator system⁵

- a. Because the nonadjustable articulator is simplest, the dentist may be directed toward it. For a patient

with adequate and immediate anterior guidance, this type may be successfully used for the fabrication of single crown.

- b. Semiadjustable articulator is capable of closely reproducing mandibular movement and therefore reducing intraoral adjustments. It is helpful in fabricating crown for patient with minimal anterior guidance.
- c. Fully adjustable articulator is indicated for complex full mouth constructions and when alteration in vertical dimension of occlusion is being considered.
- 4) Skill of the clinician

It is important that an articulator is only as accurate as the clinician who uses it. When care is not exercised in acquiring information from the patient for adjusting the articulator or when casts are inaccurately mounted, the usefulness of any articulator is greatly diminished.

FACEBOW TRANSFER

Facebows are used to record the anteroposterior and mediolateral spatial position of the maxillary occlusal surfaces relative to the transverse opening and closing axis of the patient's mandible. The facebow is then attached to the semi adjustable articulator to transfer the recorded relationship of the maxilla by ensuring that the corresponding cast is attached in the proper position relative to the hinge axis of the instrument.

Two types of facebows are arbitrary and kinematic. Arbitrary facebows are less accurate than the kinematic type, but they are sufficient for most routine dental procedures. Kinematic facebows are indicated when it is important to precisely reproduce the exact opening and closing movement of the patient on the articulator and for patients who necessitate alteration of the vertical dimension of occlusion.⁶

Transverse Horizontal Axis

The mandibular hinging movement around the transverse horizontal axis is repeatable. That makes this imaginary "hinge axis" around which the mandible may rotate in the sagittal plane of considerable importance in treatment planning.

Third point of reference

It is the anterior reference point used for orienting casts in the three dimensional space in an articulator. And it also helps to duplicate the recorded position on the articulator in further appointment in the same plane. Commonly used anterior reference points are nasion and orbitale.⁷

Steps in facebow transfer:

- 1) Add modeling compound to the facebow fork.
- 2) Temper in water and seat the fork, make indentations of the maxillary cusp tips by using cast. The facebow fork is positioned in the patient's mouth, and an impression of the maxillary cusp tips made. The impression must be deep enough to permit

accurate repositioning of the maxillary cast after the facebow fork has been removed from the mouth.

- 3) Remove the fork from the mouth. Chill and reseat the fork, and check that no distortion has occurred. The inclusion of details of pits and fissures in the recording medium will lead to inaccuracies when trying to seat the stone cast. Trim the excess recording medium before reseating. After reseating, check for stability.
- 4) Have the patient stabilize the facebow fork by biting on cotton rolls. Attach U shaped frame to the facebow fork. Adjust the height and anteroposterior distance using anterior reference mark. Midline of face bow should coincide with that of patient. Tighten the locking devices (Fig 4).
- 5) Remove the facebow from the mouth. And transfer the record to the articulator. Mount the upper cast using this record.

Errors in Facebow Transfer

1. Deep indentation into bite material
2. Raising or lowering the face-bow mounting
3. Unstable bitefork.
4. Not having the fork come out the right side of the mouth.
5. Eccentric position of the vertical rod.

CENTRIC RELATION

The maxillomandibular relationship in which the condyle articulates with the thinnest a vascular portion of their respective disc with the complex in the anterior superior position against the slopes of the articulate eminence. This position is independent of tooth contact.

- It is a reproducible arch to arch relationship and hence considered an optimum recordable position of jaws for dentate patients for the comfort and function of temporomandibular joints.
- Casts articulated in the maximum intercuspation (MI) position do not permit the evaluation of CR and retruded contact relationships. Therefore, the articulation of diagnostic casts in CR is of greater diagnostic value.
- Centric relation is related to the terminal hinge axis. In this position the mandible moves in a hinge motion to a distance 15-25 mm at the incisal in the sagittal plane. This means that if interocclusal records were taken at any vertical height within the true hinge movement, transferring of casts to an articulator will not incorporate closing errors on the articulator.
- It is a reproducible position which can be repeatedly arrived at and thus serves as a reliable guide to develop centric occlusion in artificial denture.
- It serves as a reference position for the institution of occlusal rehabilitation in dentate conditions.

But not necessarily the position where the centric occlusion is placed.

- The terminal act of masticatory stroke terminates in centric relation. It is also the most terminal position where upper and lower teeth could be braced against each other during deglutition.

DEPROGRAMMING DEVICES

For some patients the centric relation does not coincide with the maximum intercuspation position. Use of an anterior deprogramming device allows separation of the posterior teeth immediately prior to centric record fabrication. This results in loss of muscle memory and allows the patient to close in an operator defined repeatable position. Various deprogramming materials and devices are Cotton rolls, Impression compounds adapted to the maxillary incisors, Tongue blade, Lucia Jig, Pankey Jig.

RECORDING CENTRIC RELATION

1. Chin point guidance

The patients mandible is guided in an arcing motion to the terminal hinge position. During this manipulation, posteriorly directed force is placed gently against the chin. The mandible is then manipulated into a passive interocclusal registration medium.

2. Tongue to palate

The patient is requested to touch the tongues to the posterior border of the hard palate. The patient is then requested to hold the tongue in place while carefully elevating the mandible until the interocclusal recording medium is engaged.

3. Dawson bimanual manipulation

According to Dawson, bilateral manipulation is the most repeatable and achieves the most superior position of the condyles.⁸ By this method it is possible to verify

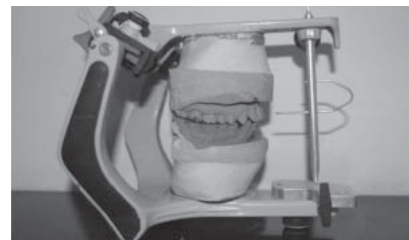

Fig 1: mounted diagnostic cast




Fig 2: Rim lock tray follows anatomic contour of mouth than conventional tray.

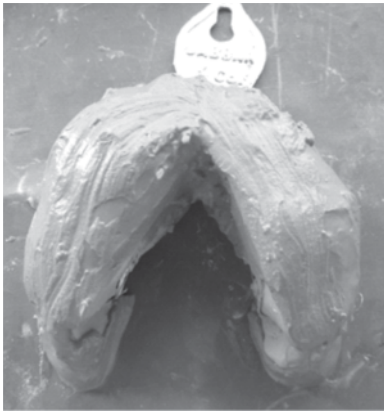

Fig 3: impression with long extension

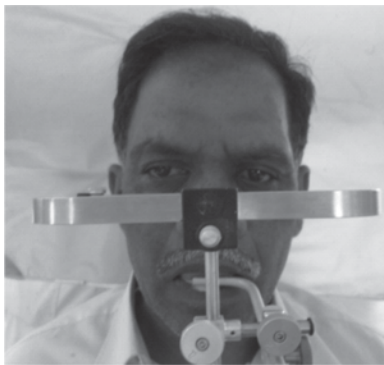


Fig 4: Face bow transfer




Fig 5: interocclusal record

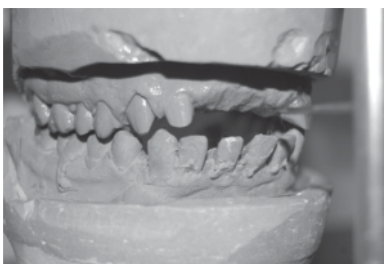

Fig 6: Diagnostic tooth preparation

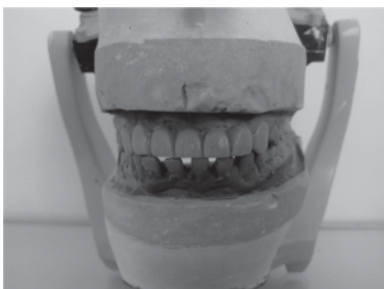

Fig 7: Diagnostic Wax Up

the correctness of the condyle position, alignment of the condyle disk assembly, integrity of the articular surfaces.

Method for Bimanual manipulation

1. Recline the patient all the way back, point the chin up. When the patient is supine it is comfortable for the operator to work in a seated position and it is easy for the patient to relax.
2. With the head firmly stabilized, position the four fingers of each hand on the lower border of the mandible. The little fingers should be on the angle of the mandible or even slightly behind it. Thumbs should be on the notch above the symphysis. It forms a C with each hand. No pressure is applied at this time.
3. Now jaw is manipulated so that it slowly hinges open and closed. As it hinges the mandible will usually slip up into centric relation automatically if no pressure is applied. Any pressure applied before the condyles are completely seated will be resisted by the lateral pterygoid muscles. An arc of 1 to 2mm is acceptable. When arcing do not let teeth touch.
4. Once the jaw starts hinging freely and the condyles seem to be fully seated up in their fossae, the centric relation position must be verified. Both the position of the each condyle and its proper alignment with the disk must be tested by application of a very firm pressure upward.
5. Each closing arc should be progressively closer to the tooth contact. When initial tooth to tooth contact is made, the first interference to centric relation has been located. With the mandible held on its terminal axis, the interfering teeth are tapped together two or three times so that the patient can feel the prematurity.

Verification of centric relation

Load testing is done to verify that the condyles are completely seated after the operator has gently manipulated the mandible to a freely hinging position that is suspected of being in centric relation. If the Condyle -Disk assemblies are completely seated there is no discomfort in the TMJ and in the masticatory musculature from loading. Proper load testing must be done in increments. First increment of load must be given with gentle compression. If pain is present, it is may be due to intracapsular disorder or muscle spasm. Second increment is moderate loading. Pain at this level is mostly due to muscle bracing. Third increment should be firm loading.

Requirements of centric record

1. The bite record must not cause any movement of teeth or displacement of soft tissue.

2. It must be possible to check the accuracy of the bite record in the mouth.
3. The bite record must fit the models as accurately as it fits the mouth.
4. It must be possible to check the accuracy of the bite record on the models
5. The bite record should not distort during storage or transportation to the laboratory.

Examples of interocclusal bite registration medium: plaster, waxes, ZOE paste, silicon elastomers, acrylic resin, stabilized bite rim.

CENTRIC RELATION RECORD

The use of wax bite for making interocclusal records is by far the most popular method. The main reason is due to its simplicity

The following procedures are basic for making a direct wax interocclusal record (wax bite)

1. The surfaces of a sheet of extra hard base plate wax are heated over a bunsen burner. While wax is warm it is pressed very lightly against the upper arch either in the mouth or against a model. The indentations are noted, and with warm knife, the wafer is trimmed to just fit the arch. The bite is cooled slightly with air and removed. It is checked to make sure there are no penetrations (Fig 5).
2. The wax record is returned to the upper arch and the mandible is guided into it, making sure there is no deviation during closure. The mouth is closed firmly against the wax, which is slightly warm, and perfect adaptation of the wax to the teeth is checked.
3. The wax wafer should extend directly across the arch without touching palatal tissue. The wax is chilled in ice water. Now the record is placed in against the upper teeth and the mandible manipulated to check for occlusal interferences. All the teeth should be checked that they touch the bite record at the same time. With the centric record, mount the mandibular cast to the articulator.

Errors in centric relation record

1. Improper manipulation of mandible
2. No guidance or verification of centric
3. Flimsy bite recording materials
4. Too deep indentations in the bite material.
5. Use of soft waxes that are easily distorted when casts are seated into the record.
6. Too shallow or nonexistent indentations.
7. Unstable bite recording materials that warp or distort after the recording is made.

ECCENTRIC REGISTRATIONS

The purpose of eccentric interocclusal registrations or check bites is to assist the dentist in setting the articulator fossa elements on a semiadjustable articulator. There are two types of eccentric registrations lateral-excursive records (lateral check bites) and protrusive records.

Lateral check bites

Lateral check bites are used to set the condylar elements of an arcon semiadjustable articulator.

Technique

Before the lateral interocclusal registration is fabricated the patient's casts are mounted on an arcon articulator using the appropriate facebow and centric relation record.

1. Arbitrarily set the superior walls of the fossae to the angle of 300 and medial walls to 150. If an articulator having fixed progressive side shift is used, set the immediate side shift to 1mm.
2. Manipulate the mandibular member of the articulator into left lateral excursion so that the left mandibular canine is edge to edge with left maxillary canine. Open the incisal pin to create 2mm space between the incisal edges. Make a pencil mark at the point on the incisal table.
3. Soften the wafer and place it on the lower cast; Close the articulator until the incisal guide pin touches pencil mark on the surface of the incisal table. Chill the wax wafer to remove it from the cast without distortion.
4. While the patient is present, soften the wafer slightly in a water bath. Place the wafer against the upper teeth and have the patient move into left lateral excursion until the lower teeth locate the indentations in the wax made by the mandibular cast. Have the patient bite firmly into the wax. Reline the preregistered lateral check bite record with bite registration paste, then place it against the maxillary teeth and have the patient move into lateral position.
5. After the paste sets, trim the lateral check bite so only shallow cuspal imprints remain. Seat it on the mandibular cast and place the maxillary cast over it. Loosen the horizontal and medial condylar housing walls of the right condylar housing. Set them to allow the horizontal and medial walls to just contact the condyle. Tighten the walls and remove the record. Repeat this procedure using the right lateral excursive to set the left condylar housing.

Protrusive check bites

When a non arcon articulator is anticipated, a protrusive interocclusal record is indicated. Protrusive

excursive record fabrication is similar to the lateral interocclusal records, but only one is necessary. The horizontal condylar inclination of a non arcon articulator are arbitrarily set 30 degrees and same procedure has to be repeated with the tooth in edge to edge contact.

DIAGNOSTIC TOOTH PREPARATION

1. Mount the cast in centric relationship.
2. After mounting observe the occlusal contact relationship, rotation, supra eruption and drifting.
3. Check for the first tooth contact. Lock the centric latch when observing the contact.
4. Determine the vertical dimension of occlusion and mount it in maximum intercuspation. Keep the incisal guide pin on contact with incisal table. This will be the vertical dimension of the patient.
5. Reposition the cast in the centric relation. Perform selective grinding until get the stable contact in the same vertical dimension.
6. Analyze the occlusal plane. Plane can be established by occlusal plane analyzer. See for amount of tooth reduction necessary to achieve proper occlusal plane. If it is 2-3mm that tooth definitely protected with metal/metal ceramic crown. If tooth need extensive reduction, root canal treatment is recommended before tooth preparation (Fig 6).
7. Mutilated teeth or tooth that is to be gone for extraction can be mentioned on the cast with marker.

DIAGNOSTIC WAX UP

The diagnostic wax-up is the process of converting a programmed treatment plan into a three-dimensional visualization (Fig 7).

Uses of diagnostic wax-up

- Aids in deciding which teeth to prepare, how to prepare each tooth to allow adequate restoration and how to contour the final restoration.
- For establishing Stable holding contacts.
- Selecting the best treatment option.
- Increases the dentist confidence.
- Best visual aid to the patient.
- For explaining the treatment nature to the specialists.
- Fabrication of provisional restorations.
- For esthetic analyses.
- For making orthodontic and surgical decisions.

Procedure

1. Casts are waxed-up to the limits of recorded mandibular movement patterns, and aesthetics.
2. Establish the holding contacts with wax. Cusp cones of wax rise/hang to touch opposing contact surface.
3. Check mandibular motions to ensure contacts bypass each other.
4. Lobes joined by waxing on marginal ridges.
5. Triangular cross-tooth and oblique ridges connect the lobes.
6. Add peripheral contours.
7. Check the anterior guidance and condylar guidance for interferences. Complete the waxup.
8. Equilibration is the first treatment option to explore. The combination of the clinical exam and the diagnostic wax-up on mounted casts enabled the dentist to arrive at a decision.

CONCLUSION

Diagnostic casts are a valuable tool in evaluating tooth contacts at occlusion and function. Failure to utilize a diagnostic cast during prosthodontic treatment planning will result in an improper and inadequate treatment outcome.

REFERENCES

1. Larry G Loos. Procedure for occlusal refinement of mounted definitive casts to reduce clinical time required for adjustment of occlusion. *J Prosthet dent* 2001; 85: 246-51.
2. Rosensteil. Contemporary fixed Prosthodontics. Fourth Edition. Elsevier Publication: Saurabh printers Noida, India: 2007 pg 43-45.
3. John R Agar et al. Jaw relation records for fixed prosthodontics. *DCNA* 2004, 48: 2,471-487.
4. Jeffery P Okeson. Management of Temporomandibular Disorders and Occlusion. Second Edition. The C.V Mosby Company. USA. 1989. Pg 475-478.
5. A.J. Mc Cullock. Making occlusion work: 1. Terminology, occlusal assessment and recording. *Journal of Restorative dentistry* 2003; 30: 150-57.
6. Herbert T. Shillingburg, Fundamentals of fixed prosthodontics. Third Edition. Quintessence Publishing Co, Rakesh press India. 1997 Pg 29-30.
7. S.J. Daves. The examination and recording of the occlusion: why and how. *The dental journal* 201; 191: 291-302.
8. Peter E Dawson. Functional occlusion from TMJ to Smile Deign. Elsevier Publication: Canada. 2007 Pg 76-79.