

## FREQUENCY OF VITREO MACULAR TRACTION IN DIABETIC MACULAR EDEMA ON OPTICAL COHERENCE TOMOGRAPHY

Nauroz Fatima, Qamar UI Islam\*, Maeirah Shafique\*\*

Combined Military Hospital/National University of Medical Sciences (NUMS) Rawalpindi Pakistan, \*Pakistan Naval Ship Hospital Karachi Pakistan, \*\*Combined Military Hospital Khuzdar/National University of Medical Sciences (NUMS) Pakistan

### ABSTRACT

**Objective:** To determine the frequency of vitreo macular traction (VMT) in patients of diabetic macular edema (DME) as detected on spectral domain optical coherence tomography (SD-OCT).

**Study Design:** Cross-sectional study.

**Place and Duration of Study:** Armed Forces Institute of Ophthalmology (AFIO) Rawalpindi, from May 2013 to Jan 2014.

**Patients and Methods:** Diabetic patients of less than 18 years of age with DME and central macular thickness of more than 250 micrometers ( $\mu\text{m}$ ) were included. The patients with idiopathic VMT, history of vitreoretinal surgery, and history of other retinal vascular diseases were excluded from the study. Dilated fundus was done in each patient using 90 D lens on a slit lamp biomicroscope and patients with diabetic retinopathy changes and DME were subjected to OCT examination using Topcon 3-D OCT 1000 (Topcon Corporation). Record of each patient including demographic data, ocular findings and OCT data were endorsed on a pre-devised proforma.

**Results:** Seventy one eyes of 68 patients were included, 36 (50.7%) were males and 35 (49.29%) were females. Mean age was  $53.17 \pm 8.79$  years. Mean central macular thickness (CMT) was  $361.8 \pm 109 \mu\text{m}$ . VMT was detected in 17 (23.9%) eyes. Amongst these, 2(12.5%) eyes had vitreofoveal traction, epiretinal membrane was found in 4 (25%) eyes and 11(62.5%) eyes had extra foveal VMT.

**Conclusion:** Detection of VMT in about a quarter of cases reflects that OCT is a viable tool for early detection of vitreomacular interface abnormalities.

**Keywords:** Diabetic macular edema, Extrafoveal vitreous traction, Optical coherence tomography.

This is an Open Access article distributed under the terms of the Creative Commons Attribution License (<http://creativecommons.org/licenses/by/4.0>), which permits unrestricted use, distribution, and reproduction in any medium, provided the original work is properly cited.

### INTRODUCTION

The role of vitreo macular interface (VMI) abnormalities in diabetic retinopathy population is important as it can influence the progression of disease and response to treatment. As the vitreous gel liquefies there is weakening of adhesions at vitreoretinal interface causing the vitreous to collapse and it pulls away from the retina, this process is known as posterior vitreous detachment (PVD). Sometimes the vitreous liquefaction exceeds the vitreoretinal dehiscence leading to anomalous PVD. When vitreous is only partially detached at macula with normal anatomy it is called vitreomacular adhesion (VMA) and when it leads to anatomical retinal

changes on OCT it is called as vitreomacular traction (VMT)<sup>1</sup>. The incidence of PVD was found to be lower in patients with diabetic macular edema (DME) than in diabetics without macular edema suggesting that attached vitreous is a risk factor for DME and also adversely affects the clinical course of DME<sup>2</sup>.

High resolution SD OCT is a noninvasive and non-contact imaging technology that has revolutionized the understanding of VMI in patients with various retinal disorders including DME<sup>3</sup>. It utilizes the spectral analysis of interference fringe pattern and acquires approximately 20,000 A-scans per second with an axial resolution of 5-7  $\mu\text{m}$ <sup>4</sup>. It precisely differentiates various types of DME as well as the presence of macular traction. Several patterns of DME has been identified on the OCT which include cystoid type, spongy type, mixed type,

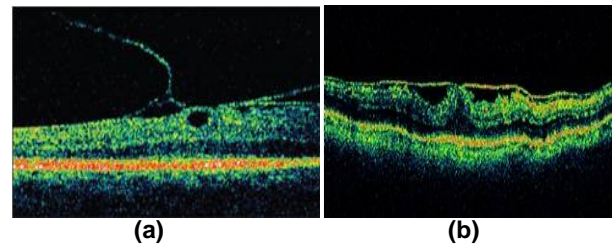
**Correspondence:** Dr Nauroz Fatima, Graded Eye Specialist Eye Dept CMH Rawalpindi Pakistan (Email:wittyfatima@hotmail.com)  
Received: 19 Feb 2016; revised received: 21 Apr 2016; accepted: 05 May 2016

foveal serous retinal detachment, associated with taut posterior hyaloid, with vitreo-macular traction etc<sup>5</sup>. Assessment of macular traction is of prime importance in determining the therapeutic approach, prognosis and effect of treatment. Pars plana vitrectomy (PPV) was found beneficial in eyes with persistent DME associated with VMT<sup>6</sup>. Early detection of VMT in DME patients using SD OCT is important to reduce the morbidity related to DME. Available local data on the subject is scarce. The rationale of this study was to determine the frequency of VMT in patients with DME on OCT.

### MATERIAL AND METHODS

It was a cross-sectional study carried out at outpatient department of Armed Forces Institute of Ophthalmology Rawalpindi. Non probability consecutive sampling was done from May 2013 to January 2014. Sample size of 71 cases was calculated by using WHO sample size calculator, keeping confidence level 95%, absolute precision required 10% and anticipated population proportion 24%<sup>7</sup>. Diabetic patients of >18 years of age with DME and central macular thickness (CMT) of >250  $\mu\text{m}$  were included. The patients with idiopathic VMT, history of vitreoretinal surgery, eyes with vitreomacular adherence without signs of traction and eyes with history of other retinal vascular diseases like retinal vein occlusion were excluded from study. After taking history and visual acuity Tropicamide 1% eye drop was instilled one in each eye. For poorly dilating pupils 2.5% Phenylephrine eye drop was also instilled. Fundus was examined using 90 D lens on a slit lamp bio microscope. The patients with diabetic retinopathy changes and DME were subjected to OCT examination. SD OCT examination was carried out by using Topcon 3-D OCT 1000 (Topcon Corporation). Macular scan was selected and the image was captured using standard 6 $\times$ 6 mm protocol, in which the 3-D acquisition consisted of 64 B-scan slices. Axial resolution was 6  $\mu\text{m}$  while transverse resolution was 20  $\mu\text{m}$ . A fundus photograph was also obtained at the same time. The image quality index was provided on the screen by the OCT

software. Confidentiality of the patient record was maintained. All the findings were endorsed on a pre devised proforma. Evidence of traction was shown as vitreous adherence to the retina associated with tissue elevation and deformity at the traction site. The shape of the inner retina at the site of traction was changed and thus was typically thicker than that of the adjoining edematous retinal tissue. OCT results were related into three groups (1) Vitreo foveal traction: at the center of macula (fig-1a) (2) Extra



**Figure-1: Vitreo macular interface abnormalities in diabetic macular edema (a) Vitreo foveal traction (b) ERM.**

foveal traction: vitreoretinal traction elsewhere at the posterior pole in between vascular arcades (3) Epi retinal membrane: diagnosed as difference in the brightness of surface tissues (fig-1b).

Data were analyzed using SPSS version 14. Descriptive statistics were used to calculate mean and standard deviation of age, number of diabetic years and CMT. Percentage was calculated for the presence or absence of VMT and gender.

### RESULTS

Seventy one eyes of 68 patients who were fulfilling the inclusion criteria were included in final analysis. Out of them 36 (50.7%) were male and 35 (49.29%) were female. Right eye was involved in 31 (45.5%) patients, left eye was involved in 34 (50%) patients and bilateral involvement was present in 3 (4.5%) patients. Mean age of study population was  $53.17 \pm 8.79$  years (range: 35-70 years) with majority of patients were in their 6th decade of life. Mean duration of diabetes mellitus was  $8.5 \pm 3.5$  years (range: 2-19 years). Mean CMT was  $361.8 \pm 109 \mu\text{m}$ . Minimum CMT was 254  $\mu\text{m}$  and

maximum CMT was 652  $\mu$ m. All the patients had CMT > 250  $\mu$ m.

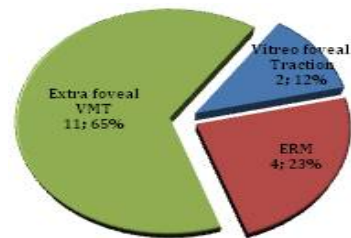
VMT was detected on OCT examination in 17 (23.9%) eyes. Out of these 17 cases vitreous foveal traction was found in 2 (12%) cases, epi retinal membrane was found in 4 (23%) cases and 11 (65%) cases had extra foveal vitreous macular traction bands (fig-2). Mean CMT in cases with VMT was 386  $\pm$  92  $\mu$ m while mean CMT in cases with no VMT was 355  $\pm$  114  $\mu$ m.

## DISCUSSION

Conventional methods of accessing DME include contact and non-contact slit lamp biomicroscopy, indirect ophthalmoscopy, fluorescein angiography and fundus stereo photography. However, with the advent of OCT, the diagnosis and management of DME has been revolutionized. The relationship between vitreous/posterior hyaloid and macular surface in diabetic retinopathy is very complex. OCT identifies VMI abnormalities including epi retinal membrane and/or VMT with precision. Ghazi et al evaluated OCT characteristics of 48 eyes with persistent clinically significant DME after focal laser treatment and found definite VMI abnormalities in 52.1% of eyes and OCT was found to be 1.94 times more sensitive than traditional techniques in detecting VMI abnormalities<sup>7</sup>. In a retrospective study, OCT scans of diabetic patients with macular edema were reviewed and 24% of the cases were associated with vitreofoveal or extra foveal vitreous traction, out of which, 56% had vitreofoveal traction and 44% had extrafoveal traction<sup>8</sup>. Gandorfer et al looked at the vitreoretinal relationship in diabetic patients with and without DME using OCT and reported that 53% of patients with macular edema had peri foveal PVD, while only 11% of patients without DME had peri foveal PVD<sup>9</sup>. In DME VMT is a contributing factor which not only aggravates the primary pathology but also worsens the prognosis and has an adverse effect on the vision. In our study, 23.9% of eyes had VMT. Ophir et al, while studying the outcomes of grid laser

photocoagulation on diffuse DME detected that in 16.7% of the eyes with treatment failure in terms of increase CMT above baseline level, after initial improvement, was due to presence of extra foveal VMT<sup>10</sup>. Khan et al evaluated SD OCT evident ERM and/or partial vitreous macular separation (pVMS) in patients undergoing macular laser photocoagulation for center involving DME and found out that ERM or pVMS was present in 25% of eyes<sup>11</sup>.

According to Diabetic retinopathy clinical research network, there was reduction in CMT in 93% of eyes which underwent vitrectomy for DME associated with VMT<sup>12</sup>. Diaz-Llopis et al studied that there was reduction in CMT in 100% of cases who underwent enzymatic vitreolysis for DME associated with evident posterior hyaloid adherence to the retinal surface<sup>13</sup>. It was found by La Heij et al in one of their studies that the visual acuity improvement after vitrectomy for DME was significantly better in the eyes which did not



**Figure-2: Type of vitreous macular interface abnormalities.**

have laser photocoagulation previously. The author suggested that delay in the vitrectomy and harmful effects of the laser are the causes for poor visual outcomes<sup>14</sup>. Hence the detection of VMT is important in deciding the mode of treatment.

The current study revealed that a considerable number of cases of DME were associated with VMT with extra foveal VMT (62.5%), ERM (25%) and foveal VMT (12.5%) were the common abnormalities. In this study apart from 2-D B-mode imaging, 3-D images were also analyzed. In a retrospective study association between diffuse DME and extrafoveal

vitreous traction was observed in 186 eyes of 121 patients and VMT was found in 45 (24%) eyes. Out of those vitreofoveal traction was detected in 25 (56%) eyes and extrafoveal traction in 20 (44%) eyes<sup>7</sup>. In that study centrally fixated Automatic 6-radial line program and line group OCT-2000 program was used. The results of our study were comparable with that study. However, in our study, extrafoveal VMT was detected in relatively more number of eyes with DME. This could be because of utilization of 3-D imaging modality in our study. In 3-D image whole vitreoretinal field is imaged so the interface can be observed more clearly. Jackson et al in a meta-analysis of vitreous attachment in DME found the cumulative prevalence of VMT or taut hyaloid being 18%, with 28.7% of eyes undergoing pars plana vitrectomy had VMT as compared to 12% of non-surgical cases<sup>2</sup>. In another study sole extrafoveal vitreous traction was found in 34.5% of the patients by using 3-D SD OCT, with extrafoveal sites included both retinal as well as the papillary traction<sup>15</sup>. Vitreopapillary traction was not included in our results. In our study, two (18%) of the 11 eyes with extrafoveal VMT, no association was found between the underlying retinal thickening and the central macular edema. This finding should be kept in mind while planning for an intravitreal therapeutic agent. It was reported by Arevalo et al that the intra vitreal Bevacizumab injection in eyes with proliferative diabetic retinopathy may lead to tractional retinal detachment or its progression<sup>16</sup>.

The results of this study provide more insight into the VMI abnormalities in our population, hence providing a rationale for deciding between intra vitreal anti VEGF agents or surgical treatment in patients with DME associated with VMI abnormalities. The limitations of this study were relatively smaller sample size that was not necessarily representing the whole population. Further case control studies are required in our set up to provide more detailed understanding of this intriguing

aspect of DME.

## CONCLUSION

Detection of VMT in about a quarter of cases reflects that OCT is a viable tool for early detection of vitreomacular interface abnormalities.

## CONFLICT OF INTEREST

This study has no conflict of interest to declare by any author.

## REFERENCES

- Duker JS, Kaiser PK, Binder S, de Smet MD, Gaudric A, Reichel E et al. The international vitreous macular traction study group classification of vitreous macular adhesion, traction, and macular hole. *Ophthalmology* 2013; 120 (12):2611-9.
- Jackson TL, Nicod E, Angelis A, Grimaldi F, Prevost AT, Simpson AR et al. Vitreous attachment in age-related macular degeneration, diabetic macular edema, and retinal vein occlusion: a systematic review and meta-analysis. *Retina* 2013; 33(6):1099-108.
- Agarwal D, Gelman R, Ponce CP, Stevenson W, Cristoforidis JB. The vitreous macular interface in diabetic retinopathy. *Journal of Ophthalmology* 2015; Article ID 392983, 10 pages 392983.
- Sull AC, Vuong LN, Price LL, Sirinivasan VJ, Gorczynska I, Fujimoto JG et al. Comparison of spectral / fourier domain optical coherence tomography instruments for assessment of normal macular thickness. *Retina* 2011; 30 (2): 235.
- Pai SA, Hussain N, Hebri SP, Lootah AM, Dekhain MA. Volcano like pattern in optical coherence tomography in chronic diabetic macular edema. *Saudi journal of ophthalmology* 2014; 28 :157-9.
- Song SJ, Sohn JH, Park KH. Evaluation of the efficacy of vitrectomy for persistent diabetic macular edema and associated factors predicting outcome. *Korean J Ophthalmol* 2007; 21 (3):146-150.
- Ophir A, Trevino A, Fatum S. Extra foveal vitreous traction associated with diabetic diffuse macular edema. *Eye* 2010; 24 (2):347-53.
- Ghazi NG, Cirasky JB, Shah SM, Campochiaro PA, Haller JA. Optical coherence tomography findings in persistent diabetic macular edema: the vitreous macular interface. *Am J Ophthalmol.* 2007; 144 (5): 747-54.
- Gandorfer A, Haritoglou C, Kampik A. Optical coherence tomography assessment of the vitreoretinal relationship in diabetic macular edema. *Am J Ophthalmol* 2006; 141(1): 234-5.
- Ophir A, Hanna R, Martinez MR. Importance of 3-D image reconstruction of spectral-domain OCT on outcome of grid laser photocoagulation for diffuse diabetic macular edema. *Int J Ophthalmol.* 2013; 6(6): 836-43.
- Khan A, Mohamed MD, Mann SS, Hysi PG, Laidlaw DA. Prevalence of vitreous macular interface abnormalities on spectral domain optical coherence tomography of patients undergoing macular photocoagulation for centre involving diabetic macular edema. *Br J Ophthalmol* 2015; 99 (8):1078-81.
- Diabetic retinopathy clinical research network. Vitrectomy outcomes in eyes with diabetic macular edema and vitreous macular traction. *Ophthalmology* 2010; 117(6): 1087-1093.
- Diaz-Llopis M, Udaondo P, Millán JM, Arevalo JF. Enzymatic vitrectomy for diabetic retinopathy and diabetic macular edema. *World J Diabetes* 2013; 4(6): 319-23.
- La Heij EC, Hendrikse F, Kessels AG, Derhaag PJ. Vitrectomy results in diabetic macular oedema without evident vitreomacular traction. *Graefes Arch Clin Exp Ophthalmol.* 2001; 239 (4):264-70.
- Ophir A, Martinez MR, Mosqueda P, Trevino A. Vitreous traction and epiretinal membrane in diabetic macular edema using spectral domain OCT. *Eye* 2010;24 (10):1545-3.
- Arevalo JF, Maia M, Flynn Jr HW, Saravia M, Avery RL, Wu L et al. Tractional retinal detachment following intravitreal bevacizumab (Avastin) in patients with severe proliferative diabetic retinopathy. *Br J Ophthalmol* 2008; 92 (2): 213-16.