

# Necrolytic acral erythema: A rare entity

Saima Ilyas, Sara Masood Cheema, Tariq Rashid

Dermatology Department, Allama Iqbal Medical College/Jinnah Hospital, Lahore

**Abstract** Necrolytic acral erythema (NAE) is a rare but distinct clinical entity. It is one of the necrolytic erythemas that presents with itchy well-defined, dusky, erythematous to violaceous papules and plaques on acral areas. We report a case of a 50-year-old woman with 8-year history of itchy hyperpigmented papules and plaques on dorsum of both feet. Later, she developed similar lesions on both hands along with hemorrhagic blisters and purpura. She was found to be a hepatitis C virus (HCV) positive case. Histopathological findings were consistent with necrolytic acral erythema. She was treated with topical tacrolimus, oral zinc and cetirizine, and referred to medical outpatient department for treatment of HCV infection i.e. interferon and ribavirin.

**Key words**

Necrolytic acral erythema, hepatitis C virus infection, interferon, ribavirin.

## Introduction

Necrolytic acral erythema (NAE) is a clinical variant of necrolytic migratory erythema.<sup>1</sup> This entity is unique in its exclusive acral distribution, normal glucagon level and strong association with HCV infection. We describe a case of NAE who was diagnosed late in the course of disease, followed by a discussion on the subject.

## Case report

A 50-year-old housewife presented to our outpatient department with 8-year history of itchy erythematous papules on dorsa of both feet which coalesced and evolved into violaceous hyperpigmented plaques over a couple of weeks. These plaques gradually increased in size and extended up to both ankle joints and Achilles tendons in next 2 months. Similar lesions appeared on knuckles of both hands one and half

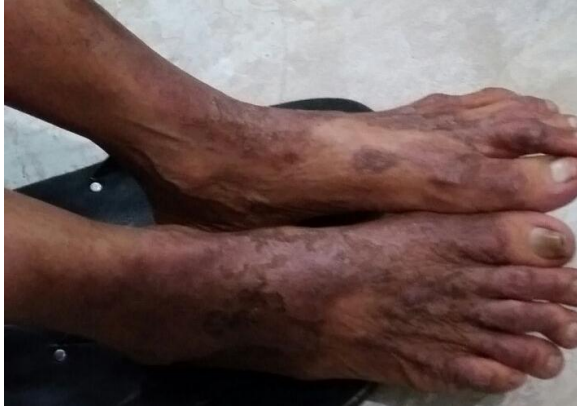year ago. There was history of recurrent pustular eruption within these plaques with yellowish fluid discharge. The patient also complained of hemorrhagic blisters and purplish lesions over arms and legs for the last 6 months. She had severe itching on these lesions and difficulty in closure of her hands and performance of her routine activities. During these 8 years, she had been treated on the lines of infected eczema with topical steroids along with oral and topical antibiotics repeatedly. Her skin lesions did not improve and itching was persistent.

Dermatological examination revealed well-defined, bilaterally symmetrical, hyperkeratotic, erythematous to violaceous, lichenified plaques on dorsal aspect of feet, ankles, Achilles tendons and lower one third of anterior surface of shins. Similar lesions were present on dorsa of proximal and distal interphalangeal joints of fingers of both hands (**Figure 1, 2 and 3**). There were discrete purpuric patches scattered over arms and crusted erosions along with excoriations were seen at places over arms and legs. Nail, hair and mucosae were normal.

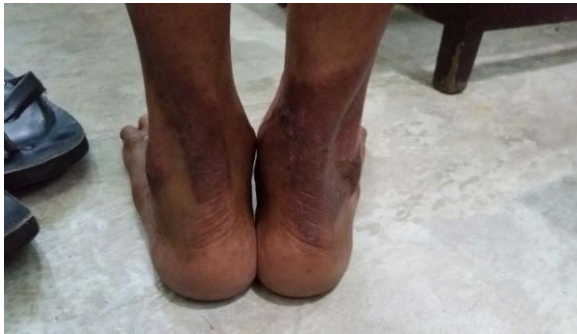---

**Address for correspondence**

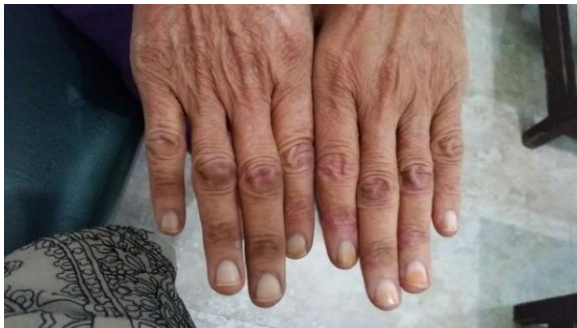Dr. Saima Ilyas, Senior Registrar,  
Dermatology Unit-I,  
Allama Iqbal Medical College/Jinnah Hospital,  
Lahore  
Email: drsaimaimc@gmail.com



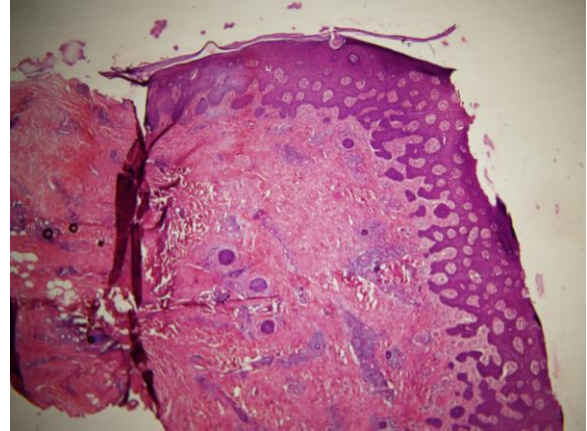
**Figure 1** Bilaterally symmetrical, hyperkeratotic, erythematous to violaceous, lichenified plaques on dorsal aspect of feet.



**Figure 2** Bilaterally symmetrical, hyperkeratotic, erythematous to violaceous, lichenified plaques on Achilles tendons.



**Figure 3** Bilaterally symmetrical, hyperkeratotic, erythematous to violaceous, lichenified plaques on interphalangeal joints.



**Figure 4** Histopathology showed psoriasiform hyperplasia, hyperkeratosis, parakeratosis, spongiosis and few necrotic keratinocytes in upper epidermis. In dermis perivascular inflammatory infiltrate and pigmentary incontinence were noted.

On laboratory analysis, hemoglobin was 11.1g/dl, white cell count 6800/mm<sup>3</sup>, platelet count 310000/mm<sup>3</sup>, ESR 30mm/1st hour, serum bilirubin 0.4mg/dl, SGPT 48U/l, ALP 177U/l, and blood sugar random 123mg/dl. Serum albumin and renal function tests were within normal limits. Anti-HCV antibodies were reactive by ELISA. Prothrombin time, activated thromboplastin time and ultrasound abdomen were normal.

Based on clinical findings, our differentials were following: chronic eczema, pustular psoriasis, hypertrophic LP, erythema elevatum diutinum and necrolytic acral erythema. Histopathology of the lesion revealed psoriasiform hyperplasia, hyperkeratosis, parakeratosis, spongiosis and few necrotic keratinocytes in upper epidermis. There was absence of basal cell degeneration. Dermis showed perivascular inflammatory infiltrate and pigmentary incontinence (**Figure 4**). Findings were suggestive of necrolytic acral erythema.

Patient was prescribed topical tacrolimus, oral zinc sulphate 200mg twice a day and tablet cetirizine 10mg daily. She was discharged and referred to medical OPD for treatment of HCV

infection (interferon alpha and ribavirin). She was advised follow-up at monthly intervals.

### **Discussion**

The necrolytic erythemas comprise a group of dermatoses that share similar clinical and histological features. Several necrolytic erythemas have been reported till date, which are associated with a specific metabolic abnormality. For example, necrolytic migratory erythema with high level of glucagon, acrodermatitis enteropathica with low zinc level, pellagra with niacin deficiency, biotin and fatty acid deficiency syndromes with low level of biotin and essential fatty acid respectively.<sup>2</sup>

Necrolytic acral erythema differs from other necrolytic erythemas in its limited acral distribution and strong association with HCV infection. It was originally described by EI Darouti and EI EIA in 1996.<sup>3</sup> The age of patients with NAE range from 11-60 years but onset typically occurs between 35-55 years. There is no sex predisposition reported in the literature.<sup>4</sup> It presents with sharply defined, tender, dusky, erythematous plaques with adherent scales. Lesions may be lichenified and associated with burning and/or pruritus. Classical site of involvement is dorsal surface of toes. The dorsum of hands may or may not be involved. Palms, soles, hair, nails and mucosae are usually not involved.<sup>5,6</sup> Histological findings are either eczematous or psoriasiform along with keratinocyte necrosis in upper epidermis. Clinically, the lesions of NAE may resemble eczema and histologically may demonstrate spongiosis. Well-defined lesions with a characteristic acral distribution, histological keratinocyte necrosis and non-responsiveness to topical corticosteroids differentiate it from eczema.

Exact cause of this condition is unknown. Suggested causes include hepatocellular degeneration from HCV infection, low zinc level, hypoalbuminemia and hypoaminoacidemia.<sup>6</sup> As HCV infection is present in almost all cases, NAE is considered as a significant cutaneous manifestation of HCV infection.<sup>7,8</sup>

NAE often resolves in patients who are successfully treated with ribavirin and/or interferon alpha.<sup>9</sup> The lesions may improve or clear with zinc sulphate supplementation. It has been observed that addition of zinc in therapeutic dose clears NAE lesions effectively in those patients who have normal serum zinc level. The reason might be that zinc levels in serum become low late in the course of zinc deficiency.<sup>10,11</sup>

Since its origin in 1996, less than 100 cases of NAE have been reported worldwide in the subsequent years. Majority of the cases are reported from Egypt where the prevalence of HCV infection is highest (15-20%) in the world.<sup>12</sup> Few cases of NAE associated with HCV infection have been published from United States.<sup>10</sup> Recently, some cases of NAE have been reported from Eastern India, Taiwan and United State which are seronegative for hepatitis C.<sup>13</sup> Pemet *et al.*<sup>14</sup> reported a case following hepatitis B vaccination. Although, Pakistan has the second highest prevalence rate of HCV infection ranging from 4.5% to 8%, but very few cases of NAE have been reported from here.<sup>15</sup> The possible reason can be less awareness of this relative rare entity and misdiagnosis due to its close resemblance with other dermatoses like chronic eczema, psoriasis and hypertrophic lichen planus.

### **Conclusion**

Awareness and knowledge of NAE is important not only for accurate dermatological diagnosis but also for the earlier diagnosis and treatment of hepatitis C infection.

## References

1. Rustin M, Cerio R. Necrolytic migratory erythema. In: Griffiths C, Barker J, Bleiker T, Chalmers R, Creamer D. *Rook's Textbook of Dermatology*, 9<sup>th</sup> edn. Oxford: Wiley Blackwell; 2016. P. 47.13-47.16
2. Shumez H, Prasad PVS, Kaviarasan PK, Viswanathan P. Necrolytic acral erythema: high degree of suspicion for diagnosis. *Int J Med Res Health Sci*. 2015;4:435-8.
3. El Darouti M, Abu El Ela M. Necrolytic acral erythema: a cutaneous marker of viral hepatitis C. *Int J Dermatol*. 1996;35:252-6.
4. Hayat W, Zahra K, Malik LM, Azfar NA, Jahangir M. Necrolytic acral erythema: an unusual cutaneous presentation of hepatitis C virus infection. *J Pak Assoc Dermatol*. 2012;22:66-9.
5. Yost JM, Boyd KP, Patel RR, Ramachandran S, Franks AG Jr. Necrolytic acral erythema. *Dermatol Online J*. 2013;19(12):20709
6. Bentley D, Andea A, Holzer A, Elewski B. Lack of classic histology should not prevent diagnosis of necrolytic acral erythema. *J Am Acad Dermatol*. 2009;60:504-7.
7. Abdallah MA, Ghozzi MY, Monib HA, Hafez AM, Hiatt KM *et al*. Necrolytic acral erythema: a cutaneous sign of hepatitis C virus infection. *J Am Acad Dermatol*. 2005;53:247-51.
8. Tabibian JH, Gerstenblith MR, Tedford RJ, Junkins-Hopkins JM, Abuav R. Necrolytic acral erythema as a cutaneous marker of hepatitis C: Report of two cases and review. *Dig Dis Sci*. 2010;55:2735-43.
9. Khanna VJ, Shieh S, Benjamin J, Somach S, Zaim MT, Dorner W Jr *et al*. Necrolytic acral erythema associated with hepatitis C: effective treatment with interferon alfa and zinc. *Arch Dermatol*. 2000;136:755-7.
10. Abdallah MA, Hull C, Horn TD. Necrolytic acral erythema: A patient from the United States successfully treated with oral zinc. *Arch Dermatol*. 2005;141:85-7.
11. Najarian DJ, Lefkowitz I, Balfour E, Pappert AS, Rao BK. Zinc deficiency associated with necrolytic acral erythema. *J Am Acad Dermatol*. 2006;55(5 Suppl):S108-10.
12. Raphael BA, Dorey-Stein ZL, Lott J, Amorosa V, Lo Re V 3<sup>rd</sup>, Kovarik C. Low prevalence of necrolytic acral erythema in patients with chronic hepatitis C virus infection. *J Am Acad Dermatol*. 2012;67(5):962-8.
13. Panda S, Lahiri K. Seronegative necrolytic acral erythema: A distinct clinical subset? *Indian J Dermatol*. 2010;55:259-61.
14. Pernet C, Guillot B, Araka O, Dereure O, Bessis D. Necrolytic acral erythema following hepatitis B vaccination. *Br J Dermatol*. 2014;171:1255-6.
15. Khattak MF, Salamat N, Bhatti FA, Qureshi TZ. Seroprevalence of hepatitis B, C and HIV in blood donors in northern Pakistan. *J Pak Med Assoc*. 2002;52:398-402.