

Alopecia areata: an update

Syed Suhail Amin, Sandeep Sachdeva

Department of Dermatology, JN Medical College, Aligarh Muslim University (AMU), Aligarh, India

Abstract Alopecia areata (AA) is a nonscarring, autoimmune hair loss on the scalp, and/or body. Etiology and pathogenesis are still unknown. The most common site affected is the scalp in the form of solitary or multiple patches of alopecia. Histopathology is characterized by an increased number of telogen follicles and presence of inflammatory lymphocytic infiltrate in the peribulbar region. Corticosteroids are the most popular drugs for the treatment of this disease. This review precisely outlines the etiologic and pathogenic mechanisms, clinical features, diagnosis and management of alopecia areata.

Key words

Alopecia areata, etiology, pathogenesis, management

Introduction

Alopecia areata (AA) is a common cause of nonscarring alopecia that occurs in a patchy, confluent or diffuse pattern. It may involve loss of hair from some or all areas of the body, usually from the scalp.¹ In 1%–2% of cases, the condition can spread to the entire scalp (alopecia totalis) or to the entire epidermis (alopecia universalis). AA has a reported incidence of 0.1–0.2% with a lifetime risk of 1.7% with men and women being affected equally.² Sharma *et al.* in their decade long prospective study observed an incidence of 0.7% among new dermatology outpatients.³ The etiology of AA has eluded investigators for years and, therefore, a multitude of associations have been proposed by researchers in the field of trichology. One of the strongest associations is that with autoimmunity.^{4,5} This view has been supported by the occurrence of AA in association with

other autoimmune disorders like vitiligo, lichen planus, morphea, atopic dermatitis, Hashimoto's thyroiditis, pernicious anemia and diabetes mellitus.⁶ More recently, it has been reported that there is a high prevalence of mood, adjustment, depressive and anxiety disorders in patients with AA.⁷ This element of psychiatric morbidity has widely been purported to be both, a cause and effect of AA. A multipronged approach is therefore warranted in the management of such patients. Though corticosteroids have been the mainstay in therapy, a wide array of evidence based therapies has come into force for management of AA. The present study attempts to systematically review the various aspects in the natural history of alopecia areata and the pros and cons in the different treatment modalities.

Dynamics of hair loss

Hair follicle growth occurs in cycles (**Figure 1**). Each cycle consists of a long growing phase (anagen), a short transitional phase (catagen) and a short resting phase (telogen). At the end of the resting phase, the hair falls out (exogen) and a new hair starts growing in the follicle beginning

Address for correspondence

Dr. Sandeep Sachdeva
3/115 A, Durgabadi, Marris Road,
Aligarh, UP, India 202002
Email: sandeepsemail@rediffmail.com
Ph# 00919359507294

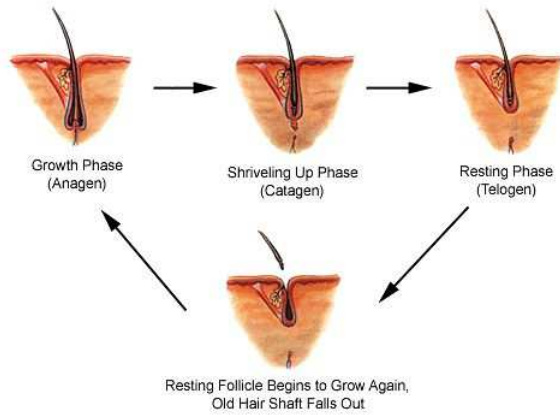


Figure 1 Phases of hair growth.

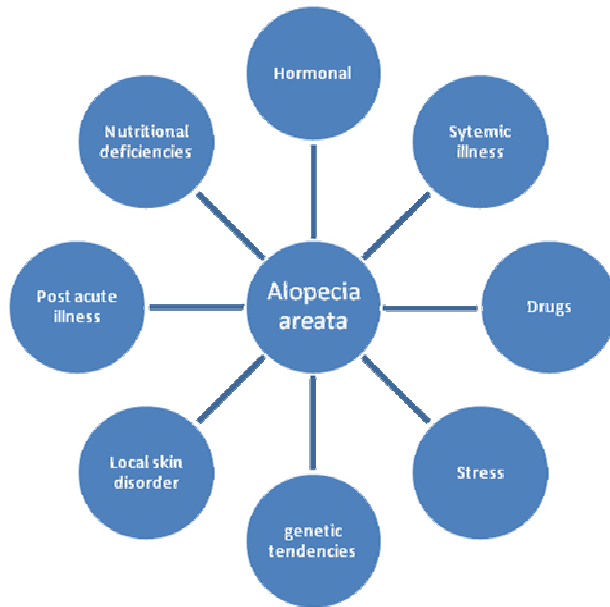

Figure 2 Multifactorial etiology of alopecia areata.

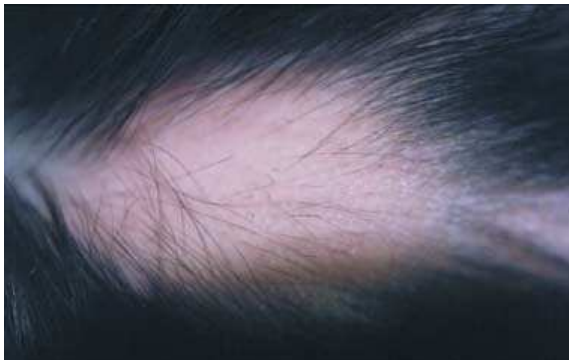

Figure 3 Localized patch of alopecia areata on scalp.

the cycle again. There are considerable variations in the length of the three phases, with the duration of the anagen determining the type of hair produced, particularly its length. Normally about 100 hairs reach the end of their resting phase each day and fallout.⁸ Hair loss in nonscarring alopecia, including alopecia areata essentially represents a disorder of hair follicle cycling.⁹ It is believed that in AA, an as yet unidentified trigger stimulates an autoimmune lymphocytic attack on the hair bulb. This inflammation is specific for anagen hairs and causes anagen arrest. A disruption of the growing phase, that is anagen arrest, causes abnormal loss of anagen hairs (anagen effluvium), clinically recognized as dystrophic anagen hair with tapered proximal ends and lack of root sheaths. A related but distinct entity observed very frequently in women is 'telogen effluvium'. This is an umbrella term inclusive of conditions wherein the affected hairs undergo an abrupt conversion from anagen to telogen (anagen release), clinically seen as localized shedding of hair in the telogen and morphologically identified as hair with a depigmented bulb.¹⁰

Etiopathogenesis

The etiology of AA has experienced considerable drift over the years and different schools of thought have assigned varied etiologies to the condition (**Figure 2**). A viral etiology was proposed in the late 1970s but subsequent articles have demonstrated no connection.¹¹ A genetic study by Yang *et al.*¹² found that 8.4% of the patients had a positive family history of AA, suggesting a polygenic additive mode of inheritance. It has now been widely postulated that AA is an organ-specific autoimmune disease with genetic predisposition and an environmental trigger.^{13,14} An association between AA and human leukocyte antigen

(HLA) has been demonstrated. Kavak *et al.*¹⁵ reported patients with AA had HLA-A1, HLA-B62, HLA-DQ1, and HLADQ3. Recently, in the United States, Barahmani *et al.*¹⁶ demonstrated that a non-HLA molecule including the major histocompatibility complex class I chain-related gene A (MICA) is associated with AA. It could be a potential candidate gene and part of an extended HLA haplotype that may contribute to susceptibility to and severity of this entity. HLA class I molecules are expressed on virtually all nucleated cells and platelets and present antigens to CD8+ T cells. HLA class II molecules have three main subclasses (DR, DQ, and DP); they are found on specific immune cells, including B cells, activated T cells, macrophages, keratinocytes, and dendritic cell and present peptides to CD4+ T cells. Because class II molecules are associated with antigen presentation, many studies have focused on this area of the HLA molecule.¹⁷

These associations with HLA-DR and HLA-DQ suggest a role for T cells in this disease, as well as, autoimmunity. Patients with AA have an increased frequency of autoantibodies to follicular structures; however, there is little consistency in which follicular structures are labeled by the antibodies.¹⁸ Other diseases that are reported to be associated with AA are at higher rate than the normal population are atopic dermatitis, vitiligo, thyroid disease, and Down syndrome.¹⁹ Most of the research in the field of AA thus demonstrates a strong case for the implication of autoimmunity in the etiopathogenesis. Other potential offenders proposed in the causation of AA are psychologic stress, anemia, parasitic infestations, hypothyroidism, hyperthyroidism and diabetes.

Clinical features

The diagnosis of AA is essentially made on clinical grounds. Age at onset, duration and progression of disease, personal and family history of atopy, family history of similar disease with special reference to autoimmune disease and other systemic complaints are noted in detail. Routine investigations like complete hemogram, anemia panel, erythrocyte sedimentation rate, thyroid function tests, serum calcium, serum proteins etc. should be carried out to arrive at a specific diagnosis. Skin biopsy and autoimmune panel may be performed in selected cases. Alopecia areata most commonly manifests as a sudden loss of hair in localized areas. The lesion is usually a round or oval patch of alopecia and may be solitary (alopecia areata monocularis) or numerous (alopecia areata multilocularis). The patch of alopecia usually has a distinct border where normal hair demarcates the periphery of the lesion (**Figure 3**). The scalp is the most common site affected by AA (90%).^{19,20} Scalp and body hair such as eyebrows, eyelashes, beard, underarm hair, and pubic hair may be affected (alopecia totalis), as well as, the entire body (alopecia universalis). The ophiasis pattern refers to a severe form of AA extending along the posterior occipital and temporal scalp margins. The affected skin appears normal with no grossly evident epidermal alterations such as scaling or follicular abnormalities.²¹ In all forms “exclamation point hairs” are found, that become narrower along the length of the strand closer to the base may be seen within or around the areas of alopecia.²² Upon regrowth, hair often initially lack pigment resulting in blonde or white hair.²³ Nail changes can be seen in a portion of patients (10-66%) of AA. Small shallow pits (30%) up to trachyonychia (sandpaper nails; 10%) are typical, rarely other changes. A red-spotted lunula and periungual

erythema have been postulated as a sign of acute nail involvement.²⁴

Quantitating hair loss

Hair pull tests conducted at the periphery of the lesion may be correlated with disease activity and also assist in determining the etiology of alopecia. A few clinical tests are presented as under:

- *The pull test* this test helps to evaluate diffuse scalp hair loss. Gentle traction is exerted on a group of hair (about 40–60) on three different areas of the scalp. The number of extracted hairs is counted and examined under a microscope. Normally, <3 hairs per area should come out with each pull. If >10 hairs are obtained, the pull test is considered positive.
- *The pluck test* In this test, the individual pulls hair out “by the roots.” The root of the plucked hair is examined under a microscope to determine the phase of growth and used to diagnose a defect of telogen, anagen, or systemic disease. Telogen hairs are hairs that have tiny bulbs without sheaths at their roots. Telogen effluvium shows an increased percentage of hairs upon examination. Anagen hairs are hairs that have sheaths attached to their roots. Anagen effluvium shows a decrease in telogen-phase hairs and an increased number of broken hairs.
- *Scalp biopsy* This test is done when alopecia is present, but the diagnosis is unsure. The biopsy allows for differing between scarring and non-scarring forms in case there is clinical distinction is difficult. Hair samples are taken from

areas of inflammation, usually around the border of the bald patch.

- *Daily hair counts* This is normally done when the pull test is negative. It is done by counting the number of hairs lost. The hair that should be counted is the hair from the first morning combing or during washing. The hair is collected in a clear plastic bag for 14 days. The strands are recorded. If the hair count is >100/day is considered abnormal except after shampooing, where hair counts will be up 250 and be normal.
- *Trichoscopy* is a non-invasive method of hair and scalp. The test may be performed with the use of a handheld dermoscope or a videodermoscope. In alopecia areata trichoscopy shows regularly distributed "yellow dots" (hyperkeratotic plugs), micro-exclamation mark hairs, and "black dots" (destroyed hairs in the hair follicle opening).

Nails as described earlier, show changes in the form of pitting or trachyonychia.²⁵ Stigmata of organ specific autoimmunity may be present on systemic examination.

Gauging severity of disease Researchers have devised a clinical scale in order to assess the severity of AA,¹⁵ presented as under:

1. *Mild* Three or less patches of alopecia with a widest diameter of less than 3 cm or disease limited to eyelashes and eyebrows.
2. *Moderate* Existence of more than three patches of alopecia or a patch greater than 3 cm at the widest diameter without alopecia totalis or universalis.

3. *Severe Alopecia totalis* or alopecia universalis.
4. *Ophiasis* Severe form in which loss of hair occurs in the shape of a wave at the circumference of the head (described above).

The National Alopecia Areata Foundation working committee has devised "Severity of Alopecia Tool score" (SALT score).²⁶ Scalp is divided into 4 areas namely, Vertex - 40% (0.4) of scalp surface area; right profile of scalp - 18% (0.18) of scalp surface area; left profile of scalp - 18% (0.18) of scalp surface area; Posterior aspect of scalp - 24% (0.24) of scalp surface area. Percentage of hair loss in any of these areas is percentage hair loss multiplied by percent surface area of the scalp in that area. SALT score is the sum of percentage of hair loss in all above mentioned areas.

Differential diagnosis

Though alopecia areata is a form of nonscarring alopecia, it is sometimes confused with different varieties of scarring alopecia as well. This is also because many alopecia types are biphasic in their natural history. The first step, therefore, is to distinguish between scarring and nonscarring alopecia. Scarring alopecia has loss of follicular ostia, or atrophy. Clinical inflammation is frequently, but not always, present. Histologic inflammation may be present. Ultimately, histologic confirmation is the best method to confirm the presence of a fibrosing/scarring process with loss of hair follicles. A few entities in scarring alopecia are lichen planopilaris, central centrifugal cicatricial alopecia, pseudopelade, discoid lupus erythematosus and traction alopecia. The main confounders in diagnosis are the other varieties of nonscarring alopecia. They are:

- *Trichotillomania* this condition probably causes most confusion and it is possible that it coexists with alopecia areata in some cases. The incomplete nature of the hair loss in trichotillomania and the fact that the broken hairs are firmly anchored in the scalp (i.e. they remain in the growing phase, anagen, unlike exclamation mark hairs) are distinguishing features.
- *Tinea capitis* the scalp is inflamed in tinea capitis and there is often scaling but the signs may be subtle
- *Early scarring alopecia*
- *Telogen effluvium*
- *Anagen effluvium* (drug-induced) may mimic diffuse alopecia areata
- *Systemic lupus erythematosus*
- *Secondary syphilis*
- *Loose anagen hair syndrome* This is a disorder of abnormal anagen hair anchorage. It is commonly found in children and has an autosomal dominant inheritance.²⁷
- *ADTA* Acute diffuse and total alopecia (ADTA) is a new subtype of alopecia areata with favorable prognosis. ADTA has been reported to have a short clinical course ranging from acute hair loss to total baldness, followed by rapid recovery, sometimes even without treatment.²⁸
- *SISAPHO* This is an unusual form of alopecia in which a band-like pattern is found on the frontal hairline. This can be clinically confused with frontal fibrosing alopecia. The opposite of ophiasis type, where hairs are lost centrally and spared at the margins of the scalp, is called sisiapho. It may mimic androgenetic alopecia.²⁹

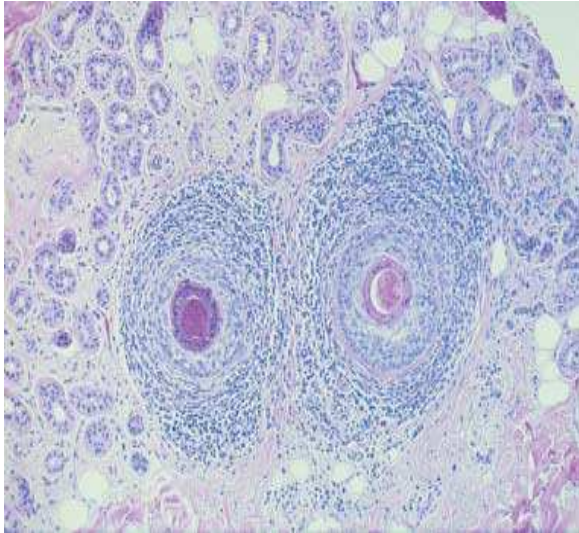


Figure 4 Swarm of bees' appearance of the inflammatory infiltrate around terminal hair follicles in alopecia areata (H&E stain).

Raunatha *et al.* in their case report have demonstrated infantile scurvy also, as a cause of diffuse non scarring alopecia of the scalp.³⁰

Histopathology

The histopathologic features of alopecia areata depend on the stage of the current episode and do not vary with the age, sex or race of the patient.³¹ In the acute stage, terminal hairs are surrounded by bulbar lymphocytes ('swarm of bees') [Figure 4]. In the subacute stage, decreased anagen and increased catagen and telogen hairs are characteristically found. In the chronic stage, decreased terminal and increased miniaturized hairs are found, with variable inflammation. Immunofluorescence studies have shown deposits of C3, IgG, and IgM along the basement membrane of the inferior part of the hair follicle.³² During recovery, increasing numbers of terminal anagen hairs from regrowth of miniaturized hairs and a lack of inflammation are noted. Alopecia areata should histologically be suspected when high percentages of telogen hair or miniaturized hair are present, even in the absence of a peribulbar lymphocytic infiltrate.

The histopathology of the lesion in ADTA reveals infiltration of mononuclear cells around the hair follicles and prominent pigment incontinence.²⁸

Management

Management of patients with alopecia areata is a challenging task as a number of risk factors have been implicated in its etiology. No definitive cure has been established, and treatment has focused mainly on containing disease activity.

1. Glucocorticoids

Glucocorticoids have been the mainstay of therapy, and have been used via topical, oral and parenteral routes for the same. Glucocorticoids have been harnessed for their overarching anti-inflammatory effects for AA.³³

Intralesional corticosteroids

For circumscribed AA involving less than 50% of the scalp, intralesional corticosteroids are the first-line approach.³⁴ Triamcinolone acetonide in a concentration of 10 mg/ml is administered using a 0.5-inch long 30-gauge needle in multiple 0.1 mL injections approximately 1 cm apart.³⁵ Initial results of intralesional treatment are often seen in 1–2 months. Additional treatments are repeated every 4–6 weeks.

Topical corticosteroids

Several forms of topical corticosteroids have been reported to exhibit varying levels of efficacy in AA. Some of the topical therapies have included fluocinolone acetonide cream, fluocinolone scalp gel, betamethasone valerate lotion and clobetasol propionate ointment.^{36,37} They remain a very good option in children because of their painless application and wide safety margin.

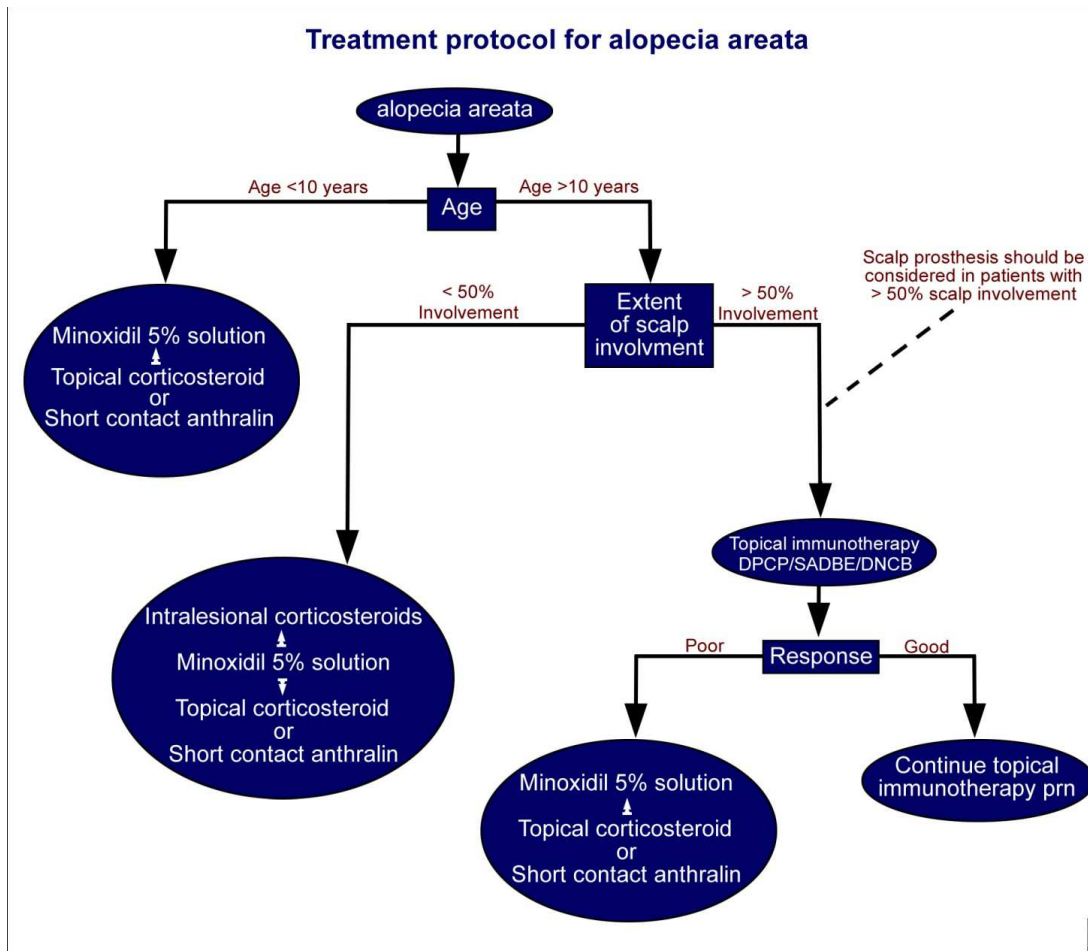


Figure 5 Algorithm for management of Alopecia areata in different age groups. (*Adapted with permission from the Editor, *J Am Acad Dermatol.* 2010;62:191-202).

Systemic corticosteroids

The suggested dosages of prednisolone are 1 mg/kg/day for adults and 0.1–1 mg/kg/day for children.²¹ The dosages necessary to maintain hair regrowth in AA are between 30 and 150 mg daily.³⁸ Treatment course can range from 1 to 6 months, but prolonged courses should be avoided secondary to the numerous side effects of these drugs especially when children are treated. Its side effect profile in conjunction with the long-term treatment requirements and high relapse rates make systemic corticosteroids a more limited option. Friedli *et al.*³⁹ have also reported successful therapy with pulsed methylprednisolone (250 mg IV twice daily for 3 consecutive days) in patchy AA. Contraindications and side effects should

however be discussed at length with patients considered for this therapy.

Oral mini pulse steroids Daily oral corticosteroids have high efficacy, however their long-term use may result in serious side effects like development of hypertension, diabetes and suppression of the HPA axis. To avoid these side effects, pulse therapy was conceived. In a study conducted by Pasricha *et al.*⁴⁰ betamethasone oral mini-pulse therapy is a convenient and fairly effective treatment modality for extensive alopecia areata. However, it is proposed that randomized controlled trials with standard therapies on a larger number of patients are required to give more insight into the efficacy and safety of oral mini-pulse therapy for

extensive alopecia areata Oral mini-pulse therapy (OMP) with corticosteroids has been successfully used for the treatment of alopecia areata with minimal side effects. Persistent hiccups is a rare complication of oral and intravenous corticosteroid therapy.⁴¹

2. Minoxidil

First introduced as an antihypertensive agent, its side effect of hypertrichosis led to its use as treatment for various forms of alopecia. Minoxidil directly affects follicles by stimulating proliferation at the base of the bulb and differentiation above the dermal papilla, independent of its vascular influences.⁴² Minoxidil has shown considerable results in the management of AA and it is believed that patients resistant to minoxidil treatment often suffer from severe AA, AT or AU.^{43,44} Combination therapy of minoxidil 5 % lotion and anthralin have been documented to show better results by few authors.⁴⁵

3. Anthralin

Anthralin exerts its effect through its irritant contact properties. It also acts through its immunosuppressive and anti-inflammatory properties via the generation of free radicals.³⁵ Patients are instructed to apply 0.5-1% anthralin cream to bare areas for 20-30 min daily over 2 weeks, gradually increasing daily exposure until low-grade erythema and pruritus develops, which when once achieved is continued for 3 to 6 months.⁴⁶ It is believed to be a suitable agent for children under 10 years of age.⁴⁷ Adverse effects include scaling, staining of treated skin and fabrics, folliculitis, and regional lymphadenopathy.

4. Topical immunomodulators

Topical immunotherapy relies on inciting an allergic contact dermatitis (ACD) by applying potent contact allergens to the affected skin. It is believed that contact sensitizers act through immunomodulation of the skin and its appendages at several different points. Dinitrochlorobenzene (DNCB) was the first sensitizer used for the treatment of AA.⁴⁸ Other contact sensitizers used in alopecia areata are diphenyl-cyclo-propenone (DPCP) and squaric acid dibutyl ester (SADBE).⁴⁹ The only disadvantage of DNCB is its mutagenicity by Ames test. DNCB was however found non-carcinogenic when fed in large doses in rats, mice, guinea pigs and man. Happle and Edernacht⁵⁰ had a good response with DNCB. Inosiplex, a synthetic drug that acts as an immunomodulating agent was used recently in cases of alopecia totalis and cell mediated immunodeficiency states with satisfactory results.⁵¹ Adverse effects of topical immunotherapy include pruritus, mild erythema, scaling, and postauricular lymphadenopathy. Reported undesired side effects include contact urticaria, postinflammatory hyper- and hypopigmentation, erythema multiforme, facial or eyelid edema, fever, flulike symptoms, anaphylaxis, "dyschromia in confetti," and vitiligo.

5. PUVA

The use of PUVA (psoralen plus ultraviolet light A) is based on the concept that the mononuclear cells and Langerhans cells that surround the affected hair follicles may play a direct pathogenic role and that PUVA therapy can eradicate this inflammatory cell infiltrate. Recently, Whitmont did a study with 8-methoxypsoralen (8-MOP) (oral dose-0.5 mg/kg) plus UVA radiation at 1 J/cm² and have demonstrated complete hair regrowth in patients with AA totalis (53%) and AA universalis (55%)

and a low relapse rate among these patients (21%) within a long period of follow up (means 5.2 years).⁵² In 2005, Mohamed *et al.*⁵³ did a large study (124 patients with AA and 25 patients with AA totalis or universalis). They used topical 8-MOP plus UVA radiancy at higher doses (8-42 J/cm²) and they found that 85% of patients from the AA group had good or excellent response to the treatment, and 14 patients from AA-U group had 50% hair regrowth. Side effects included slight erythema and painful burning in patients who did not protect their scalp from sunlight after PUVA exposure. Recurrence of hair loss was noted in eight cases after a period of 10 months to 2 years of treatment.

The relatively simple procedure of PUVASOL therapy (local and systemic) because of good availability of solar radiation, negligible side effects, encouraging results and non-availability of various other procedures and frequent treatment failures with these treatment schedules makes this procedure better suited in the tropics.⁵⁴

6. Cyclosporine A (CsA)

Cyclosporine A is a common antimetabolite drug used in post-transplantation patients which exerts its effect via inhibition of T-cell activation. A common cutaneous side effect is hypertrichosis, which occurs in approximately 80% of patients, possibly as a result of prolongation of the anagen phase of the hair cycle. It also decreases the perifollicular lymphocytic infiltrates, particularly the mean number of helper T cells.⁵⁵ Successful use of systemic CsA in patients with AA has been conflicting as it is a nephrotoxic, hepatotoxic drug, it also causes gingival hyperplasia, headaches, tremors, and hyperlipidemia.⁵⁶

7. Tacrolimus

Tacrolimus is a topical calcineurin inhibitor that inhibits transcription following T-cell activation of several cytokines including interleukin-2, interferon-and tumor necrosis factor.⁵⁷ Yamamoto *et al.*⁵⁸ reported in their findings that tacrolimus stimulated hair growth in mice although subsequent studies showed conflicting results.⁵⁹

8. Sulfasalazine

Sulfasalazine is believed to be a good alternative treatment for alopecia areata because of its good efficacy, good adverse event profile and steroid sparing nature. The drug has immunosuppressive and immunomodulatory effects, including the inhibition of inflammatory cell chemotaxis, and cytokine and antibody production and similar to cyclosporine, sulfasalazine has been shown to inhibit the release of interleukin 2.⁶⁰ In a study on treatment of persistent alopecia areata with sulfasalazine. Thirty-nine patients with persistent alopecia areata received 3 g of oral sulfasalazine for months, and terminal hair regrowth was quantified as no response, moderate response, or good response. A good response occurred in 10 of the 39 patients (25.6%), a moderate response in 12 (30.7%), and a poor or no response in 17 (43.5%).⁶¹

9. Mesotherapy

Mesotherapy employs multiple injections of pharmaceutical and homeopathic medications, plant extracts, vitamins, and other ingredients into the target tissue. In treatment of alopecia, mesotherapy can be of help by causing hair regrowth by delivering medications into the middle layer under the skin. Olsen⁶² concluded from their study that minoxidil injected by

mesotherapy is more efficient than that of topical application in treatment of female pattern hair loss.

10. Biological therapy

These medications synthesized from recombinant proteins reduce the pathogenic T cells, inhibit T-cell activation and inhibit inflammatory cytokines, suggesting a potential role in the treatment of AA. Etanercept is a biological agent and a fusion protein receptor consisting of two human TNF receptors and Fc domain of human immunoglobulin G1. Strober *et al.*⁶³ administered 50 mg of etanercept twice weekly to patients with moderate to severe AA. They however observed no significant hair regrowth after 24 weeks of treatment. Studies with other biological agents in the treatment of AA are still underway. In cases where all the treatments fail, other options that have been reported for AA are hair transplant, but recently it has only been performed in eyebrows with good results. Another alternative is micropigmentation, also known as tattoo; it has been used aesthetically to camouflage various medical conditions related to dermatology.

Conclusion

Alopecia areata has a great impact on the appearance and psyche of the afflicted individual. Moreover, no uniformly dependable treatment is known. Corticosteroids have shown promising results and are time tested drugs in management over the years. Other treatments that have been used with some success include: minoxidil, anthralin, DNCB, SADBE, PUVA, cyclosporine. With each treatment, side effects and cosmetically acceptable improvement must be considered. Support mechanisms in the form of local support groups should be formed in order to provide counseling for the affected

patients and allay their psychiatric comorbidities.

References

1. James WD, Berger TG, Elston DM. *Andrews' Diseases of the Skin: Clinical Dermatology*. 10th edn. Philadelphia: Saunders Elsevier; 2006.
2. Safavi KH, Muller SA, Suman VJ *et al.* Incidence of alopecia areata in Olmsted County, Minnesota, 1975 through 1989. *Mayo Clin Proc*. 1995;**70**:628-33.
3. Sharma VK, Dawn G, Kumar B. Profile of alopecia areata in Northern India. *Int J Dermatol*. 1996;**35**:22-7.
4. McDonagh AJ, Tazi-Ahnini R. Epidemiology and genetics of alopecia areata. *Clin Exp Dermatol*. 2002;**27**:405-9.
5. Hordinsky M, Ericson M. Autoimmunity: Alopecia areata. *J Invest Dermatol Symp Proc*. 2004;**9**:73-8.
6. Brenner R. Coincidences of alopecia areata, vitiligo, onychodystrophy, localized scleroderma and lichen planus. *Dermatologica*. 1979;**159**:356-8.
7. Ruiz-Doblado S, Carrizosa A, Garcia-Hernandez MJ. Alopecia areata: psychiatric comorbidity and adjustment to illness. *Int J Dermatol*. 2003;**42**:434-7.
8. Trueb RM. Systematic approach to hair loss in women. *Indian Clin Updates-Dermatology* 2010;**2**:284-97.
9. Paus R. Control of the hair cycle and hair diseases as cycling disorders. *Curr Opin Dermatol*. 1996;**3**:248-58.
10. Wasserman D, Guzman-Sanchez DA, Scott K, McMichael A. Alopecia areata. *Int J Dermatol*. 2007;**46**:121-31.
11. Tosti A, La Placa M, Placucci F *et al.* No correlation between cytomegalovirus and alopecia areata. *J Invest Dermatol*. 1996;**107**:443.
12. Yang S, Yang J, Liu JB *et al.* The genetic epidemiology of alopecia areata in China. *Br J Dermatol*. 2004;**151**:16-23.
13. McMichael AJ. The genetic epidemiology of autoimmune pathogenesis alopecia areata. *J Eur Acad Dermatol Venereol*. 1997;**9**:36-43.
14. McDonagh AJ, Tazi-Ahnini R. Epidemiology and genetics of alopecia areata. *Clin Exp Dermatol*. 2002;**27**:405-9.

15. Kavak A, Baykal C, Ozarmagan G, Akar U. HLA in alopecia areata. *Int J Dermatol*. 2000;**39**:598-92.
16. Barahmani N, de Andrade M, Slusser JP *et al*. Major histocompatibility complex class I chain-related gene A polymorphisms and extended haplotypes are associated with familial alopecia areata. *J Invest Dermatol*. 2006;**126**:74-8.
17. Hordinsky M, Ericson M. Autoimmunity: Alopecia areata. *J Invest Dermatol Symp Proc*. 2004;**9**:73-8.;
18. Gilhar A, Kalish R. Alopecia areata: a tissue-specific autoimmune disease of the hair follicle. *Autoimmunity Rev*. 2006;**5**:64-9.
19. Tan E, Tay Y-K, Goh CL *et al*. The pattern of alopecia areata in Singapore – a study of 219 Asians. *Int J Dermatol*. 2002;**41**:748-53.
20. Tan E, Tay YK, Giam YC. A clinical study of childhood alopecia areata in Singapore. *Pediatric Dermatol*. 2002;**19**:298-301.
21. Camacho F. Alopecia areata. Clinical characteristics and dermatopathology, in *Trichology: diseases of the pilosebaceous follicle 1997*, Madrid, Aula Medical Group, S. A. 471–440.
22. Zoe Diana Draelos (August 30, 2007), Alopecia Areata. MedicineNet.com. Retrieved on May 11 , 2011.
23. Cline DJ. Changes in hair color. *Dermatol Clin*. 1988;**6**:295-303.
24. Finner AM. Alopecia areata: Clinical presentation, diagnosis, and unusual cases. *Dermatol Ther*. 2011;**24**:348-54.
25. Olsen EA. Hair. In: Freedberg IM, editors. *Fitzpatrick's Dermatology in General Medicine*. New York: McGraw-Hill; 2003. P.641-3.
26. Olsen EA, Hordinsky MK, Price VH *et al*. National Alopecia Areata Foundation. Alopecia areata investigational assessment guidelines. part II. National Alopecia Areata Foundation. *J Am Acad Dermatol*. 2004;**51**:440-7.
27. Price VH, Gummer CL. Loose anagen syndrome. *J Am Acad Dermatol*. 1989;**20**:249-56.
28. Lew B-L, Shin M-K, Sim W-Y. Acute diffuse and total alopecia: A new subtype of alopecia areata with a favorable prognosis. *J Am Acad Dermatol*. 2009;**60**:85-93.
29. Garcia-Hernandez MJ. CFM. Atypical clinical forms of alopecia areata. In: Camacho Francisco MR, Price Vera H, eds. *Hair and its Disorders: Biology, Pathology, and Management*. London: Martin Dunitz; 2000. P.228-31.
30. Ragunatha S, Inamadar AC, Palit A *et al*. Diffuse nonscarring alopecia of scalp: an indicator of early infantile scurvy? *Pediatr Dermatol*. 2008;**25**:644-6.
31. Whiting DA. Histopathologic features of alopecia areata: a new look. *Arch Dermatol*. 2003;**139**:1555-9.
32. Igarashi R, Moroashi M, Takeuchi S. Immunofluorescence studies on complement components in the hair follicles of normal scalp and of scalp affected by alopecia areata. *Acta Derm Venereol*. 1981;**61**:131-5.
33. Shimmer BP, Parker KL, eds. *Goodman's and Gillman's: The Pharmacological Basis of Therapeutics*. New York: McGraw-Hill; 2001. P.1661-3.
34. Ross EK, Shapiro J. Management of hair loss. *Dermatol Clin*. 2005;**23**:227-43.
35. Madani S, Shapiro J. Alopecia areata update. *J Am Acad Dermatol*. 2000;**42**:549-66.
36. Pascher F, Kurtin S, Andrade R. Assay of 0.2 percent fluocinolone acetonide cream for alopecia areata and totalis. Efficacy, side effects including histologic study ensuing localized acneiform response. *Dermatologica*. 1970;**141**:193-202.
37. Tosti A, Piraccini BM, Pazzaglia M *et al*. Clobetasol propionate 0.05% under occlusion in the treatment of alopecia totalis/universalis. *J Am Acad Dermatol*. 2003;**49**:96-8.
38. Burton JL, Shuster S. Large doses of glucocorticoid in the treatment of alopecia areata. *Acta Derm Venereol*. 1975;**55**:493-6.
39. Friedli A, Labarthe MP, Engelhardt E *et al*. Pulse methylprednisolone therapy for severe alopecia areata: an open prospective study of 45 patients. *J Am Acad Dermatol*. 1998;**39**:597-602.
40. Pasricha JS, Kumrah L. Alopecia totalis treated with oral mini-pulse (OMP) therapy with betamethasone. *Indian J Dermatol Venereol Leprol*. 1996;**62**:106-9.
41. Dickerman RD, Jaikumar S. The hiccup reflex arc and persistent hiccups with high dose anabolic steroids: Is the brainstem the steroid-responsive locus? *Clin Neuropharmacol*. 2001;**24**:62-4.
42. Fiedler VC, Wendrow A, Szpunar GJ *et al*. Treatment resistant alopecia areata. Response to combination therapy with minoxidil plus anthralin. *Arch Dermatol*. 1990;**126**:756-9.

43. Buhl AE. Minoxidil's action in hair follicles. *J Invest Dermatol.* 1991;**96**:73S-74S.
44. Fransway AF, Muller SA. 3 Percent topical minoxidil compared with placebo for the treatment of chronic severe alopecia areata. *Cutis.* 1988;**41**:431-5.
45. Price VH. Double-blind, placebo-controlled evaluation of topical minoxidil in extensive alopecia areata. *J Am Acad Dermatol.* 1987;**16**:730-6.
46. Ross EK, Shapiro J. Management of hair loss. *Dermatol Clin.* 2005;**23**:227-43.
47. Thappa DM, Vijayikumar M. Alopecia areata. *Indian J Dermatol Venereol Leprol.* 2001;**67**:187-90.
48. Rosenberg EW, Drake L. In: Discussion of Dunaway DA. Alopecia areata. *Arch Dermatol.* 1976;**112**:256.
49. Van der Steen PH, van Baar HM, Happle R *et al.* Prognostic factors in the treatment of alopecia areata with diphenylcyclopropenone. *J Am Acad Dermatol.* 1991;**24**:227-30.
50. Happle R, Echternacht K. Induction of hair growth in alopecia areata with DNCB. *Lancet.* 1977;**2**:1002-3.
51. Galbraith GMP, Thiers BH, Fundenberg HH. An open-label trial of immunomodulation therapy with Inosiplex (Isoprinosine) in patients with alopecia totalis and cell mediated immunodeficiency. *J Am Acad Dermatol.* 1984;**11**:224-30.
52. Whitmont K, Cooper A. PUVA treatment of alopecia areata totalis and universalis: a retrospective study. *Australas J Dermatol.* 2003;**44**:106-9.
53. Mohamed Z, Bhourri A, Jallouli A *et al.* Alopecia areata treatment with a phototoxic dose of UVA and topical 8-methoxypsoralen. *J Eur Acad Dermatol Venereol.* 2005;**19**:552-5.
54. Sharma PK, Jain RK, Sharma AK. PUVASOL therapy in alopecia areata. *Indian J Dermatol Venereol Leprol.* 1990;**56**:301-3
55. Taylor M, Ashcroft AT, Messenger AG. Cyclosporin A prolongs human hair growth in vitro. *J Invest Dermatol.* 1993;**100**:237-9.
56. Gupta AK, Ellis CN, Nickoloff BJ *et al.* Oral cyclosporine in the treatment of inflammatory and noninflammatory dermatoses. A clinical and immunopathologic analysis. *Arch Dermatol.* 1990;**126**:339-50.
57. Lawrence ID. Tacrolimus (FK506): experience in dermatology. *Dermatol Ther.* 1998;**5**:74-84.
58. Yamamoto S, Jiang H, Kato R. Stimulation of hair growth by topical application of FK506, a potent immunosuppressive agent. *J Invest Dermatol.* 1994;**102**:160-4.
59. Jiang H, Yamamoto S, Kato R. Induction of anagen in telogen mouse skin by topical application of FK506, a potent immunosuppressant. *J Invest Dermatol* 1995;**104**:523-5.
60. Ellis CN, Brown MF, Voorhees JJ. sulfasalazine for alopecia areata. *J Am Acad Dermatol.* 2002;**46**:541-4.
61. Rashidi T, Mahd AA. Treatment of persistent alopecia areata with sulfasalazine. *Int J Dermatol.* 2008;**47**:850-2.
62. Olsen AE. Female pattern hair loss. *J Am Acad Dermatol.* 2001;**45**:S70-80.
63. Strober B, Siu K, Alexis A *et al.* Etanercept does not effectively treat moderate to severe alopecia areata: an open-label study. *J Am Acad Dermatol.* 2005;**52**:1082-4.