

## Using Diode Laser for Soft Tissue Incision of Oral Cavity

Reza Amid<sup>1</sup>, Mahdi Kadkhodazadeh<sup>1</sup>, Mohammad Reza Talebi Ardakani<sup>1</sup>, Somayeh Hemmatzadeh<sup>2</sup>  
Soheil Refoua<sup>2</sup>, Parastoo Iranparvar<sup>2</sup>, Anahita Shahiz

<sup>1</sup>Dental Research Center, Department of Periodontics, Shahid Beheshti University of Medical Sciences, Tehran, Iran  
<sup>2</sup>School of Dentistry, Department of Periodontics, Shahid Beheshti University of Medical Sciences, Tehran, Iran

### Abstract:

**Introduction:** The purpose of this case report is to analyze the results of vestibuleplasty around an over-denture based on dental implants to determine the evidence on the effectiveness of laser-assisted surgery and soft tissue management in implant dentistry.

**Case Report:** The patient in this case report was a 57 year- old male who was completely edentulous, with a mandibular over denture based on 4 standard implants suffering from pain on chewing, and a general discomfort, especially in anterior segment. He received a standard gingival augmentation surgery which failed to create sufficient vestibular depth. A laser-assisted vestibuloplasty was done to make the environment suitable for making a new overdenture.

**Conclusions:** There were clinically significant improvements in vestibular depth and peri implant soft tissue situation by laser. Also, bleeding during surgery was well controlled; the patient's discomfort and pain were less than the first operation done with gingival graft. Based on our clinical data and review of the literature, an evidence-based approach to the use of lasers for the management of soft tissue in oral surgery is necessary. Simply, there is insufficient evidence to suggest that any specific wavelength of laser is superior to the traditional modalities of therapy. However, improved hemostasis and patient's satisfaction can be considered as advantages of adjunctive laser therapy in some clinical situations like vestibuloplasty.

**Keywords:** diode Laser; overdenture; vestibuloplasties

---

Please cite this article as follows:

Amid R, Kadkhodazadeh M, Talebi MR, Hemmatzadeh S, Refoua S, Iranparvar P, Shahi A. Using Diode Laser for Soft Tissue Incision of Oral Cavity: J Lasers Med Sci 2012; 3(1):36-43

---

\*Corresponding Author: Mahdi Kadkhodazadeh, DDS, MS; Department of Periodontics, Shahid Beheshti University of Medical Sciences, Tehran, Iran; Tel: +98-912-760-8346; Fax: +98-21-2219-0224; Email: kadkhodazadehmahdi@yahoo.com

### Introduction

Dentistry has seen many great improvements in the field of instruments through years. Many instruments have been invented for performing incisions, scaling, root planning, etc. However, there has always been a concern in patients regarding these instruments. For example, fear of the pain from incision by scalpel in spite of anesthesia in

location or the fear of the noises coming from devices, such as scaling instruments. On the other hand, using scalpels is easy, but these instruments fail to make hemostasis in the surgical site (1). More or less, different lasers may be able to reduce patients' fear and pain and also can make great hemostasis in the surgery field besides many other benefits.

The first laser was introduced by Maiman in

1960 (2), who used ruby to make laser. After a while, (Carbon Dioxide Laser) CO<sub>2</sub> and Neodymium-Doped Yttrium Aluminium Garnet (Nd: YAG) lasers were developed. In medical field, laser was first used for photocoagulation of retina in 1960 (3). Goldman used lasers in dentistry in 1964 for the first time (3). In 1989, Myers published the first article about using laser in periodontal surgery (3). However, in those years studies suggested that the laser devices used for incision and ablation of soft tissues were not suitable for dental hard tissues and finally Food and Drug Administration (FDA) allowed CO<sub>2</sub>, Nd: YAG, and diode lasers only for soft tissues (3). Today, there are different types of lasers available for using in dentistry: CO<sub>2</sub>, Nd: YAG, Holmium Yttrium Aluminium Garnet (Ho: YAG), (Erbium, Chromium doped Yttrium Scandium Gallium Garnet) Er,Cr: YSGG, Neodymium doped Yttrium Aluminum Perovskite (Nd: YAP), Gallium arsenide (GaAs) (diode), and Argon(4).

### Soft Tissue Surgical Applications of Lasers

In comparison with conventional scalpel, laser has many benefits, such as ease of soft tissue ablation, hemostasis (5), instant sterilization, reduced bacteremia, little wound contraction, reduced edema, minimal scar, reduced mechanical trauma, less operative and post-operative pain (6-8), increased patients' acceptance (6), no or few sutures, no need for topical anesthesia (9). Thus, different dental lasers are being widely used for gingival soft tissue procedures including gingivectomy, frenectomy, gingivoplasty, epulis, or benign tumor removal (5), gingival depigmentation, second stage exposure of dental implants, irradiation of aphthous ulcers, coagulation of free gingival graft donor sites (6), and soft tissue crown-lengthening (5). Vascular lesions, such as hemangioma, should be approached with caution. Incisional biopsies are not allowed, but smaller lesions, particularly those affecting the lip are best ablated with either laser or cryosurgery (10).

### Case Report

The patient presented here was a 57 year- old male who was completely edentulous, with a mandibular over denture based on 4 screw type

implants which were constructed by O'ball abutments. He was suffering from pain on chewing and a general discomfort, especially in the anterior segment. He could not use his prosthesis for the past three months, and was only able to wear it during mastication and in public. It was found that peri mucositis was present around the soft tissue of two implants inserted in right side; the area also showed bleeding on probing and tenderness (Figure 1a). The patient received a gingival augmentation surgery that was performed with free gingival graft obtained from keratinized palatal mucosa (Figure 1b). Searching in patient's file documented in our department showed that the result was not acceptable, and the procedure had totally failed to gain the sufficient vestibular depth. The colleagues working in prosthetic phase recommended another operation to create sufficient space for the next overdenture (Figure 1c).

Considering all aspects like his age, fear of surgery, hypersensitivity, need for fast healing to prepare the soft tissue as soon as possible, it was decided to perform vestibuloplasty with soft tissue laser (14). The laser wavelength was 810 nm and it was set in a continuous wave mode at a power output of 2.5 watt with a 0.3-mm diameter fiber tip (Doctor Smile Diode Laser, Italy). The tip was directed at an angle of 10 to 15 degrees to the tissue; and was applied continuously for 5 minutes till the approvable vestibular depth was achieved. There was no significant bleeding during, or immediately after the surgery (Figure 2).

The local anesthesia used before laser irradiation was minimal, and the patient's discomfort after surgery was limited and managed with mouthwash chlorhexidine. No additional analgesic or antibiotic was recommended. Suturing was done at the apical part of margin in order to prevent from muscular reattachment. We used periosteal penetration technique and sutures to reduce the muscle tension during the healing phase. In most clinical cases, sutures would not be used, because of excellent hemostasis achieved with dental lasers. The secondary wound closure was covered with sponge gauze soaked in tetracycline ointment. Two weeks later, a new overdenture was made and delivered to the patient. The patient was satisfied, and the retention of final prosthesis was great well due to deep vestibule.

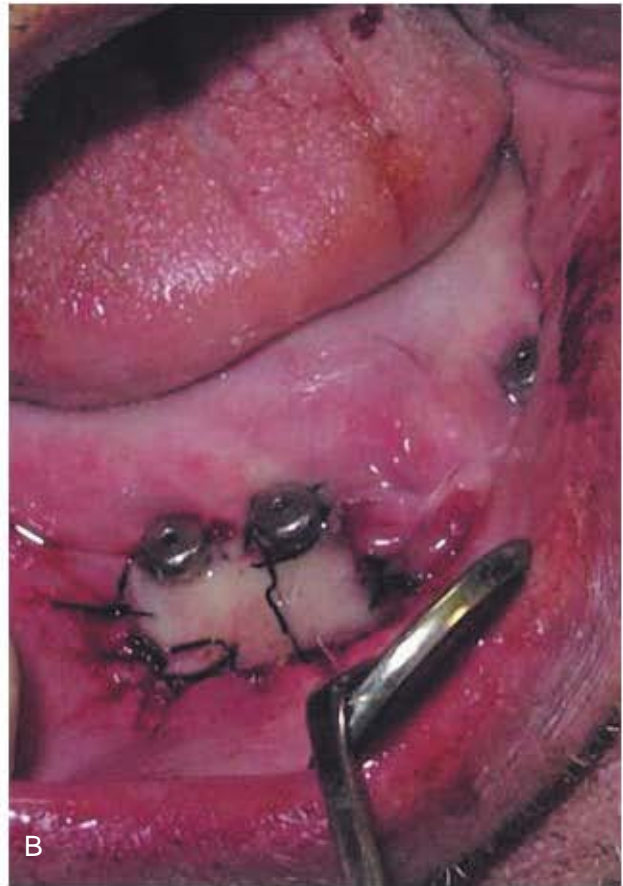
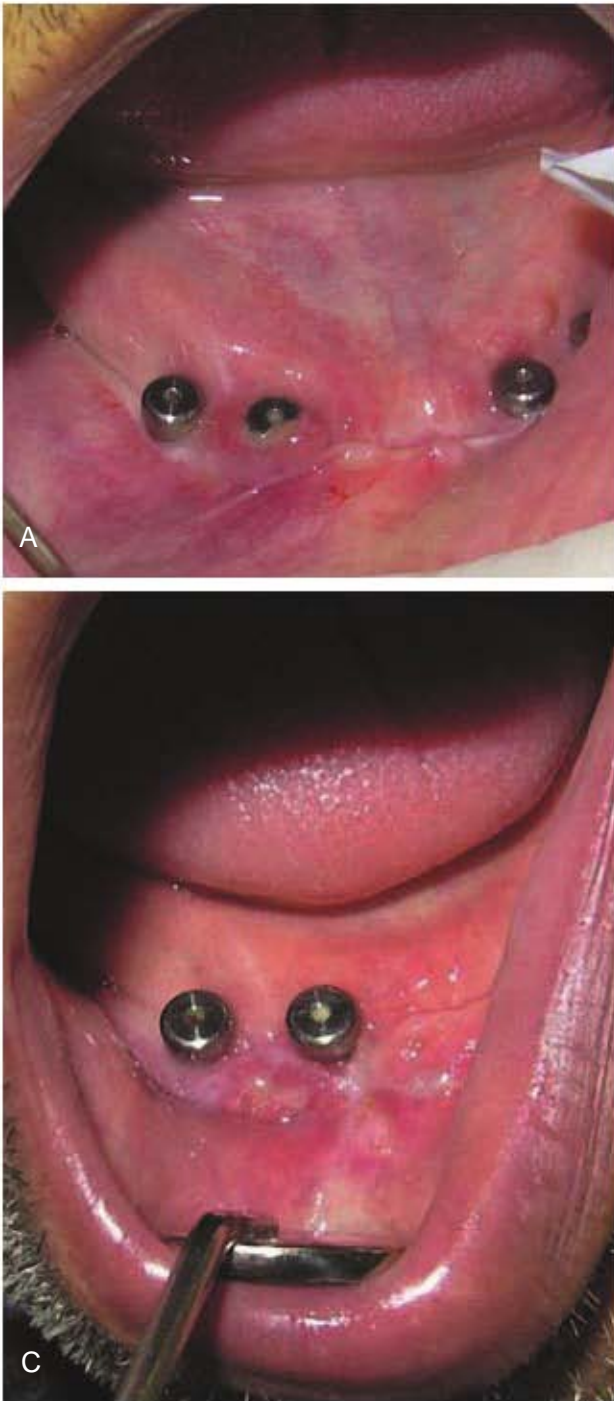
Figure 1. (A) Insufficient keratinized soft tissue and narrow vestibule around dental implants supporting an overdenture. Peri implant mucositis apparently exist. (B) Using free gingival graft to create some attached and keratinized soft tissue. (C) Early healing of soft tissue graft seems acceptable results. However, narrow vestibular depth made the prosthesis phase difficult.

## Discussion

Usages of lasers in periodontics include initial periodontal therapy, implant therapy, root surface modification, osseous surgery and soft tissue surgery (4). Need for creating a reasonable band of keratinized gingival/soft tissue around natural teeth/dental implants is not a rare condition in

clinics. In some cases like in the patient described here, conventional augmentation procedures cannot be efficient enough to solve the problem. Excessive vestibuloplasty alone, or in combination with gingival graft is recommended in order to prevent recurrent high muscle attachment. Narrow vestibular depth is one of the most complicated situations for successful gingival augmentation.

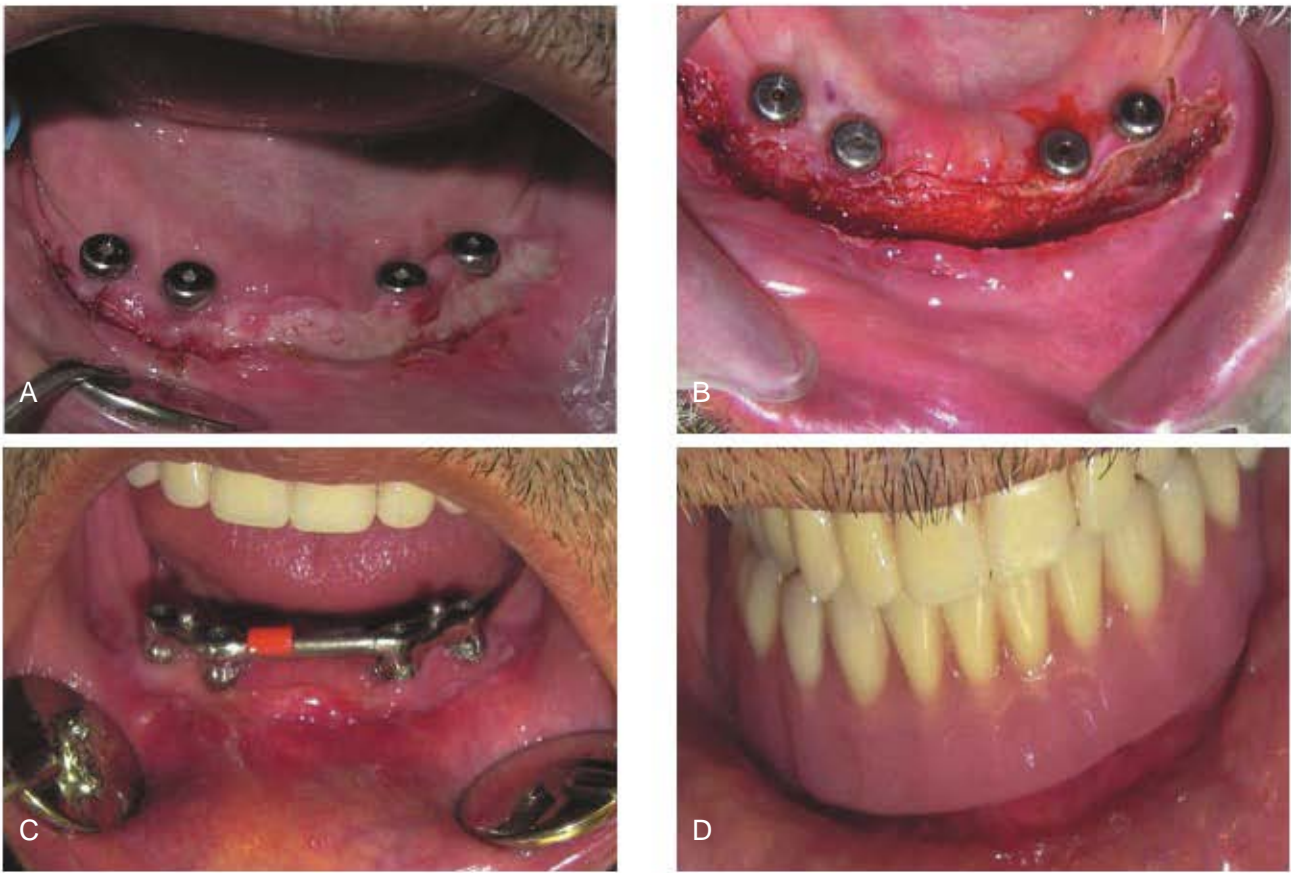


Figure 2. (A) Clinical situation exactly before second operation. (B) Laser-assisted vestibuloplasty using diode laser immediately after irradiation. Excellent hemostasis can be observed. (C) Healing of the tissue around dental implants two weeks later. (D) Final overdenture could be made in an easy way due to sufficient depth of vestibule in anterior segment.

Using dental lasers for vestibuloplasty has some clinical benefits during surgery like little bleeding with better access and less discomfort. Understanding of the mechanisms and different effects of routine dental lasers is necessary before clinical use. By striking the laser beam to a material, four results may occur for the laser beam: absorption, reflection, scattering, and transmission. When striking the laser beam to living tissues, the beam is absorbed unless the penetration is so deep. In that situation the beam will be scattered. Conceiving many factors, the absorbed energy can cause heating, coagulation and incision. These factors include emitted wavelength, power (Watts), wave form (i.e. continues or pulsed), pulse duration, energy per pulse, energy density, duration of exposure, peak power of pulse, angulation of energy delivery to the target surface, and optical properties of tissue (e.g. factors such as pigmentation, water content, mineral content, etc.). The energy absorption degree

of each tissue is specific, so the wavelength of the outcome laser beam should be designed for each tissue separately (3). A comprehensive review of available data in soft tissue surgery by different dental lasers is calculated in Table 1.

In brief, CO<sub>2</sub> laser was effective in achieving hemostasis by vessel coagulation. (34). Less wound contraction occurs, because the CO<sub>2</sub> laser does not remove the tissue collagen (8). Thus, the CO<sub>2</sub> laser is a useful instrument, which provides control of the surgical field, esthetic and functional results (35). For CO<sub>2</sub> laser, histological effects are related to the beam characteristics, rather than wavelength; greater damage has been observed with the use of the constant wave mode (1). The least risk of unwanted thermal damage can be achieved with very short pulses at the highest power density for the shortest time possible (11).

In the case presented here, we used laser beam around dental implants. Some clinicians have considerations for side effects of irradiation of

## Diode Laser for Oral Cavity Soft Tissue Incision

Table 1. Review of published data in using dental lasers for different kinds of soft tissue incisions.

Author/year	Method/clinical application	Laser type	Conclusion
1 Wilder-Smith et al 1995 (11)	Soft tissue incision (oral mucosa of pig's mandible)	CO <sub>2</sub>	Thermal and histologic results were related to parameters and beam characteristics rather than wavelength. Minimal edge coagulation artifact observed. minimal to no hemorrhage and re-epithelialization and collagenization were found to occur by day 7 in both laser and conventional groups.
2 RizoIU et al 1996 (12)	incision mucocutaneous soft tissues	Er,Cr:YSGG	
3 White et al 1998 (9)	Excision of oral mucosa lesions(leukoplakia,lichen planus, squamous papilloma, pyogenic granuloma,...)	CO <sub>2</sub> and Nd:YAG	Laser excision was well tolerated by patients, All patients healed post surgically with no loss of function, minimal postoperative pain, conservative site-specific minimally invasive surgeries, and elimination of need for sutures.
4 Goharkhay et al 1999 (1)	Soft tissue incision	Diode laser (810 nm/0.5-15 w/pulse rate of 2-32zone. Excellent coagulation ability, useful alternative msec/1.5-250 Hz)in soft-tissue surgery of the oral cavity.	
5 Neiburger et al 1999 (13)	gingival flap incisions	1.4 mw helium-neon (670 helium-neon diode lasers, at the mentioned energy nm) diode laser for 30level, increase the rate of gingival wound healing in seconds (fluence = 0.3469 percent of patients, without any side effects. J/cm <sup>2</sup> ).	
6 Wilcox et al 2001 (14)	Use of electrosurgery and lasers a unipolar electrosurgical unit should be in the presence of dentalunit, a bipolaravoided, while judicious use of both the bipolar unit implants (in vitro study)electrosurgical unit, and or the laser unit should produce temperature profiles Nd:YAG.well within clinical limits.		
7 Gontijo et al 2005 (15)	labial frenectomy in infant patients.	diode (810 nm) and Er:YAG	a combined technique is suggested: using the diode laser in soft tissues and the Er:YAG laser in periosteal bone tissues and for removal of final collagen fibers.
8 Haytac et al 2006 (16)	frenectomy	CO <sub>2</sub>	Compared with scalpel technique it shows less postoperative pain and fewer functional complications (speaking and chewing). required fewer analgesics. safe, effective, acceptable, and impressive alternative for frenectomy operations. No pain medication was required after surgery, wound healing was excellent and rapidly achieved. The oral pathology report confirmed the pre surgical clinical diagnosis.
9 Boj et al 2007 (17)	Squamous cell papilloma removal in the pediatric dental office.	Er,Cr:YSGG laser	
10 D'Arcangelo et al 2007 (18)	incisions in rat oral tissue	diode (808 nm)	Diode laser tends to produce more pronounced changes than conventional scalpel surgical procedure (due to tissue thermal damage), with corresponding greater inflammatory reaction and delay in tissue organization only at the initial stage. A successful case of a maxillary labial frenectomy in a pediatric patient .
11 Shetty et al 2008 (19)	Maxillary frenectomy in a pediatric patient.	CO <sub>2</sub>	the diode laser is undoubtedly a good alternative to conventional surgery. possibility of avoiding direct suture is surely helpful in aesthetic areas.
12 Capodiferro S et al 2008 (20)	excision of fibrolipoma of the lip	Diode	The wound healed excellently and rapidly without sutures. No relapse was observed a year after the surgery.
13 Boj et al 2009 (21)	Lower lip mucocele treatment	Er:YAG	Minimal damage to surrounding tissue.
14 Iseri et al 2009 (22)	epulis fissuratum and prosthetic rehabilitation in patients with vesiculobullous disease.	CO <sub>2</sub> Treatment of	
15 De Arruda Paes- Junior et al 2010 (23)	Treatment of epulis fissuratum	CO <sub>2</sub>	Good haemostasis, no infection, post-operative comfort, esthetic and functional aspects immediately reestablished.
16 Tuncer et al 2010 (24)	Intra oral soft tissue excisional biopsies	CO <sub>2</sub>	Minimal interoperative and postoperative complications , good pain control.

## Diode Laser for Oral Cavity Soft Tissue Incision

Table 1. (Continue)

Author/year	Method/clinical application	Laser type	Conclusion
17 Cercadillo-Ibarquren et al 2010 (25)	In vitro study on porcine oral mucosa	CO <sub>2</sub> (1w, 2w, 10w, 20w) Diode (2w, 5w, 10w) pulsed)-Er,Cr:YSGG (1w with & without water/air spray, )	The wavelength of each laser determines the absorption rate of every tissue and the thermal effect
18 Vescovi et al 2010 (26)	Hyperplastic fibroepithelial lesions excision. (buccal and mucosa)	Nd:YAG (3.5 w, 60 Hz) and Nd:YAG (5w, 30 Hz)	Better incision quality and less width of overall tissue injuries in use of higher frequency and lower power.
19 Jin et al 2010	Wound healing following mucosa	Diode laser (27) Er,Cr:YSGG laser	Diode laser is considered a good cutting device for oral mucosa.
Gomez-Santos et al 2010 (28)	Irradiation of different implant surfaces	CO <sub>2</sub> (4 W) and an ErCr:YSGG laser (1.5a W, pulsed mode)	The acid-etched and sandblasted surfaces were those most affected by the thermal changes.
20 De Oliveira-Guare et al 2010 (29)	Drug-induced gingival enlargement treatment (gingivectomy)	gallium-aluminum-arsenide (GaAlAs) diode laser	
21 Pedron et al 2010 (30)	Excision of mucocele of the lower lip.	high-intensity diode laser	A diode laser was used as an effective and safe method to remove the patient's overgrown gingival tissue in a two year follow up. rapid, bloodless, and well accepted by patients.
22			Postoperative problems, discomfort, and scarring were minimal. laser-aided procedures, when used at appropriate Er:YAG laser ( 100 mJ, 10 Hz); diode laser (808 laser settings, preserve the original morphology and chemical composition of cementum. nm, 1.2 W, continuous wave); and CO <sub>2</sub> laser (10.6 mm, 3 W). Er,Cr:YSGG laser minimized postoperative pain, and the time to prosthetic rehabilitation was also shortened. The esthetic results were far superior, and no complications were recorded.
23 Lee et al 2010 (31)	laser-aided circumferential supracrestal fiberotomy		
24 Arnabat-Dominguez et al 2010 (32)	second-stage implant surgery in patients with insufficient gingival attachment.		
25 Boj et al 2011 (33)	Crown lengthening, exposure of an unerupted molar, lingual and maxillary frenectomies,...	Er,Cr:YSGG laser	All cases healed satisfactorily and were followed up for 3 to 4 years.

implant surfaces. According to Arnabat-Dominguez et al application of Erbium, Chromium doped Yttrium Scandium Gallium Garnet (Er, Cr: YSGG) laser in the 2<sup>nd</sup> stage of implant surgery in patients, minimized postoperative pain, and the time to prosthetic rehabilitation was also shortened. The esthetic results were far superior, and no complications were recorded (32). When the Er, Cr: YSGG was used with a water spray, a decrease in temperature was observed in all implants. The acid-etched and sandblasted surfaces were those most affected by the thermal changes. Er, Cr: YSGG laser with a water spray applied to the sealing cap, or the coronal zone of the implants does not generate thermal increments in the apical surface capable of adversely affecting osseointegration and the integrity of the peri-implant bone tissue (28).

Cercadillo\_Ibarquren et al histologically evaluated the thermal damage produced in soft tissue by CO<sub>2</sub>, Er, Cr: YSGG and diode lasers and showed that the samples with lowest thermal

damage were those irradiated with Er, Cr: YSGG laser using water/air spray, followed by CO<sub>2</sub> and diode lasers (25). In addition, Vescovi et al showed that Nd: YAG laser induced serious thermal effects in small specimens (mean size < 7 mm) independently from the frequency and power employed. Better incision quality and less width of overall tissue injuries were observed in the use of higher frequency and lower power (26).

There are different findings about the healing process after using different dental lasers. Jin et al showed that CO<sub>2</sub> laser leads to less tissue damage than a scalpel or Er,Cr:YSGG laser. (27) D'Arcangelo et al. evaluated that diode laser at a power output of 6 W showed the worst results of tissue repair, especially after 7 days. On the contrary, the extent of epithelial damage lateral to the wound edge and the extent of collagen denaturation were near equal with scalpel incision and laser irradiation at 4 W after 14 days. There was a greater concentration of endothelial nitric

oxide synthase (eNOS) and inducible nitric oxide synthase (iNOS) after 7 days of laser surgical procedure. Diode laser tends to produce more pronounced changes than conventional scalpel surgical procedure (due to tissue thermal damage), with corresponding greater inflammatory reaction and delay in tissue organization only at the initial stage (18).

## Conclusion

Because of their rapid operations and regular wound healing without sutures, lasers apply a great technology and are useful for soft tissue surgery in modern dentistry. In spite of all these advantages of using lasers in soft tissue incisions, there are not enough data to support the theory of reducing the healing time using lasers. Cost and the site of the laser device may be the biggest obstacles for its routine application.

## Acknowledgments

The study was supported by a grant from the Dental Research Center, Shahid Beheshti University of Medical Sciences.

## Conflicts of Interest and Source of Funding:

none declared

## References

- Goharkhay K, Moritz A, Wilder-Smith P, Schoop U, Kluger W, Jakolitsch S, et al. Effects on oral soft tissue produced by a diode laser in vitro. *Lasers Surg Med.* 1999;25(5):401-6.
- Maiman TH. Stimulated optical radiation in ruby. *Nature.* 1960;187:493-4.
- Mahajan A. Lasers in periodontics-a review. *Eur J Dent Med.* 2011;3:1-11.
- Bains VK, Gupta S, Bains R. Lasers in periodontics: An Overview. *J Oral Health Community Dent.* 2010;4:29-34.
- Ishikawa I, Aoki A, Takasaki AA, Mizutani K, Sasaki KM, Izumi Y. Application of laser in periodontics: true innovation or myth? *Periodontol* 2000. 2009;50:90-126.
- Cobb CM. Lasers in periodontics:a review of the literature. *J Periodontol.* 2006;77(4):545-64.
- Wigdor HA, Walsh JT Jr, Featherstone JDB, Virsuri SR, Fried D, Waldvogel JL. Lasers in dentistry. *Lasers Surg Med.* 1995;16(2):103-33.
- Luomanen M, Meurman JH, Lehto VP. Extracellular matrix in healing CO<sub>2</sub> laser incision wound. *J Oral Pathol.* 1987;16(6):322-31.
- White JM, Goodis HE, Rose CL. Use of pulsed Nd:YAG laser for intraoral soft tissue surgery. *Lasers Surg Med.* 1991;11(5):455-61.
- Oliver RJ, Sloan P, Pemberton MN. Oral Biopsies: methods and applications. *Br Dent J.* 2004; 196(6):329-33.
- Wilder-Smith P, Arrastia AM, Liaw LH, Berns M. Incision properties and thermal effects of three CO<sub>2</sub> lasers in soft tissue. *Oral Surg Oral Med Oral Pathol Oral Radiol Endod.* 1995;79(6):685-91.
- Rizoiu IM, Eversole LR, Kimmel AI. Effects of an erbium, chromium: yttrium, scandium, gallium, garnet laser on mucocutaneous soft tissues. *Oral Surg Oral Med Oral Pathol Oral Radiol Endod.* 1996;82(4):386-95.
- Neiburger EJ. Rapid healing of gingival incisions by the helium-neon diode laser. *J Mass Dent Soc.* 1999;48(1):8-13, 40.
- Wilcox CW, Wilwerding TM, Watson P, Morris JT. Use of electrosurgery and lasers in the presence of dental implants. *Int J Oral Maxillofac Implants.* 2001;16(4):578-82.
- Gontijo I, Navarro RS, Haypek P, Ciamponi AL, Haddad AE. The applications of diode and Er:YAG lasers in labial frenectomy in infant patients. *J Dent Child (Chic).* 2005;72(1):10-5.
- Haytac MC, Ozcelik O. Evaluation of patient perceptions after frenectomy operations: a comparison of carbon dioxide laser and scalpel techniques. *J Periodontol.* 2006;77(11):1815-9.
- Boj JR, Hernandez M, Espasa E, Poirier C. Laser treatment of an oral papilloma in the pediatric dental office: a case report. *Quintessence Int.* 2007;38(4):307-12.
- D'Arcangelo C, Di Nardo Di Maio F, Prospero GD, Conte E, Baldi M, Caputi S. A preliminary study of healing of diode laser versus scalpel incisions in rat oral tissue: a comparison of clinical, histological, and immunohistochemical results. *Oral Surg Oral Med Oral Pathol Oral Radiol Endod.* 2007;103(6):764-73.
- Shetty K, Trajtenberg C, Patel C, Streckfus C. Maxillary frenectomy using a carbon dioxide laser in a pediatric patient: a case report. *Gen Dent.* 2008;56(1):60-3.
- Capodiferro S, Maiorano E, Scarpelli F, Favia G. Fibrolipoma of the lip treated by diode laser surgery: a case report. *J Med Case Reports.* 2008;2:301.
- Boj JR, Poirier C, Espasa E, Hernandez M, Espanya A. Lower lip mucocele treated with an erbium laser. *Pediatr Dent.* 2009;31(3):249-52.
- Işeri U, Özçakir-Tomruk C, Gürsoy-Mert H. Treatment of epulis fissuratum with CO<sub>2</sub> laser and prosthetic rehabilitation in patients with vesiculobullous disease. *Photomed Laser Surg.* 2009;27(4):675-81.
- de Arruda Paes-Junior TJ, Cavalcanti SC, Nascimento DF, Saavedra Gde S, Kimpara ET, Borges AL, et al. CO<sub>2</sub> laser surgery and prosthetic management for the treatment

- of epulis fissuratum. *ISRN Dent.* 2011;2011:282361.
24. Tuncer I, Ozçakir-Tomruk C, Sencift K, Cöloğlu S. Comparison of conventional surgery and CO2 laser on intraoral soft tissue pathologies and evaluation of the collateral thermal damage. *Photomed Laser Surg.* 2010;28(1):75-9.
25. Cercadillo-Ibarguren I, Espana Tost A, Arnabat-Dominguez J, Valmaseda-Castellon E, Berini-Aytes L, Gay-Escoda C. Histologic evaluation of thermal damage produced on soft tissues by CO2, Er,Cr: YSGG and diode lasers. *Med Oral Patol Oral Cir Bucal.* 2010;15(6):912-8.
26. Vescovi P, Corcione L, Meleti M, Merigo E, Fornaini C, Manfredi M, et al. Nd:YAG laser versus traditional scalpel. A preliminary histological analysis of specimens from the human oral mucosa. *Lasers Med Sci.* 2010;25(5):685-91.
27. Jin JY, Lee SH, Yoon HJ. A comparative study of wound healing following incision with a scalpel, diode laser or Er,Cr:YSGG laser in guinea pig oral mucosa: A histological and immunohistochemical analysis. *Acta Odontol Scand.* 2010;68(4):232-8.
28. Gómez-Santos L, Arnabat-Domínguez J, Sierra-Rebolledo A, Gay-Escoda C. Thermal increment due to ErCr:YSGG and CO2 laser irradiation of different implant surfaces. A pilot study. *Med Oral Patol Oral Cir Bucal.* 2010;15(5):e782-7.
29. De Oliveira Guaré R, Costa SC, Baeder F, de Souza Merli LA, Dos Santos MT. Drug-induced gingival enlargement: biofilm control and surgical therapy with gallium-aluminum-arsenide (GaAlAs) diode laser-A 2-year follow-up. *Spec Care Dentist.* 2010;30(2):46-52.
30. Pedron IG, Galletta VC, Azevedo LH, Corrêa L. Treatment of mucocele of the lower lip with diode laser in pediatric patients: presentation of 2 clinical cases. *Pediatr Dent.* 2010;32(7):539-41.
31. Lee JW, Park KH, Chung JH, Kim SJ. Effects of laser-aided circumferential supracrestal fiberotomy on root surfaces. *Angle Orthod.* 2011;81(6):1021-7.
32. Arnabat-Domínguez J, Bragado-Novell M, España-Tost AJ, Berini-Aytés L, Gay-Escoda C. Advantages and esthetic results of erbium, chromium:yttrium-scandium-gallium-garnet laser application in second-stage implant surgery in patients with insufficient gingival attachment: a report of three cases. *Lasers Med Sci.* 2010;25(3):459-64.
33. Boj JR, Poirier C, Hernandez M, Espassa E, Espanya A. Case series: laser treatments for soft tissue problems in children. *Eur Arch Paediatr Dent.* 2011;12(2):113-7.
34. Kardos TB, Holt T, Ferguson MM. Histological evaluation of the effect of a miniature CO2 laser on oral mucosa. *Int J Oral Maxillofac surg.* 1989;18(2):117-20.
35. Niccoli-Filho W, Murilo-Santos L, Schubert M, Morosolli AC. Treatment of developmental defect of upper lip with CO2 laser radiation: First surgical time. *J Cosmet Laser Ther.* 2005;7(2):97-100.