

## An Achondroplastic Case with Foramen Magnum Stenosis, Hydrocephaly, Cortical Atrophy, Respiratory Failure and Sympathetic Dysfunction

Mustafa Ozcetin<sup>1</sup>, MD; Mehmet Tayip Arslan<sup>2</sup>, MD, and Bulent Karapinar<sup>2</sup>

1. Department of Pediatrics, Faculty of Medicine, Zonguldak Karaelmas University, Zonguldak, Turkey
2. Department of Pediatrics, Ege University Faculty of Medicine, Izmir, Turkey

Received: Jan 01, 2011; Final Revision: Mar 17, 2011; Accepted: Apr 04, 2011

### Abstract

**Background:** Achondroplasia is a relatively frequent genetic disorder that may lead to limb weakness, motor-mental retardation, hydrocephaly, and respiratory disorders. In this pathology, foramen magnum stenosis and accompanying disorders like respiratory depression is well documented.

**Case Presentation:** A 2.5 year-old child with the diagnosis of achondroplasia admitted to our clinic with severe respiratory depression, limb weakness, and motor mental retardation as well as sympathetic dysfunction. In radiologic evaluations, severe foramen magnum stenosis was detected. The patient was operated and posterior fossa decompression was accomplished to prevent compression of respiratory centers and neurons.

**Conclusion:** This case is unique with the narrowest foramen magnum reported up to date and the sympathetic dysfunction which is not reported as a complication in achondroplastic patients. The authors review the relevant literature, focusing on the indications for cervicomedullary decompression in infants with achondroplasia.

*Iranian Journal of Pediatrics, Volume 21 (Number 1), March 2012, Pages: 121-124*

**Key Words:** Achondroplasia; Foramen Magnum; Respiratory Depression; Sympathetic Dysfunction

### Introduction

Achondroplasia is a rather common type of osteochondrodysplasia that is characterized by short-limbed dwarfism, craniofacial deformities, such as macrocephaly, frontal bossing, midface hypoplasia and a depressed nasal bridge, a protuberant abdomen, increased pelvic tilt, rhisomelia, and trident hand. It is inherited in an autosomal dominant fashion and affects more than

250 000 individuals worldwide [1]. In this disorder the main problem is defective enchondral growth. Due to this pathology, disturbance of enchondral ossification may lead to lethal complications like foramen magnum stenosis, vertebral canal stenosis, jugular foramen stenosis, and odontoid process defects in 35-50% of achondroplastic patients if not diagnosed and treated early. These conditions which can cause respiratory disorders, weakness of limbs, myelopathy, syringobulbia,

\* Corresponding Author;

Address: Zonguldak Karaelmas University Faculty of Medicine, Department of Pediatrics, Zonguldak/Turkey

E-mail: mozcetin@gmail.com

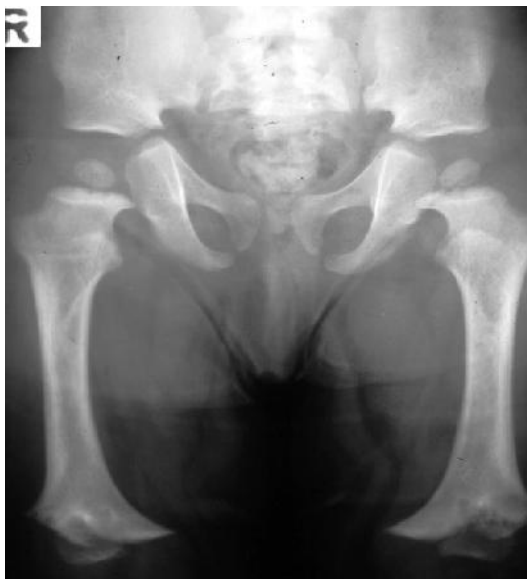© 2012 by Pediatrics Center of Excellence, Children's Medical Center, Tehran University of Medical Sciences, All rights reserved.

syringo-myelia, hydrocephalus; death usually takes place between third and fourth decade<sup>[1]</sup>. Foramen magnum stenosis in achondroplastic patients causes respiratory depression and increased sudden infant death rate due to compression of vital centers<sup>[2]</sup>. In this report, an achondroplastic patient with respiratory failure, extensive foramen magnum stenosis, hydrocephaly, cortical atrophy and sympathetic dysfunction who required very long mechanical ventilation due to late recognition, is presented with relevant literature.

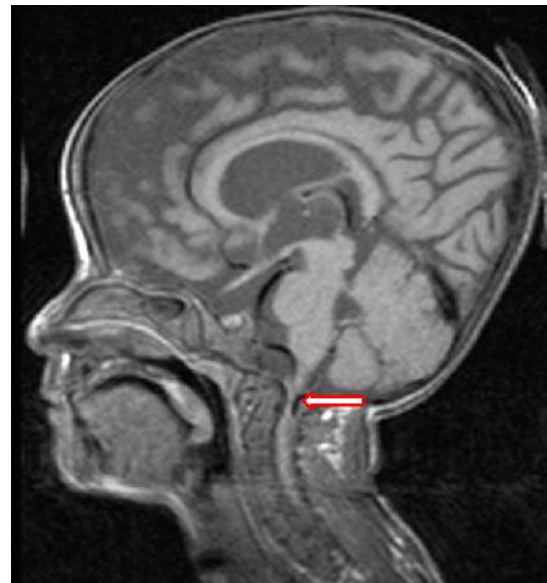
### Case Presentation

A 2.5 year old female child was referred to our clinic due to inability to wean the patient from mechanical ventilation. Past medical history revealed that her developmental mile stones were retarded relative to her peers until she developed pulmonary infection at 2 years of age and then had downhill course over 6 months despite vigorous antibiotic treatment. On physical examination, craniofacially the head appeared large with frontal bossing, but with midfacial hypoplasia. The patient was an alert girl with dysmorphic features

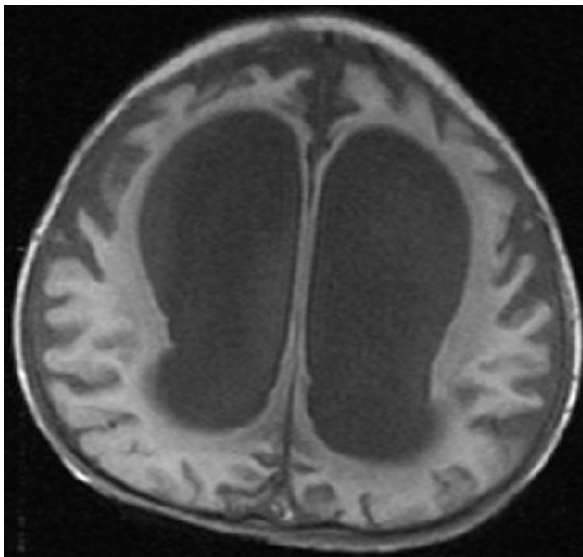
characteristic of achondroplasia, including short-limbed skeletal dysplasia (Fig 1). The hands were short and broad with fingers exhibiting a three pronged (trident) appearance. The patient was 6 kg (<3p) and 61 cm (<3p) at admission according to achondroplastic percentiles. She was unable to tolerate spontaneous respiration. The results of full blood analysis, erythrocyte sedimentation rate and C-reactive protein were within normal ranges. Moreover, there were no laboratory data suggestive of endocrinopathies, hypophosphatasia and/or hypercalcemia. Cranial MRI revealed extensive foramen magnum stenosis which is known to cause respiratory disorders through compression of respiratory centers and neurons (Fig 2) as well as hydrocephalus and cortical atrophy (Fig 3). The patient was operated at the neurosurgical department of our hospital and posterior fossa decompression was accomplished. The hydrocephaly was not resolved after decompressive surgery and necessitated placement of ventriculoperitoneal shunt. However the patient needed mechanical ventilation for more than 8 months after operation with several attempts to free the patient of the ventilator. During postoperative follow up period she had also hypotension and bradycardia attacks which suggested sympathetic nervous system dysfunction, and needed dopamin infusions



**Fig. 1:** Short-limbed skeletal dysplasia (The ilia are square and small, femora are broad for their length)



**Fig. 2:** Saggital Cranial MR of the patient demonstrating very severe foramen magnum stenosis of 5 mm diameter



**Fig. 3:** Transverse Cranial MRI of the patient demonstrating hydrocephalus

ranging between 5-15 micgr/kg/min for 1-2 days for each attack. She also experienced several attacks of mechanical ventilation induced pneumonia and required vigorous and prolonged antibiotherapy. In spite of intensive treatment, both neurologic and respiratory problems were increased and the case was lost 8 months later.

## Discussion

Achondroplasia is the most common form of congenital bony dysplasia and it is known to cause many neurological symptoms including cervicomedullary compression, sleep disorders, spinal cord infarction and nerve root compression. The genetic defect in achondroplasia reduces the number of functional fibroblast growth factor receptor-3 (FGFR-3) which interferes with chondrocyte division [3,4]. This in turn leads to defective enchondral growth while the periosteal growth is normal. The pathogenesis of the distorted growth of the foramen magnum in achondroplasia has primarily been attributed to 2 factors. The first is a defect in endochondral ossification in the basiocciput that may result in an

anterior extension of squamous occipital bone. The second factor is an abnormal placement and premature fusion of the posterior synchondroses [5].

Neurological manifestations of this disorder, which occur in 35-47% of patients [6], include hypotonia, macrocrania with or without hydrocephalus, psychomotor delay, apnea, sleep disorders, multisegmented compressive spinal syndromes, and foramen magnum stenosis [5]. Most infants die as a result of respiratory disturbance, including upper airway obstruction, chest deformity, and compression of the cervicomedullary junction. Respiratory disorders which are seen in 85% of achondroplastic patients are mainly due to compression on respiratory center, obstructive sleep apnea, small and poorly developed paranasal sinuses, small thoracic chest, obstructive apnea, and severe hypotonia [6]. Compression of respiratory centers by the narrow foramen magnum is a possible explanation for respiratory disturbance in our patient because the patient gradually tolerated spontaneous respiration after the decompressive operation. The long course of the disease may be related with the severity of the stenosis. The early recognition of these well known complications is quite important to prevent long term disabilities and sequels. In present case, late recognition of foramen magnum stenosis, which is a known complication of achondroplasia, posed the patient to prolonged mechanical ventilation and to its risks, like ventilator induced pneumonia and interstitial lung disease. The second reason for the respiratory failure may be upper airway obstruction. Although this condition may have contributed to the respiratory disorder, the failure of recovery of spontaneous respiration after tracheostomy suggests that its role in respiratory failure is of minor one.

Achondroplasia is also characterized by central nervous system defects including compression at the cervicomedullary junction and hydrocephalus, and respiratory disorders including central apnea, obstructive apnea, and restrictive lung disease [1]. To our knowledge, the sympathetic dysfunction in achondroplastic patients due to foramen magnum or vertebral canal stenosis has not been reported in the literature. The transverse width of foramen magnum in our patient was 5 mm which is far

below the mean transverse width of achondroplastic patients which is 17.9 mm for the same age group<sup>[7]</sup>. Hypotension may be seen during bacteremia due to inflammatory response of the body. However, the hypotension and accompanying bradycardia seen in this patient lasted approximately 4.5 months necessitating intermittent positive inotropic support by dopamin infusions, and we observed severe hypotensive attacks in the absence of underlying septic condition. We could explain these attacks with sympathetic system failure secondary to severe compression by the narrow foramen magnum. Besides, the late remission of these hypotensive/bradycardic attacks is also related with the severity of the stenosis. The patient was 2 years 6 months of age at admission and she was not able to speak or walk. This may be due to the accompanying hydrocephaly and cortical atrophy which is seen in approximately 81% of achondroplastic patients. Besides, there are reports revealing increased mental retardation in achondroplastic patients with an incidence of 10-22% with intelligent quotient below 80<sup>[6]</sup>.

Cervicomedullary compression is both a common and potentially devastating occurrence in achondroplasia. The ensuing cervico-medullary compression is associated with severe morbidity and even sudden death, especially in infants 4 years of age or younger<sup>[5]</sup>. Defective skull-based endochondral bone formation in these children results in a narrow abnormally shaped foramen magnum, a shallow posterior fossa, and possible ventriculomegaly<sup>[5,8]</sup>. The management of cervicomedullary compression remains controversial<sup>[9]</sup>, in particular whether prophylactic decompressive surgery is warranted<sup>[5]</sup> or whether surgical intervention should be reserved for severe or symptomatic compression<sup>[10]</sup>. For treatment, ventriculo-peritoneal shunt, foramen magnum decompression, or venous decompression at the jugular foramen have been performed for hydrocephalus<sup>[5]</sup>. In the present case, although posterior fossa decompression was accomplished, the hydrocephaly was not resolved after decompressive surgery and necessitated placement of ventriculoperitoneal shunt. Similar results have been reported in many studies<sup>[5,9,10]</sup>.

## Conclusion

As a result, our patient showed the typical findings of achondroplasia like foramen magnum stenosis, respiratory failure, mental-motor retardation and hydrocephaly beside hypotension and bradycardia which seem to be new complications probably due to very severe stenosis of foramen magnum and compression of vital structures. The need for a multidisciplinary team approach involving pediatric neurosurgeons, pediatric neurologists, pediatricians, pulmonologists, geneticists, and neuroradiologists cannot be overemphasized.

## References

1. Horton WA, Hall JG, Hecht JT. Achondroplasia. *Lancet* 2007; 370(9582):162-72.
2. Freimon AS, Garg BP, Kalsbeck J. Apnea as a sole manifestation in achondroplasia. *J Pediatr* 1984; 104(3):398-401.
3. Francomano CA, Le PL, Pyeritz RE. Molecular genetic studies in achondroplasia. *Basic Life Sci* 1988;48:53-8.
4. Horton WA, Hood OJ, Machado MA, et al. Growth plate cartilage studies in achondroplasia. *Basic Life Sci* 1988;48:81-9.
5. Bagley CA, Pindrik JA, Bookland MJ, et al. Cervicomedullary decompression for foramen magnum stenosis in achondroplasia. *J Neurosurg* 2006;104(3 suppl):166-72.
6. Ruiz-Garcia M, Tovar-Baudin A, Del Castillo-Ruiz V, et al. Early detection of neurological manifestations in achondroplasia. *Childs Nerv Syst* 1997;13(4):208-13.
7. Brühl K, Stoeter P, Wietek B, et al. Cerebral spinal fluid flow, venous drainage and spinal cord compression in achondroplastic children: impact of Magnetic Resonance findings for decompressive surgery at cranio-cervical junction. *Eur J Pediatr* 2001;160(1):10-20.
8. Pauli RM, Horton VK, Glinski LP, et al. Prospective assessment of risks for cervicomedullary-junction compression in infants with achondroplasia. *Am J Hum Genet* 1995;56(3): 732-44.
9. Ho NC, Guarnieri M, Brant LJ, et al. Living with achondroplasia: quality of life evaluation following cervico-medullary decompression. *Am J Med Genet A* 2004; 131(2):163-7.
10. Keiper GL Jr, Koch B, Crone KR. Achondroplasia and cervicomedullary compression: prospective evaluation and surgical treatment. *Pediatr Neurosurg* 1999;31(2):78-83.