

## Significant Weight Loss May Delay or Eliminate the Need for Total Knee Replacement

Jeffrey H. DeClaire<sup>1,2,3,4</sup>, Tatjana T. Savich<sup>5</sup>, B. S. Adrienne LeGasse Montgomery<sup>6</sup>, Olayinka K. Warritay<sup>4</sup>

<sup>1</sup>Department of Surgery, Crittenton Hospital Medical Center, Rochester Hills, MI 48307, USA,

<sup>2</sup>Department of Orthopaedic Surgery, Crittenton Hospital Medical Center, Rochester Hills, MI 48307, USA,

<sup>3</sup>Oakland University School of Medicine, Rochester Hills, MI 48307, USA, <sup>4</sup>Department of Surgery, School of Medicine, The DeClaire Knee and Orthopaedic Institute, Rochester Hills, MI 48307, USA,

<sup>5</sup>Department of Health Care Sciences, Wayne State University College of Pharmacy and Health Sciences, CEO The DeClaire Knee and Orthopaedic Institute, Rochester Hills, MI 48307, USA, <sup>6</sup>Movestrong, Rochester Hills, MI 48307, USA

### Correspondence to:

Jeffrey H. DeClaire,  
DeClaire LaMacchia Orthopaedic Institute,  
1135 West University Drive, Rochester  
Hills, Michigan 48307, USA.  
E-mail: jhdeclaire@dl-ortho.com

**Date of Submission:** Jan 08, 2013

**Date of Acceptance:** Feb 20, 2014

**How to cite this article:** DeClaire JH, Savich TT, Montgomery BSAL, Warritay OK. Significant weight loss may delay or eliminate the need for total knee replacement. *Int J Prev Med* 2014;5:648-52.

### ABSTRACT

A 48-year-old morbidly obese woman with a left medial meniscal tear and moderately severe degenerative joint disease (DJD) reported for 14-month follow-up visit from arthroscopic surgery. She reported a resolution of pain, swelling and an improved range of motion (ROM). The patient was first evaluated 14 months ago, and at that time was considered a strong candidate for total knee replacement due to her limited (ROM), knee pain, swelling and functional impairment. At a 3 month visit prior to her initial evaluation the patient voluntarily enrolled in a nutritional and exercise program overseen by a licensed personal trainer and kinesiologist. At her final evaluation 14 months later, it was noted that in addition to her improved knee symptoms, the patient lost 15% of her initial bodyweight and exhibited significant gains in quadriceps strength. Her clinical exam and imaging suggested an arrest of progression of her joint disease. It was decided mutually by the patient and physician that she was no longer a candidate for total knee replacement surgery. Although the association between her weight loss and her knee DJD can only be hypothesized, this case report may highlight the need to discuss weight loss as an alternative treatment modality for end stage DJD.

**Keywords:** Degenerative joint disease, knee arthroplasty, obesity

### INTRODUCTION

Knee degenerative joint disease (DJD) is one of the more common disabilities in the older adult population of the United States.<sup>[1]</sup> There are several medical protocols that offer relief to patients.<sup>[2]</sup> An important component of several of these protocols is weight reduction.<sup>[3]</sup> This is especially indicated when managing overweight patients (body mass index [BMI] >24). Some of the described benefits of weight loss in these populations include; reduction in pain, increased range of motion (ROM) and an improvement in stability. It is unclear how sustained these benefits are and whether or not then can arrest progression of disease.<sup>[4]</sup> In severe disease, especially, knee arthroplasty surgery may ultimately provide the most definitive solution.<sup>[2]</sup>

Several studies have quantified the correlation between joint loads and units of lost body weight.<sup>[5]</sup> Furthermore, this

reduction has been correlated to improved pain and movement. Current estimates indicate that there needs to be at least 10% a weight reduction to demonstrate clinically significant effects on pain and disability.<sup>[4]</sup> The literature is, however, relatively deficient in studies that describe how these improved knee outcomes delay or eliminate the need for knee replacement. This case study will describe a unique case to illustrate the role of weight loss in alleviating the need for surgery in a middle-aged woman that exhibited several significant risk factors for total knee replacement upon initial evaluation with the surgeon.

## CASE REPORT

The patient's medical exam was reviewed and compared to her previous exam when TKA was presented as an option. In addition the patient's medical record and weight loss progress were also evaluated. The following information was abstracted for discussion; weight loss, percentage weight loss, BMI, waist circumference, and submax leg lift (proxy measure for quad strength).

### Most recent patient exam

- Chief complaint
- Left knee pain.

### History of present illness

A 46-year-old Caucasian woman with improved left knee pain secondary to morbid obesity and DJD presents for a recheck for her right and left knee. She was told at her last office visit 6 months ago that she was a candidate for total knee replacement to the left knee. The patient had arthroscopic surgery on her left knee 14 months ago. The patient presented with no new symptoms and is taking no medications related to her knees. The patient was participating in a weight loss program and has made tremendous improvements. The patient had no other concerns at this time.

### Past medical history

- Depression.

### Past surgical history

- Hysterectomy
- Abdominal hernia repair
- Bilateral knee arthroscopy: Right knee; meniscal repair, left knee; meniscal repair
- Podiatry surgery.

### Family history

- Heart disease.

### Social history

A 46-year-old school married paraeducator. She is a previous smoker, social drinker, and denies illicit drug use.

### Medications

Prozac, multivitamins, fish oil, calcium, Motrin.

### Allergies

No known drug allergies.

No contributing symptoms or complaints.

### Physical exam

- ROM bilateral: 0-126
- Effusion: 0.

Meniscal exam reveals no tenderness over the medial or lateral joint line. There is no pain on flexion and rotation. McMurray sign is negative.

Ligament exam revealed a negative Lachman with no pivot shift. There was no varus or valgus laxity at 0° and 30° of flexion. Posterior drawer and Godfrey sign are negative. There was no posterior sign. There is no posterolateral or posteromedial laxity with posterior, external, and internal rotation.

Patella exam revealed no crepitus with flexion-extension. There was a two quadrant glide with medial/lateral mobility. There was no medial or lateral retinacular tenderness. There is no tenderness of the patellar or quadriceps tendons. Extensor mechanism is intact with no leg lag.

### X-ray results

Four views of the knee were performed including a standing anteroposterior, standing flexion 45 posteroanterior [Figure 1], lateral, and sunrise views of the knee were performed.

### Findings

There was moderate-severe degenerative arthritis involving the medial tibiofemoral joint space. There was associated varus alignment. There was severe narrowing of the patellofemoral joint space.

Alignment: Right: Two varus, left: Varus.

### Impression

Moderate-severe degenerative arthritis of the medial tibiofemoral joint space. Varus alignment. There was severe degenerative arthritis of the patellofemoral joint space. Osteophyte formation superior and inferior pole of patella.

### Assessment/plan

A 46-year-old Caucasian woman with left knee DJD and medial meniscus tear. Non-operative treatment options for osteoarthritis were reviewed

with the patient. Treatment options discussed include: Tylenol, oral and topical anti-inflammatories, hyaluronic acid and cortisone injections, activity modification, maintaining strength, and flexibility.

## RESULTS

Fourteen months ago a patient came to our private practice for left knee pain and instability. In addition to surgery for the meniscal tear weight loss was recommended. Three months into her weight loss program and 2 months post-operative from arthroscopic medial meniscal repair surgery, our patient reported the following as shown in Table 1. The patient 14 months later was brought in for a recheck and reported the findings seen in Table 1. The patient reported a significant improvement in knee pain, swelling and ROM.

The patient began an intense weight loss program that involved diet and exercise. The patient reported the following trends [Table 2 and Charts 1-6] over an 18 month course. The patient appeared to plateau with regards to weight, BMI and waist circumference. The patient however continued to improve with regards to her leg submax measurements, which were used as a proxy measure of her quad strength.

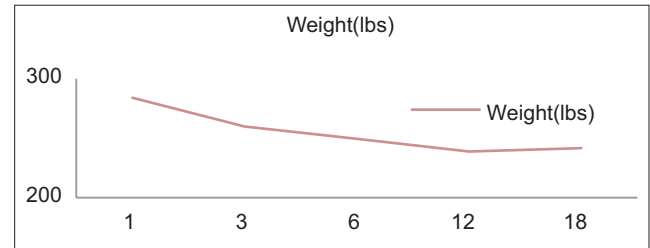
## DISCUSSION

The following are described risk factors for

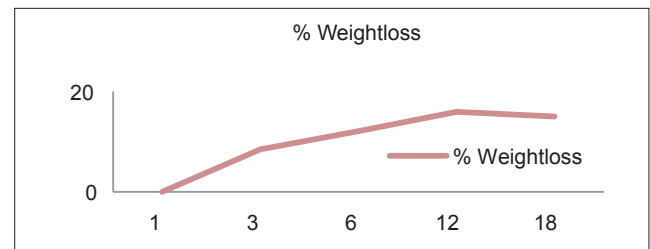
**Table 1:** Summary of clinical findings

Evaluation	Range of motion	Alignment	Clinical findings summary
Initial evaluation	120	Varus	Moderate-severe degenerative joint disease with restricted extension and associated pain and swelling
Final evaluation+ 14 months	126	Varus	Similar moderate-severe degenerative joint disease with decreased swelling decreased pain and increased range of motion. Alignment has remained varus

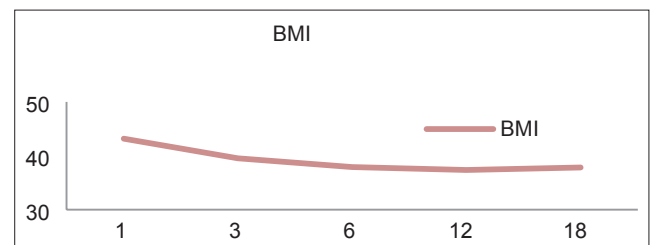
knee osteoarthritis; female gender, inflammatory joint disease, no history of osteoporosis, obesity, an occupation with repetitive knee bending, older age and previous knee injury (e.g., a meniscal tear).<sup>[2]</sup> Our patient demonstrated all of the above risk factors except for inflammatory joint disease. She had two modifiable risk factors; obesity and occupation. Our intervention was focused on weight loss and accessory muscle strengthening to eliminate the need for surgery. Modifying this one



**Chart 1:** Weight



**Chart 2:** Percentage weight loss

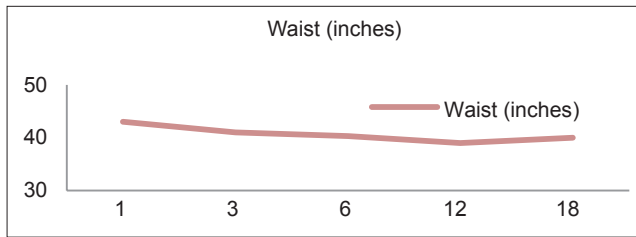


**Chart 3:** Body mass index

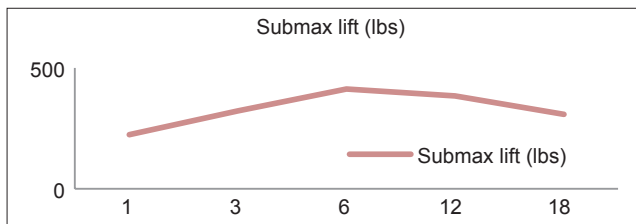
**Table 2:** Summary of weight loss findings

Time (months)	Weight (lbs)	Weight loss (%)	BMI	Waist (inches)	Submax leg lift (lbs)	Submax leg lift ratio to weight
1	284	0	43.2	43	223	0.78
3	259.8	8.5	39.5	41	322	1.24
6	249.5	12.1	37.9	40.3	412	1.65
12	238.8	15.9	37.4	39	383	1.61
18	241.5	15	37.8	40	411	1.7

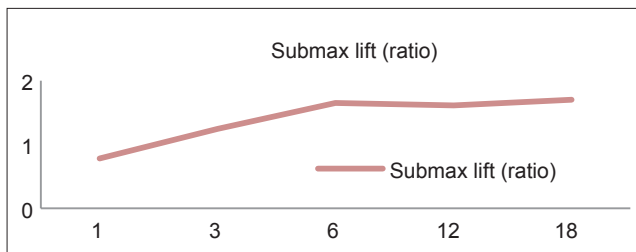
BMI=Body mass index



**Chart 4:** Waist circumference



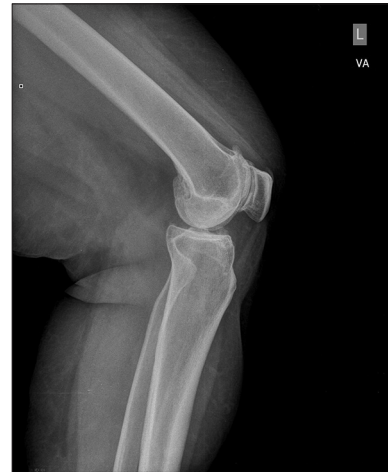**Chart 5:** Submax leg lift (lbs)



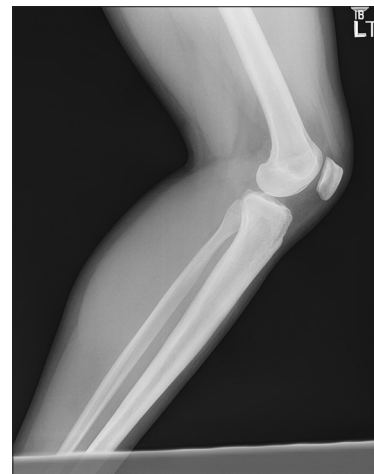**Chart 6:** Submax leg lift ratio

risk factor (15% weight loss) resulted in the patient deferring total knee replacement. It is unclear how weight loss improved her symptoms. Current theories suggest that the reduction in joint load that accompanies weight loss may play a significant role. These theories do not account for symptoms attributable to the anatomical features of end stage osteoarthritis. Her X-rays did not demonstrate any anatomical changes from previous films. This may suggest an arrest in progression of joint degeneration [Figure 2: Normal X-rays, Figures 1-3: Severe disease X-rays].

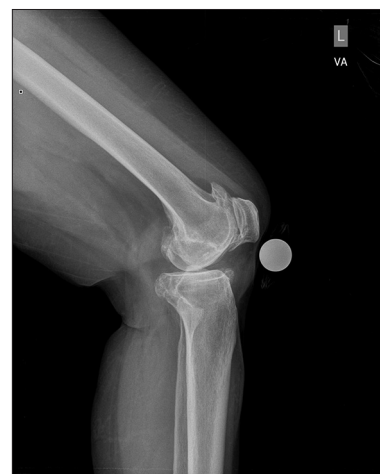There are several indications for total knee replacement. Providers often identify surgical candidates with end stage osteoarthritis and significant functional impairment. Poor ROM and impaired activity of daily living scores are established predictors of total knee replacement.<sup>[6]</sup> It is unclear if an improvement in functional outcomes correlates with anatomic changes. There is, however, evidence that patients with higher functional scores often defer surgery. In our patient, we found an improved ROM



**Figure 1:** Patient left leg with moderate degenerative joint disease



**Figure 2:** Normal Left leg with no degenerative joint disease



**Figure 3:** Left leg with severe degenerative joint disease

and a resolution of swelling and pain. These improvements in addition to our patient reporting

an overall sense of “feeling better” resulted in our patient delaying surgical intervention.

In addition to weight loss, our patient demonstrated progressive quadriceps strengthening. Poor quad strength has been associated with the development and progression of DJD of the knee. Studies suggest that quadriceps weakness is a strong predictor of functional limitations in patients with knee osteoarthritis.<sup>[7]</sup> The role of quad strengthening has been described in the recovery from total knee replacement.<sup>[6]</sup> Our case may help add to the discussion that quad strengthening may play a role in deferring surgery if combined with weight loss.

Our patient reported less pain and improved joint mobility. These findings suggest that joint inflammation may play a role. What is unclear is the mechanism by which weight loss decreases joint inflammation? An important consideration in her case is a joint injury. Our patient was seen 3 months after a meniscal repair secondary to a progressive injury and an evaluation of the patient at that time suggested that she was a candidate for total knee replacement, as she did have end stage knee DJD. What was unclear was if the patient’s pain was attributed to her healing knee or tied to her progressive DJD. This is one of the important limitations of our study. Another important limitation is that our findings are attributed to only one patient. We do believe that our patient’s progress should be highlighted and her case may encourage future studies.

## CONCLUSION AND FUTURE CONSIDERATIONS

This patient demonstrated that a significant reduction in weight loss (15%) may defer surgical

intervention (total knee replacement). Causality for this association has yet to be determined. We hope to add to the body of literature that describes the benefits of weight loss and hope to advocate for prospective studies that describe how significant weight loss may delay or eliminate the need for total knee replacement.

## REFERENCES

1. Suri P, Morgenroth DC, Hunter DJ. Epidemiology of osteoarthritis and associated comorbidities. *PM R* 2012;4 5 Suppl: S10-9.
2. Ringdahl E, Pandit S. Treatment of knee osteoarthritis. *Am Fam Physician* 2011;83:1287-92.
3. Christensen R, Astrup A, Bliddal H. Weight loss: The treatment of choice for knee osteoarthritis? A randomized trial. *Osteoarthritis Cartilage* 2005;13:20-7.
4. Aaboe J, Bliddal H, Messier SP, Alkjær T, Henriksen M. Effects of an intensive weight loss program on knee joint loading in obese adults with knee osteoarthritis. *Osteoarthritis Cartilage* 2011;19:822-8.
5. Christensen R, Bartels EM, Astrup A, Bliddal H. Effect of weight reduction in obese patients diagnosed with knee osteoarthritis: A systematic review and meta-analysis. *Ann Rheum Dis* 2007;66:433-9.
6. Zeni JA Jr, Axe MJ, Snyder-Mackler L. Clinical predictors of elective total joint replacement in persons with end-stage knee osteoarthritis. *BMC Musculoskeletal Disord* 2010;11:86.
7. Mizner RL, Petterson SC, Stevens JE, Axe MJ, Snyder-Mackler L. Preoperative quadriceps strength predicts functional ability one year after total knee arthroplasty. *J Rheumatol* 2005;32:1533-9.

**Source of Support:** Nil, **Conflict of Interest:** None declared.