

Effective Management of Large Radicular Cysts Using Surgical Enucleation vs. Marsupialization

Two Cases Report

Fawzi Riachi*, Carine Tabarani**

Abstract

Radicular cysts are the most common odontogenic cystic lesions of inflammatory origin and are managed either by surgical enucleation or by marsupialization. We illustrate the possibility of complete healing of cystic periapical lesions in permanent and mixed dentition with conservation of vital structures.

This article aims to report two clinical cases of radicular cysts of huge proportion treated with two different techniques in an effort to shed some light on the advantages and disadvantages as well as a brief discussion of the leading criterias that should be taken into consideration when assessing the treatment modalities.

Key words: *Radicular cysts – Odontogenic lesions – Surgical enucleation – Marsupialization – Permanent and mixed dentition*

Résumé

Les kystes radiculaires sont considérés comme les lésions odontogéniques d'origine inflammatoire les plus communes, et sont traités par énucléation chirurgicale ou par marsupialisation. On illustre la possibilité d'obtenir une cicatrisation complète des kystes périapicaux au niveau de la dentition permanente et mixte avec conservation des structures anatomiques.

L'objectif de cet article est de présenter deux cas cliniques de kystes radiculaires de large proportion traités par deux différentes techniques afin d'orienter le praticien dans le choix de la technique la mieux adaptée. Les avantages et les inconvénients de chacune des techniques sont abordés et discutés. Nous avons tenté de faire le point sur les critères actuels pris en considération lors de la décision des modalités thérapeutiques.

Mots clés: *Kystes radiculaires – Lésions odontogéniques – Énucléation chirurgicale – Marsupialisation – Dentition permanente et mixte*

* Dr. Chir. Dent., CES, D.U, DEA,
Chef de service de Chirurgie Orale,
Faculté de médecine dentaire,
Université Saint-Joseph

** Dr. Chir. Dent., DES Odont. Chir., D.U Patho. Orale

The most frequent odontogenic cyst of teeth bearing areas is the radicular cyst, also called periapical cyst. Radicular cysts are rare in the primary dentition, representing only 0.5 to 3.3% of the total number of radicular cysts in primary dentitions⁶. It arises from epithelial Malassez rests in periodontal ligament as a result of inflammation.

Two techniques can be used in clinical practice for surgical removal of cysts: enucleation and marsupialization.

Enucleation is defined as a complete removal of the cystic lining with healing by primary intention while marsupialization is synonymous with Partsch's operation¹⁷, and is the conversion of a cyst into a pouch¹, it requires considerable aftercare and patient cooperation in keeping the cavity clean whilst it resolves and heals by relieving the internal pressure, it is indicated when cyst is in close proximity to vital structures and where there is significant risk of injury with enucleation. The marsupialization concerns not only the radicular cysts, also follicular cysts can be treated by this technique in order to conserve and guide the eruption of permanent teeth.

Although small cystic lesions frequently heal simply with endodontic therapy, larger lesions may need additional treatment. Untreated cysts may expand causing local tissue destruction and deformities.

In a mixed dentition, several odontogenic developmental processes take place, therefore the surgical technique of choice should be the one with the least likelihood of iatrogenic damage.

A case is presented for attempting the conservative treatment of marsupialization, and a workable protocol for this is applied.

The purpose of this article is to characterize the diagnosis features of large cystic jaw lesions in two cases and to compare the treatment modalities whether it is marsupialization that has prove to be effective and quite comfortable for the patient or surgical enucleation that will assure a healing with minimal aftercare.

Case 1

A 10 year-old male patient consulted our private clinic with a complaint of painless swelling in the lower right back region of the jaw present since 1 month.

Physical examination revealed a grossly decayed 8.4 and 8.5 teeth, with considerable

expansion of buccal cortical plate in the premolar and molar regions.

Panoramic radiograph revealed a single well-defined periapical unilocular radiolucency with a radio-opaque rim, of about 3 x 2 cm in size, extending from the 4.4 to the 4.6 anteroposterioly and displacing the 4.4 and 4.5 permanent teeth (Fig. 1).

Based on history, clinical and radiographic examination, a provisional diagnosis of radicular cyst associated with the 8.4 and 8.5, and of a follicular cyst related to the 4.4 and 4.5 was made.

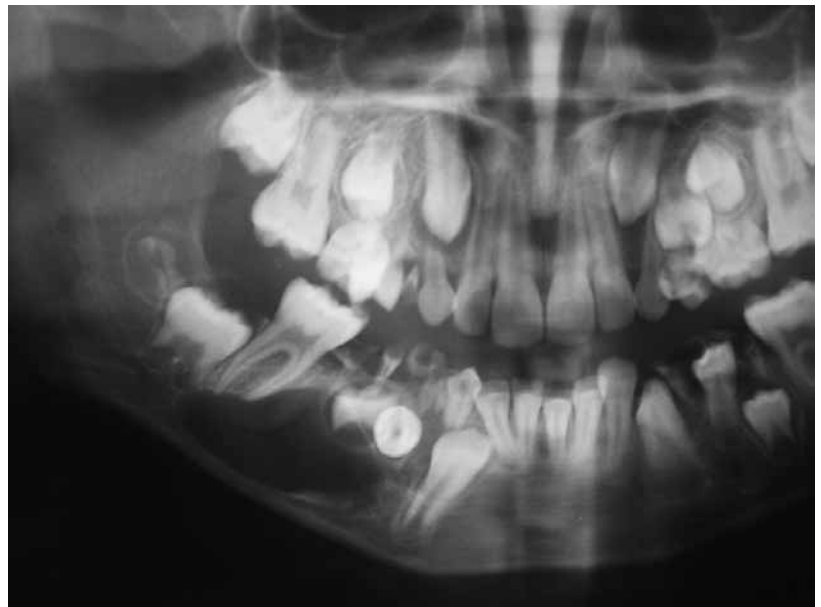


Fig 1 : Panoramic Xray showing a large radiolucency with a marked radio-opaque rim in the right mandible which displaced the 4.4 and 4.5 tooth buds.

The case was posted for surgical marsupialization of the lesion under local analgesia, the superficial lesional lining was enucleated and the teeth 8.4 and 8.5 removed, followed by an obturator incorporated into a partial denture treatment to guide the eruption of the premolars and bone healing, also to prevent food accumulation and maintain a patent surgical opening (Figs. 2, 3).

Postsurgical period was uneventful and histopathological features were consistent with the clinical diagnosis of radicular cyst (Fig. 5). The cystic cavity was lined by non keratinized stratified squamous epithelium with mixed inflammatory infiltration present.

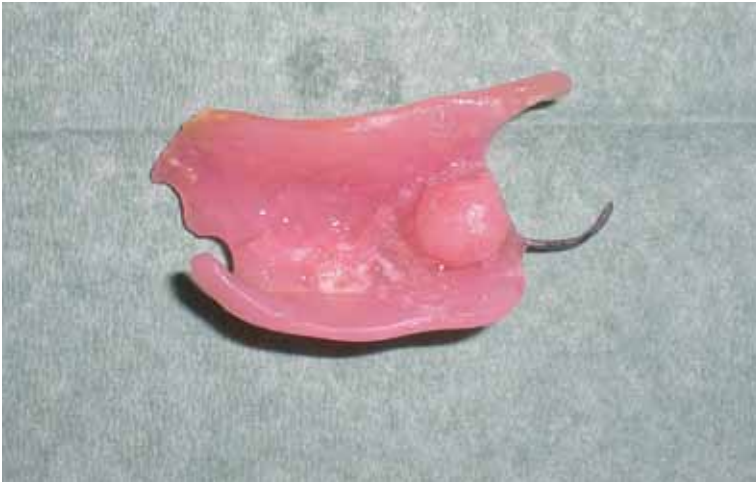

Fig 2 : Final surgical stent with obturator incorporated into partial denture.

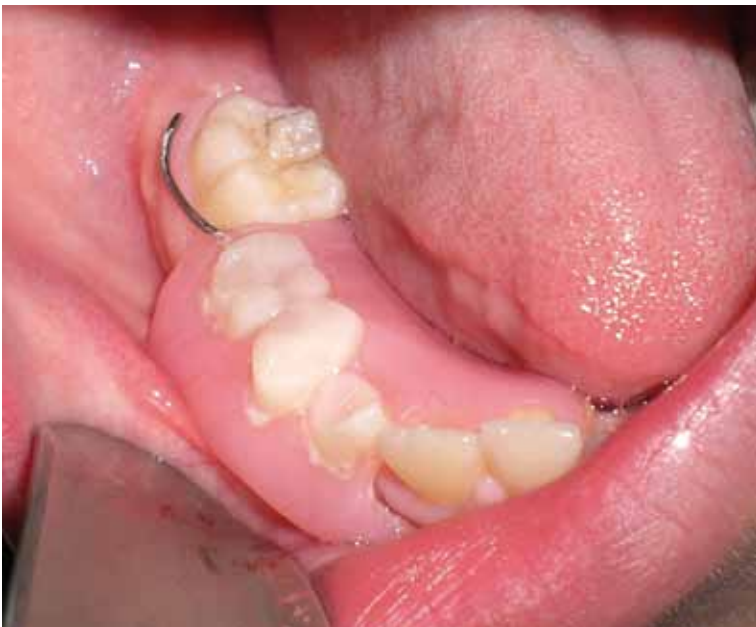

Fig 3 : Acrylic exteriorization unit in place, guiding the eruption of the premolars.

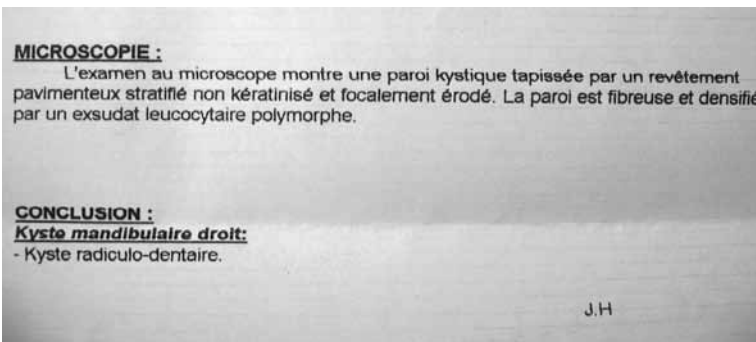


Fig 5 : Histopathological results confirming the diagnosis of radicular cyst.

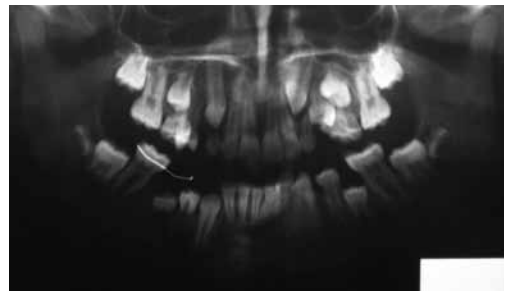


Fig 4 : Panoramic Xray after 11 months, showing the premolars emerging during the eruption process; note the satisfactory bone healing.

An 11 months postoperative recall panoramic Xray, showed substantial reduction in the size of the cystic cavity, and both right premolars were erupted into normal position (Fig. 4). A 3 years follow-up panoramic Xray showed the lower right premolars completely erupted, they were firm and in normal occlusion (Figs. 6,7).

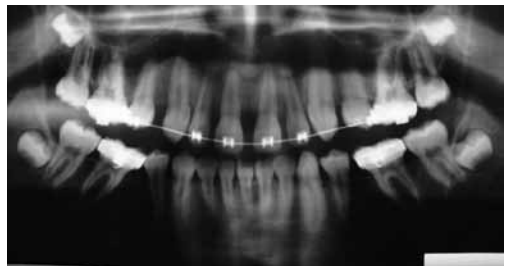


Fig 6 : Three years after enucleation, the premolars erupted into normal alignment.

Case 2

A 39 year – old man consulted us for a severe pain and a large swelling on the upper part of the left cheek.

The patient experienced recurrent episodes of such complaints for the last three months along with a gradual increase in swelling.

Intraoral examination was carried out which revealed a well defined swelling with a smooth surface, extending from the 2.4 to the 2.7.

The swelling was approximately 6×3 cm in dimension.

Vitality testing of the incriminated teeth revealed all the posteriors teeth vital except for the decayed 2.6 tooth .

Radiographs (panoramic & CT Scan) revealed an osteolytic radiolucency well delineated extending from the roots of left first premo-

lar (2.4) to the impacted 2.8 tooth, the large lesion expanded the buccal cortical and displaced the Schneiderian membrane (Figs. 8,9).

From history, clinical and radiographic examinations a provisional diagnosis of infected radicular cyst was made.

It was decided to surgically enucleate the lesion under local analgesia.

Reflection of a mucoperiosteal flap, followed by removal of bone and exposure of the lesional membrane was carried out (Figs. 10, 11, 13). Aspiration of the contents of the cystic lesion was a valuable diagnostic aid (Fig. 12), it revealed a yellow semi-viscous fluid. The lesional wall was hypertrophic and adhered partly to the mucosa of the base of the maxillary sinus, therefore, the lesional mass was totally curetted to a maximum extent. Enucleation of the cystic lesion and extraction of the 2.6 and 2.8 with care of the wound and suturing were done. Enucleating biopsy of the periapical lesion was diagnosed histologically as radicular cyst with a layer of non-keratinised stratified squamous epithelium (Fig. 15).

At the 12 months follow-up, no complications or recurrence were noticed with complete bone healing and repneumatization of the antrum (Fig. 16).

Discussion

The surgical approach to cystic lesions of the jaws is either marsupialization or enucleation⁹. The treatment of choice is dependent on the size and localization of the lesion, the bone integrity of the cystic wall and its proximity to vital structures.

Cysts are usually enucleated, where the cystic lining is separated from its inner bony surface and removed and the cavity allowed to fill with blood clot. Alternatively the cyst may be marsupialized to relieve the internal pressure.

According to Neaverth^{4,17}, marsupialization consists of deroofting the outer wall of a cyst by surgical incision and establishing a permanent opening by suturing the remaining cystic wall to the mucosal surface followed by an obturator treatment.

In our first case the marsupialization technique applied with extraction of associated primary teeth and preservation of permanent tooth buds appeared to be the most suitable treatment option with a healing period not exceeding 11 months with a normal align-

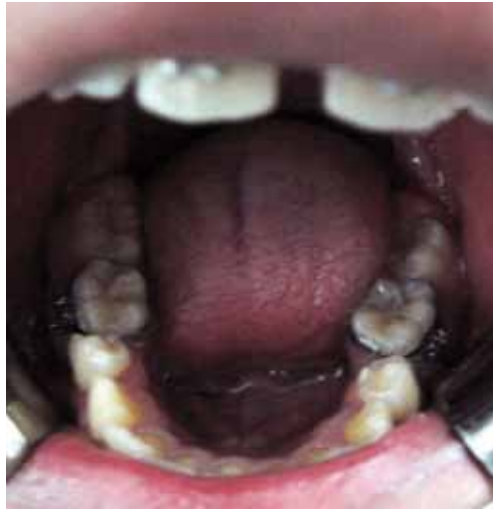

Fig 7: Intra-oral view 3 years postoperatively, both premolars were erupted into normal position. They were firm and in normal occlusion.

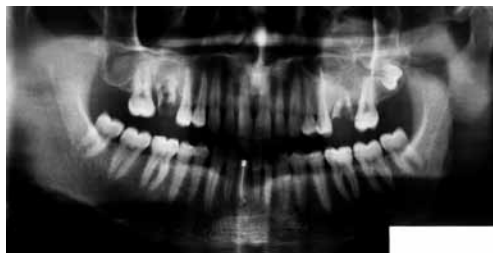

Fig 8: Panoramic Xray showing a radiolucent lesion with radio-opaque rim extending from the 2.4 to the 2.8 teeth.

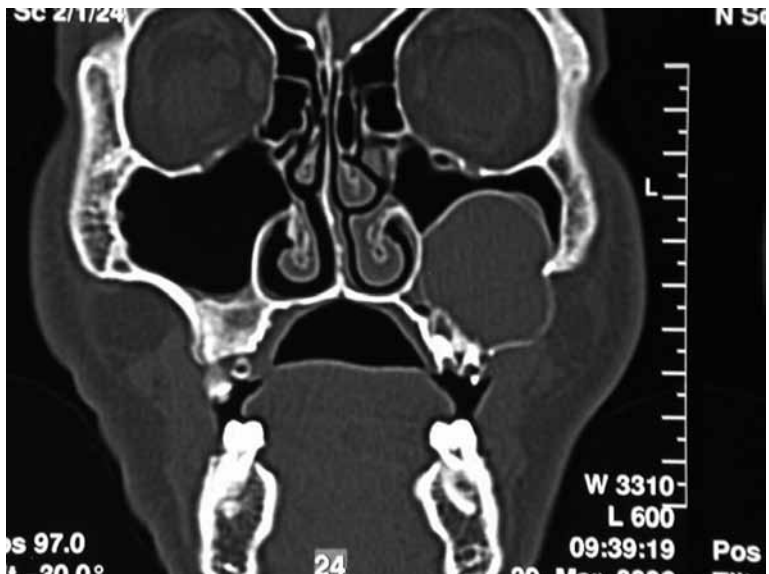


Fig 9: Frontal scanner showing the eroded buccal cortical plate.

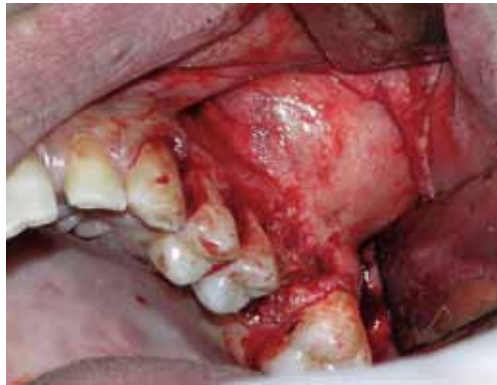

Fig 10: Peroperative surgical view. Note the marked lateral expansion of the lesion leading to loss of the lateral cortical plate of the left maxilla.

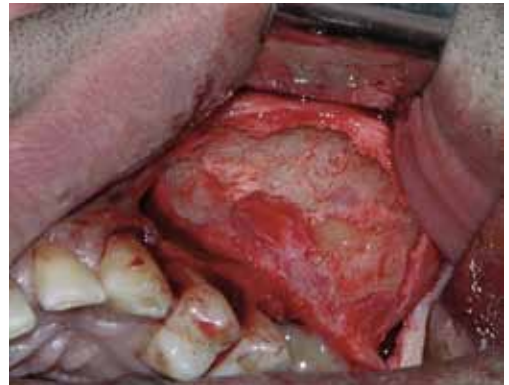

Fig 11: Exposure of the lesional membrane.

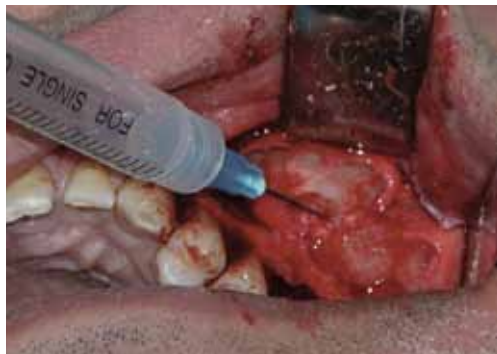

Fig 12: Aspiration of the contents of the lesion.

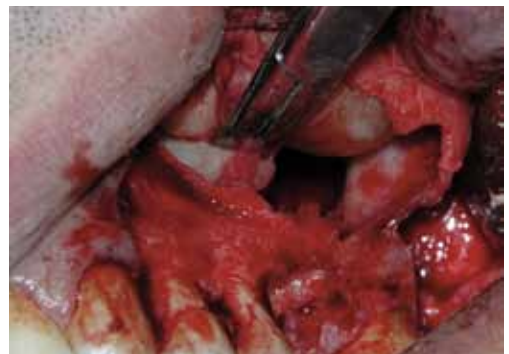

Fig 13: Enucleation of the lesion.

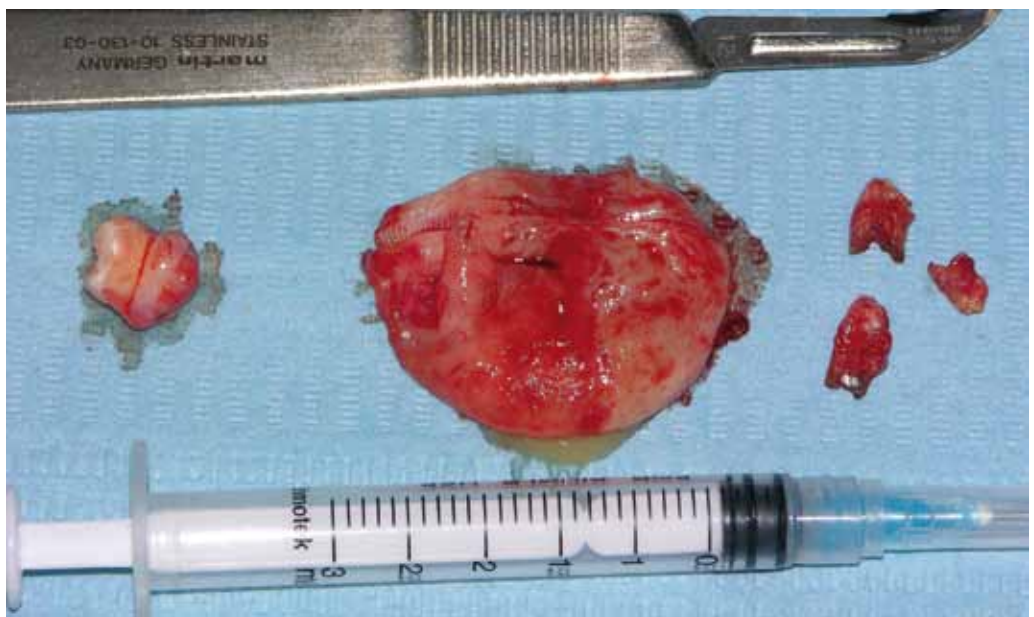

Fig 14: Surgical specimen after enucleation with the removed 2.6 and 2.8 teeth.

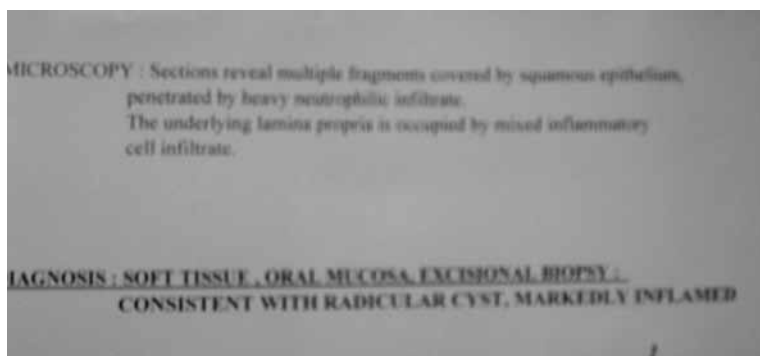


Fig 15 : Histopathological results confirming the diagnosis of radicular cyst.

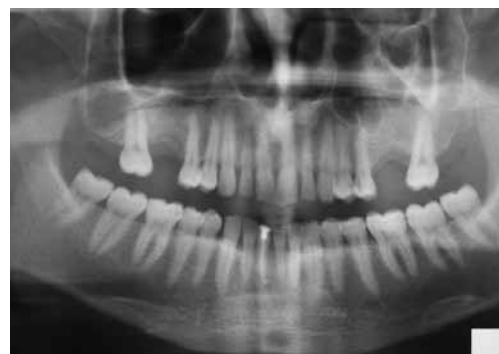

Fig 16 : Panoramic Xray after 1 year. Satisfactory bony radio-opacity and neoformation, demonstrating a good healing ; note the repneumatization of the antrum.

TABLE 1
Duration of marsupialization

	Cases	Period of application
Freedland ¹⁶	6	1 week – 14 months
Neaverth ¹⁷	4	5 weeks – 1 year

TABLE 2
Advantages and disadvantages of marsupialization and surgical enucleation in the treatment of cystic lesions :

	Advantages	Inconvenients
Enucleation and primary closure	<ul style="list-style-type: none"> • Complete treatment in one session • Cystic wall is available for histological examination • A period of shrinkage may allow for enucleation and conservation of adjacent structures (inferior dental nerve, tooth bud) 	<ul style="list-style-type: none"> • In very large cysts the clot may break down and become infected • May deprive the adjacent teeth of their blood supply and render them non-vital • Uncomplete histopathological examination • It is difficult to keep the cavity clean, it requires regular washing • The opening will also shrink, making access difficult • Ineffective for odontogenic keratocysts because they enlarge by growth of lining, and not by increasing of the hydrostatic pressure
Marsupialization technique	<ul style="list-style-type: none"> • Shrinkage may allow more teeth to be preserved • Cystic cavity reduces in size faster due to centripete bone healing and 10 months of follow-up may be required¹ 	<ul style="list-style-type: none"> • Requires a good patient cooperation

ment of permanent teeth that occurred spontaneously. In our second case the enucleation of the maxillary cystic lesion revealed to be gratifying and less troublesome in the case of large cysts which involve the antrum and where dependent drainage is not always possible.

A complete bone healing was obtained after 1 year.

Surgical management of large maxillary cysts may result in loss of bone and vital teeth in proximity to the defect.

Literature regarding treatment options and their outcomes are scarce and vague. Marsupialization is favored because of lower morbidity and the fact that bony ingrowth occurs as the lesion shrinks in size, resulting in more normal bony contour. Thus it requires a long period of postoperative management imposing a burden on the patient (Table 2). It is very likely that reduction of intracystic pressure is a key factor in the healing process.

Although it is not known what percentage of radicular cyst can be expected to heal with only marsupialization, it is a viable treatment modality that bears consideration when treating large cystic lesions.

Nevertheless, no matter which diagnosis it might be, the treatment option should be kept as conservative as possible.

Conclusion

The two clinical cases illustrate the possibility of complete healing and conservation of vital structures using either aggressive or minimal invasive approach.

Despite the disadvantages of the marsupialization technique, and considering this together with the unnecessary loss of bone and vital teeth obtained with the enucleation, the marsupialization revealed to be more advantageous in many respects and is therefore considered a worthwhile procedure for cases which the large radiolucent area involves the antrum and tooth buds.

References

1. Sakkas N, Shoen R. Obturator after marsupialization of a recurrence of a radicular cyst of the mandible. *Oral Surg Oral Med Oral Pathol Oral Radiol Endod* 2007; 103: 16-18.
2. Carter L, Carr P. Customised stents for marsupialization of jaw cysts . *Br J Oral Maxillofac Surg* 2007; 45: 429-431.
3. Chiapasco M, Rossi A. Spontaneous bone regeneration after enucleation of large mandibular cysts : a radiographic computed analysis of 27 consecutive cases. *J Oral Maxillofac Surg* 2000; 58: 942-948.
4. Takase T, Wada M. Treatment of large radicular cysts by modified marsupialization. *J Nichon Univ Sch Dent* 1996; 98: 161-168.
5. Rees JS. Conservative management of a large maxillary cyst. *Int Endod J* 1997; 30: 64-67.
6. Shear M. Radicular and residual cysts . In : *Cysts of the oral region* , 3rd edition. Wright, Bristol: 1992 , pp.136-162.
7. Mass E, Kaplan F. A clinical and histopathological study of radicular cysts associated with primary molars. *J Oral Pathol Med* 1995; 24: 458-461.
8. Delbem ACB, Cunha RF. Conservative treatment of a radicular cyst in a 5 years -old child: a case report. *Int J Ped Dent* 2003; 13: 447-450.
9. Bodner L. Cystic lesions of the jaws in children. *Int J Pediat Otorhinolaryngol* 2002; 62: 25-29.
10. Iatrou I, Theologie-Iygidakis N. Intraosseous cystic lesions of the jaws in children : a retrospective analysis of 47 consecutive cases. *Oral Surg Oral Med Oral Pathol Oral Radiol Endod* 2009; 107: 485-492.
11. Farmand M. Indication and results of marsupialization of large cysts. *Deutsch Zahnarztl Z* 1985; 40: 623-630.
12. Hanada K, Yoshimura Y. Clinical investigation of marsupialization for the cystic lesion of the jaws. *J Oral Maxillofac Surg* 1983; 41: 274-276.
13. Chiu WK, Sham AS, Hung JN. Spontaneous alignment of permanent successors after enucleation of odontogenic cysts associated with primary teeth. *Br J Oral Maxillofac Surg* 2008; 46: 42-45.
14. Savage NW, Adkins KF, Weir AV, Grundy GE. A histological study of cystic lesions following pulphtherapy in deciduous molars. *J Oral Pathol Med* 1986; 15: 209-212.
15. Schulz ZM , Von Arx T. Histology of periapical lesions obtained during apical surgery. *J Endod* 2009; 35: 634-642.
16. Freedland JB. Conservative reduction of large periapical lesions. *J Oral Surg* 1970; 29: 455-464.
17. Neaverth EJ, Burg HA. Decompression of large periapical cystic lesions. *J Endodont* 1982; 8: 175-182.