



Safety of intrastromal injection of polyhexamethylene biguanide and propamidine isethionate in a rabbit model

Chen-Chee Lim^a, I-Chen Peng^b, Yi-Hsun Huang^{a,c,*}

^a Department of Ophthalmology, National Cheng Kung University Hospital, College of Medicine, National Cheng Kung University, Tainan, Taiwan

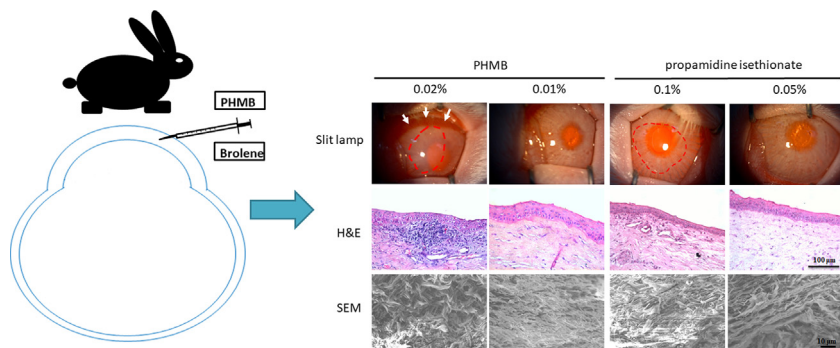
^b Department of Biomedical Engineering, National Cheng Kung University, Tainan, Taiwan

^c Institute of Clinical Medicine, College of Medicine, National Cheng Kung University, Tainan, Taiwan

HIGHLIGHTS

- Intrastromal Injection can be considered in deep *Acanthamoeba* keratitis (AK).
- Intrastromal injection of 0.01% PHMB or 0.05% propamidine isethionate is safe.
- This model system could help to determine the toxic effect of other agents.
- Further experiments may determine the toxicity of multiple intrastromal injection.
- AK animal model is required to evaluate the true effect of intrastromal injection.

GRAPHICAL ABSTRACT



ARTICLE INFO

Article history:

Received 26 September 2019

Revised 27 November 2019

Accepted 29 November 2019

Available online 4 December 2019

Keywords:

Acanthamoeba keratitis
Corneal intrastromal injection
Polyhexamethylene biguanide (PHMB)
Propamidine isethionate
Corneal toxicity

ABSTRACT

Acanthamoeba keratitis (AK) is difficult to treat, especially when the corneal deep stroma is involved. Intrastromal injection of antimicrobial agents is an effective adjuvant therapy for deep recalcitrant microbial keratitis; however, it has not been used to treat AK due to suspected drug toxicity. The purpose of this study was to evaluate the toxicity of corneal intrastromal injection of polyhexamethylene biguanide (PHMB) and propamidine isethionate (Brolene[®], Sanofi) in New Zealand white rabbits. We performed intrastromal injections of PHMB (0.02 or 0.01%) and propamidine isethionate (0.1 or 0.05%) into the rabbits' right corneas. The left corneas were injected with phosphate-buffered saline as controls. The rabbits were sacrificed on the 7th day after injection, and the corneal buttons were harvested for further evaluation by slit lamp microscopy, specular microscopy, hematoxylin and eosin staining, scanning electron microscopy, terminal deoxynucleotidyl transferase (TdT) dUTP nick-end labeling assays, and WST-1 assays. We found that intrastromal injection of 0.02% PHMB or 0.1% propamidine isethionate resulted in corneal epithelial erosion, corneal edema, and severe neovascularization. However, 0.01% PHMB or 0.05% propamidine isethionate did not induce obvious cornea toxicity. In conclusion, intrastromal injection of 0.01% PHMB or 0.05% propamidine isethionate may be promising adjunctive treatments for deep stromal AK.

© 2019 The Authors. Published by Elsevier B.V. on behalf of Cairo University. This is an open access article under the CC BY-NC-ND license (<http://creativecommons.org/licenses/by-nc-nd/4.0/>).

Peer review under responsibility of Cairo University.

* Corresponding author at: Department of Ophthalmology, National Cheng Kung University Hospital, College of Medicine, National Cheng Kung University, 138 Sheng-Li Rd., 704 Tainan, Taiwan.

E-mail address: jackhyh@gmail.com (Y.-H. Huang).

<https://doi.org/10.1016/j.jare.2019.11.012>

2090-1232/© 2019 The Authors. Published by Elsevier B.V. on behalf of Cairo University.

This is an open access article under the CC BY-NC-ND license (<http://creativecommons.org/licenses/by-nc-nd/4.0/>).

Introduction

Acanthamoeba spp. are free-living, ubiquitous protozoa found mainly in humid soil and in water reservoirs. They are the causative agents of *Acanthamoeba* keratitis (AK), a vision-threatening corneal infection first reported in 1973 in the United States [1]. *Acanthamoeba* trophozoites are relatively responsive to many therapies, while *Acanthamoeba* cysts are well suited to survive extreme environmental conditions, including medications. The highly resistant cyst form makes AK treatment difficult [2].

AK has a high cure rate if diagnosis could be made as early as possible [3]. If diagnosis is delayed, AK can become refractory to traditional treatment, particularly at later stages when the infection penetrates the deep stroma. There is no consensus on the treatment for AK till now. A recent study compared the therapeutic effect of different topical anti-amoebic agents (0.02% polyhexamethylene biguanide (PHMB) monotherapy, 0.02% PHMB + 0.1% diamidine, 0.02% PHMB + 0.02% chlorhexidine + 0.1% diamidine, and 0.1% diamidine monotherapy), which showed that 0.02% PHMB monotherapy for the initial treatment of AK is as effective as biguanide + diamidine combination therapy [4]. Nevertheless, current conventional therapies for AK are 0.02% biguanide (PHMB or chlorhexidine) in combination with a 0.1% diamidine (propamidine isethionate or hexamidine) applied hourly for at least 1 week and then tapered weekly according to the patient's clinical response [5,6]. For patients with late diagnosis and poor drug responses, alcohol-assisted epithelial debridement can be performed as an adjuvant therapy to avoid therapeutic keratoplasty [6].

Intrastromal injection of antimicrobial agents may be promising adjunctive treatments for deep recalcitrant microbial keratitis, which responds poorly to conventional treatment modalities [7–10]. However, this strategy has not been tested in AK due to suspicions of drug toxicity. The concentration-dependent corneal toxicities of anti-amoebic agents have been previously reported [11], but their toxicity after corneal intrastromal injection remains untested. Therefore, in this study, we have investigated corneal toxicity in rabbit eyes after intrastromal injection of PHMB and propamidine isethionate, to determine safe concentrations for AK treatment. With safe dosages, intrastromal injection of PHMB or propamidine isethionate could represent promising adjuvant therapies for deep AK.

Material and methods

All animal procedures were performed in accordance with the Association for Research in Vision and Ophthalmology statement for the use of animals in ophthalmic and vision research and were approved by the University Institutional Animal Care and Use Committee of National Cheng Kung University (NCKU).

Preparation of PHMB and propamidine isethionate

Two anti-amoebic agents were used in our study. PHMB is a synthetic cationic polymer composed of repeating basic biguanide units connected by hexamethylene hydrocarbon chains [12] and propamidine isethionate is a polyether compound known as bis(4-guanidinophenyl) ether of propane-1,3-diol, which works through inhibiting synthesis of DNA, RNA, phospholipids, and proteins [13]. PHMB (Cosmocil CQ 20%, Avecia Biocides, U.K.) was diluted to 0.02 and 0.01%. Propamidine isethionate (0.1%; Brolene eyedrops; Sanofi-Aventis, Australia) was used as supplied, and also diluted to 0.05%.

Animals

The right eyes of 12 New Zealand white rabbits were intrastromally injected with 0.1 mL of 0.02% PHMB, 0.01% PHMB, 0.1% pro-

pamidine isethionate, or 0.05% propamidine isethionate ($n = 3$ per treatment). The left eyes served as controls and were subjected to intrastromal injection of 0.1 mL phosphate-buffered saline (PBS).

Corneal intrastromal injection

Rabbits were anesthetized by an intramuscular injection of ketamine hydrochloride (20 mg/kg) and xylazine (10 mg/kg) before intrastromal injection. Topical anesthesia was provided using Alcaine (proparacaine hydrochloride 0.5%; Alcon, Fort Worth, TX). Under a surgical microscope, intrastromal injection of 0.1 mL of solution was performed by 30-gauge needle at three different sites in the paracentral corneal stroma. The animals were sacrificed 7 days after intrastromal injection by intravenous injection of a lethal dose of pentobarbital. The corneal buttons were harvested and examined by slit lamp microscopy, specular microscopy (SM), Hematoxylin and eosin (H&E) staining, scanning electron microscopy (SEM), Terminal deoxynucleotidyl transferase (TdT) dUTP nick-end labeling (TUNEL) assay, and cell viability test.

Isolation and culture of corneal cells

Isolated rabbit corneal endothelial cells were incubated with 0.5 g/L trypsin-0.2 g/L ethylenediaminetetraacetic acid (Invitrogen-Gibco, Karlsruhe, Germany) at 37 °C for 10 min. Descemet's layer was removed by mechanical dissection under the microscope. Endothelial cells were cultured in 25 cm² culture flasks containing Dulbecco's modified Eagle's medium (DMEM; Sigma-Aldrich) supplemented with 10% fetal calf serum (FCS; Sigma-Aldrich), 24 mg/mL adenine, 4 mM L-glutamine, 1% antibiotic solution (Invitrogen-Gibco), and growth factors (0.4 mg/mL hydrocortisone, 1.3 ng/mL triiodothyronine, 8 ng/mL cholera toxin, and 5 mg/mL insulin). The culture medium was changed every 3 days. To isolate rabbit corneal stromal keratocytes, the corneal epithelial and endothelial layers were removed carefully by mechanical scraping. The remaining stroma was cut into small explants approximately 3 mm in size, which were placed in plastic culture dishes to allow keratocyte growth. The growth media was DMEM supplemented with 10% FCS, 4 mM L-glutamine, and 1% antibiotic solution. The culture medium was changed every 3 days.

Examinations

Slit lamp microscopy

The rabbits' corneas were examined by slit lamp microscopy to evaluate the presence of possible corneal changes, including corneal edema, epithelial erosion, corneal neovascularization, and corneal haze 7 days after intrastromal injection.

Specular microscopy (SM)

Endothelial cell counts were measured on a Konan KSS-EB10 SM (Konan Medical USA, Irvine, CA) 7 days after intrastromal injection. The endothelial cell density, coefficient of variation (CV), and percentage of hexagonal cells (6A%) were determined in at least 50 endothelial cells per replicate.

Hematoxylin and eosin (H&E) staining

We prepared 6-μm sections from corneas, stained them with H&E, and imaged them under a light microscope (E-800 Leica, Solms, Germany) equipped with a digital video camera (Nikon DS-Ri1, Tokyo, Japan).

Scanning electron microscopy (SEM)

Corneal specimens were rinsed with PBS and immediately immersed in 2.5% glutaraldehyde at 4 °C for at least 24 h. The specimens were then rinsed with Milli-Q (MQ) water three times for 5 min each, and transferred to 1% tannic acid for 60 min at room temperature. The specimens were subsequently rinsed with MQ water three times for 5 min each. The samples were then dehydrated by immersion in a graduated ethanol series according to the following scheme (5 min each): 30% (once), 50% (once), 70% (once), 95% (twice), and 100% (three times). After dehydration, specimens were soaked in hexamethyldisilazane for 15 min, then placed in an empty desiccator and left in a fume hood overnight at room temperature. The specimens were coated with gold and ultrastructural changes were evaluated using an SEM at different magnifications.

Terminal deoxynucleotidyl transferase (TdT) dUTP nick-end labeling (TUNEL) assay

The TUNEL assay was used to quantitatively detect apoptosis in the corneas, using the Roche In Situ Cell Death Detection Kit, AP. Briefly, dewaxed and rehydrated tissue sections were incubated with Proteinase K working solution for 15–30 min at room temperature. Slides were rinsed with PBS and the area around the samples was dried with filter paper. The lid was added and the cells were incubated in TUNEL reaction mixture (50 μ L per well) for 60 min at 37 °C in the dark. The slides were subsequently rinsed three times with PBS. The samples were observed under a fluorescence microscope using an excitation wavelength in the range of 450–500 nm and detection in the range of 515–565 nm (green). TUNEL-positive nuclei appeared green, while TUNEL-negative nuclei appeared blue.

Cell viability assay

The viability of keratocytes and endothelial cells was assessed using the WST-1 (Water-Soluble Tetrazolium salt-1) assay (Takara Bio, Shiga, Japan). We prepared a cell suspension containing $0.1-1.0 \times 10^6$ cells/mL in medium, added 100 μ L of the suspension to the wells of a 96-well cell culture plate, and incubated the plate for 24–

96 h at 37 °C and 5% CO₂ in a humidified incubator for cell culture. Then, 10 μ L of CytoSelect™ WST-1 Cell Proliferation Assay Reagent was added to each well, and the plate incubated at 37 °C and 5% CO₂ for 0.5–4 h. Absorbance was measured at 450 nm using a plate reader.

Statistical analysis

Statistical significance was analyzed using the Student's *t*-test. *P* values < 0.05 were considered statistically significant. All data are expressed as the mean \pm SD. Statistical analyses were performed using GraphPad Prism 6.0 software.

Results

Slit lamp examination

Eyes were evaluated 7 days after intrastromal injection. Corneas injected with PBS were clear in appearance (Fig. 1A), while corneal edema, epithelial erosion, and severe neovascularization were observed with 0.02% PHMB treatment (Fig. 1B). Corneas injected with 0.01% PHMB were also clear under slit lamp examination (Fig. 1C). For propamidine isethionate, the 0.1% solution resulted in corneal edema with epithelial erosion, but no neovascularization was observed (Fig. 1D). No corneal edema or erosion was observed with 0.05% propamidine isethionate (Fig. 1E).

H&E staining

Histological sections of the corneas were observed by H&E staining. In control corneas treated with PBS, no obvious changes were observed (Fig. 1F). However, massive inflammatory cell invasion and neovascularization were observed after 0.02% PHMB injection (Fig. 1G). With 0.01% PHMB, the stroma was thickened, but no inflammatory cells were observed (Fig. 1H). In corneas injected with 0.1% propamidine isethionate, enlarged stromal spaces containing few inflammatory cells were observed (Fig. 1I), while no obvious changes were observed with 0.05% propamidine isethionate treatment (Fig. 1J).

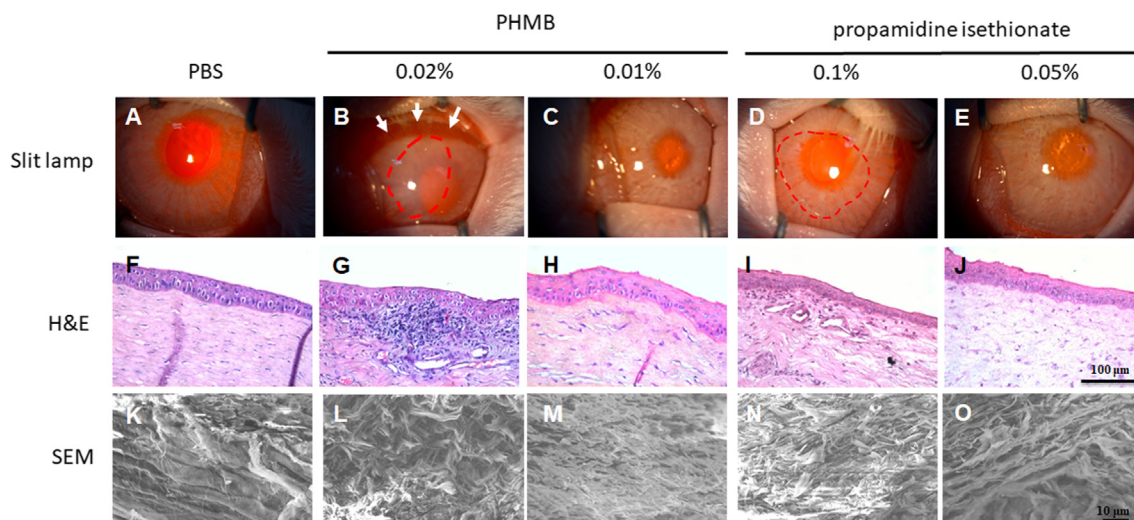


Fig. 1. Slit lamp, H&E, and SEM analysis. Slit lamp results from control (A), PHMB-treated (B,C), and propamidine isethionate-treated (D,E) corneas. H&E staining of control (F), PHMB-treated (G,H), and propamidine isethionate-treated (I,J) corneas. SEM images of control (K), PHMB-treated (L,M), and propamidine isethionate-treated (N,O) corneas. Arrows indicate neovascularization and circles indicate corneal erosion and edema area.

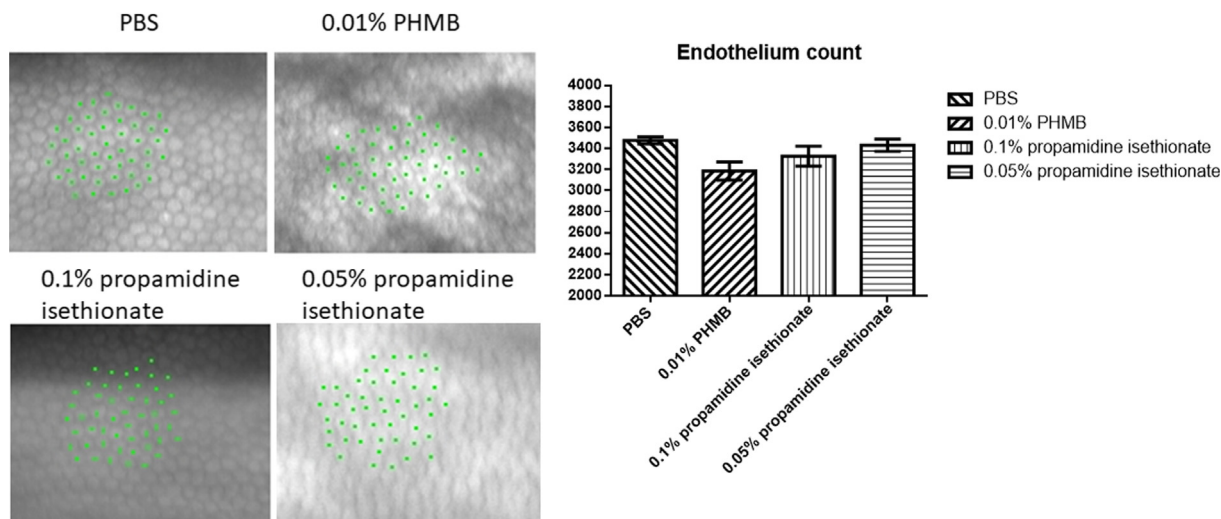


Fig. 2. Specular microscopy examination. Endothelial cell counts were measured 7 days after intrastromal injection. Analyzable images were only obtained for PBS, 0.01% PHMB, and 0.1% and 0.05% propamidine isethionate. Data are presented as the mean \pm SD ($n = 3$). All $P > 0.05$ vs. the control (PBS).

Scanning electron microscopy

With PBS treatment, the collagen fibrils of the stroma were regularly arranged (Fig. 1K). Arrangements of collagenous lamellae were distorted with 0.02% PHMB (Fig. 1L), while no structural damage was observed after 0.01% PHMB (Fig. 1M). There were also disarrangements of collagen fibrils with 0.1% propamidine isethionate injection (Fig. 1N), but no structural change was found after 0.05% propamidine isethionate treatment (Fig. 1O).

Corneal endothelium toxicity

We used SM to count the endothelial cells after intrastromal injection of PHMB or propamidine isethionate. Unfortunately, the 0.02% PHMB images were too blurry for analysis, and the endothelial cells could not be counted. However, specular micropho-

tographs were obtained for the PBS, 0.01% PHMB, 0.1% propamidine isethionate, and 0.05% propamidine isethionate treatments (Fig. 2), and the cell densities were 3476.7 ± 32.4 , 3185.7 ± 86.8 , 3327.7 ± 95.3 , and 3431.0 ± 57.9 cells/mm², respectively (All $P > 0.05$ vs. the control (PBS)). We observed cytotoxicity to corneal endothelial cells with 0.02% PHMB intrastromal injections, while intrastromal injection with 0.01% PHMB, 0.1% propamidine isethionate treatment, while 0.05% propamidine isethionate did not cause significant decreases in corneal endothelial cells.

TUNEL assay

TUNEL-positive keratocytes, which indicate keratocyte apoptosis, were detected with 0.02% PHMB and 0.1% propamidine isethionate treatment, while no keratocyte apoptosis was observed with 0.01% PHMB and 0.05% propamidine isethionate (Fig. 3).

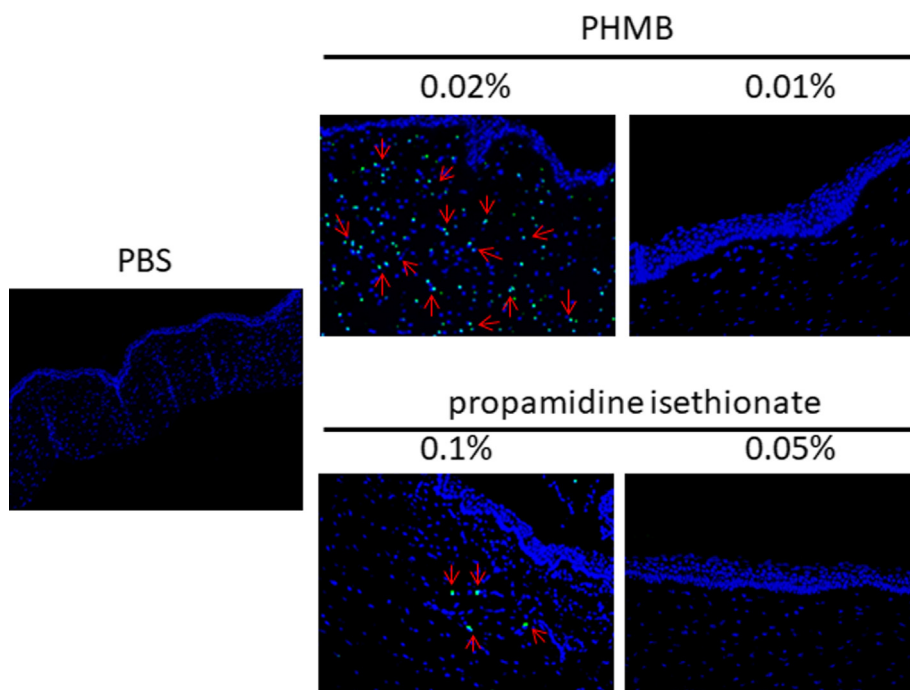


Fig. 3. TUNEL assay. TUNEL-positive cells are denoted by arrows.

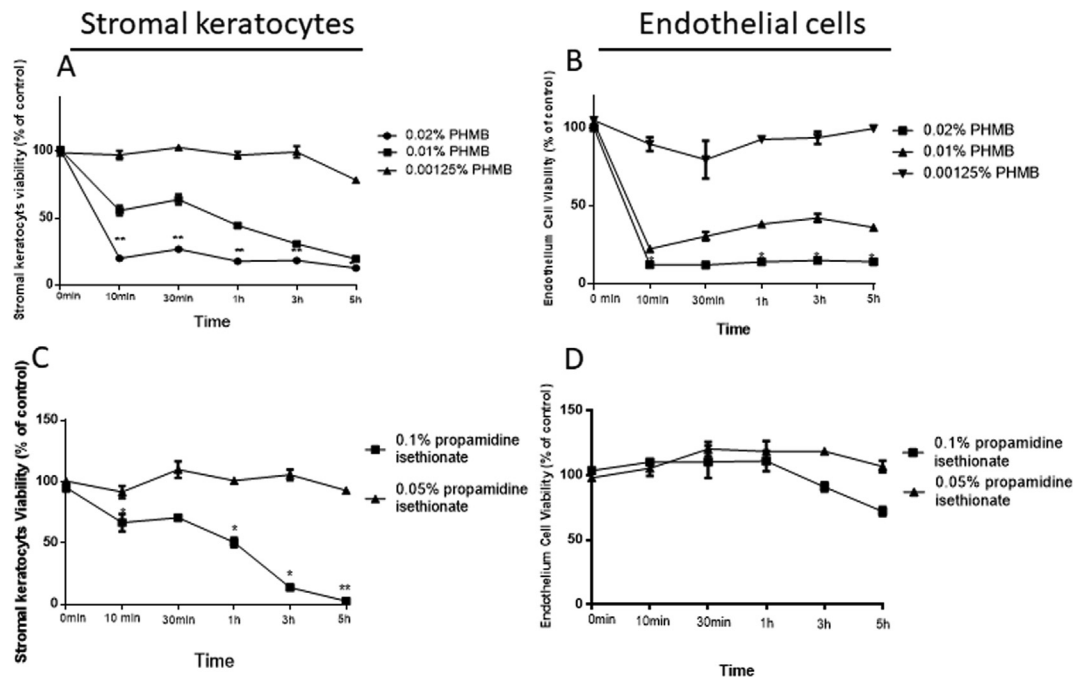


Fig. 4. Cell viability (WST-1) assay. (A) Stromal keratocyte viability with different PHMB concentrations. (B) Endothelial cell viability with different PHMB concentrations. (C) Stromal keratocyte viability with different propamidine isethionate concentrations. (D) Endothelial cell viability with different propamidine isethionate concentrations. Data are presented as the mean \pm SD ($n = 5$). * $P < 0.05$ and ** $P < 0.01$ vs. the control (PBS).

Cell viability assay

PHMB and propamidine isethionate-treated corneal stromal keratocytes and endothelial cells exhibited significant dose- and time-dependent decreases in viability (Fig. 4). PHMB had higher cell toxicity compared with propamidine isethionate. In a previous report, the combination of a low (0.00125%) concentration of PHMB with the autophagy inhibitors showed low cytopathic effects on human corneal cells and high cytopathic effects on *Acanthamoeba* cells [11]. Therefore, we used 0.00125% as our lowest concentration for PHMB in the WST-1 assay. When the PHMB concentration was decreased to 0.00125%, almost no toxicity was observed in corneal stromal keratocytes or endothelial cells ($P < 0.05$). Similarly, when the propamidine isethionate concentration was decreased to 0.05%, almost no toxicity was observed in corneal stromal keratocytes cells ($P < 0.05$).

Discussion

Previous studies have demonstrated that diffuse and deep *Acanthamoeba* cyst infiltration increases the need for therapeutic keratoplasty [14]. Intrastromal injection with antibiotics has been used to treat deep bacterial and fungal keratitis, but intrastromal injection of anti-amoebic agents has never been tested for the treatment of deep stromal AK. Theoretically, intrastromal injection of PHMB or propamidine isethionate may be an alternative treatment for patients with deep stromal AK who are unresponsive to topical anti-*Acanthamoeba* agents, decreasing the need for therapeutic keratoplasty. In addition, in patients requiring therapeutic penetrating keratoplasty (PKP), graft failure associated with AK recurrence due to residual viable cysts inside the recipient corneal stroma is not uncommon. Pre-operative intrastromal injection with PHMB or propamidine isethionate could potentially eradicate cysts in the deep stroma, reducing recurrence rates after PKP. However, there is limited data on the toxicity of PHMB and propamidine isethionate when administered via intrastromal injection. In this study, we investigated the *in vivo* and *in vitro* corneal toxicities

of different concentrations of PHMB and propamidine isethionate, in an attempt to identify effective but nontoxic concentrations for intrastromal injection.

Conventional AK treatment concentrations are 0.02% PHMB and 0.1% propamidine isethionate [2]; however, we observed significant corneal toxicity at these concentrations. Conversely, intrastromal injection of 0.01% PHMB or 0.05% propamidine isethionate was safe for the corneas. In clinical treatment, 0.02% PHMB and 0.1% propamidine isethionate will encounter serial dilution after administration. In an actual eye, 7 min after application, the concentration drops by more than half as a result of tear turnover, suggesting that 0.01% PHMB and 0.05% propamidine isethionate should be able to effectively treat AK [15].

Our results revealed that corneal toxicity increases with higher concentrations of PHMB and propamidine isethionate. PHMB concentrations higher than 0.02% and propamidine isethionate concentrations higher than 0.1% had significant corneal toxicity. Previous report also revealed that 0.02% PHMB resulted in significantly decreased viability for human corneal epithelial and endothelial cells [16]. In our study, 0.01% PHMB also caused decreased viability; however, in the absence of normal physiological eye function, this *in vitro* test could overestimate PHMB toxicity. In animal models, cornea exposure to sustained high concentrations of medications are not common. Moreover, we only give single dose of intrastromal injection in this study, the cytotoxicity is not as high as that *in vitro*.

Although the results suggest that intrastromal injection of 0.01% PHMB and 0.05% propamidine isethionate are safe adjuvant therapies for deep AK, this study has some limitations. First, some *Acanthamoeba* strains are highly resistant to PHMB, and therefore may not respond to treatment [15]. However, since the evaluation of the toxicity of corneal intrastromal injections has been established, other anti-amoebic agents can be tested for these resistant strains [17]. Second, an animal model of AK infection is required to evaluate the true effects and pharmacokinetic parameters of corneal intrastromal injection. Future studies in this model system could help determine the appropriate concentrations for intrastromal injection depending on infectious status.

Conclusion

In conclusion, to the best of our knowledge, this is the first study to demonstrate safe concentrations of PHMB and propamidine isethionate for corneal intrastromal injection in rabbit eyes. *In vivo* and *in vitro* studies suggest that intrastromal injection of 0.1 mL of 0.01% PHMB or 0.05% propamidine isethionate is safe for the corneas. These parameters should be tested in an animal model of AK to evaluate the effectiveness of treatment. Moreover, propamidine isethionate has a relatively low toxicity and could be considered for intrastromal injection in deep recalcitrant AK before further evidence is found.

Compliance with ethics requirements

All Institutional and National Guidelines for the care and use of animals (fisheries) were followed.

Acknowledgement

Financial support: Supported by Grants MOST 108-2628-B-006-010.

Declaration of Competing: The authors have no conflicts of interest to declare.

Author contributions: ICP, and YHH involved in design and conduct of study. Collection and management of the data were done by CCL, YHH, and ICP. CCL and YHH participated in management and interpretation of the data. CCL, ICP and YHH participated in preparation, review, and approval of the manuscript.

References

- [1] Naginton J, Watson PG, Playfair T, McGill J, Jones B, Steel AMcG. Amoebic infection of the eye. *Lancet* 1974;iii:1537–40.
- [2] Lorenzo-Morales J, Khan NA, Walochnik J. An update on *Acanthamoeba* keratitis: diagnosis, pathogenesis and treatment. *Parasite* 2015;22:1–20.
- [3] Illingworth CD, Cook SD, Karabatsas CH, Eady DL. *Acanthamoeba* keratitis: risk factors and outcome. *Br J Ophthalmol* 1995;79:1078–82.
- [4] Papa V, Rama P, Radford C, Minassian DC, Dart JKG. *Acanthamoeba* keratitis therapy: time to cure and visual outcome analysis for different anti-amoebic therapies in 227 cases. *Br J Ophthalmol* 2019. doi: <https://doi.org/10.1136/bjophthalmol-2019-314485>.
- [5] Elder MJ, Kilvington S, Dart JK. A clinicopathologic study of in vitro sensitivity testing and *Acanthamoeba* keratitis. *Invest Ophthalmol Vis Sci* 1994;35:1059–64.
- [6] Lin IH, Tseng SH, Huang FC, Huang YH. Effect of ethanol pretreatment in *Acanthamoeba* keratitis: a long-term follow-up study. *Infect Drug Resist* 2018;11:937–43.
- [7] Sharma N, Agarwal P, Sinha R, Titiyal JS, Velpandian T, Vajpayee RB. Evaluation of intrastromal voriconazole injection in recalcitrant deep fungal keratitis: case series. *Br J Ophthalmol* 2011;95:1735–7.
- [8] Kalaiselvi G, Narayana S, Krishnan T, Sengupta S. Intrastromal voriconazole for deep recalcitrant fungal keratitis: a case series. *Br J Ophthalmol* 2015;99:195–8.
- [9] Nejabat M, Yaqubi N, Khosravi A, Zomorodian K, Ashraf MJ, Salouti R. Therapeutic effect of intrastromal voriconazole, topical voriconazole, and topical natamycin on fusarium keratitis in rabbit. *J Ophthalmol* 2016;8692830:1–6.
- [10] Prakash G, Sharma N, Goel M, Titiyal JS, Vajpayee RB. Evaluation of intrastromal injection of voriconazole as a therapeutic adjunctive for the management of deep recalcitrant fungal keratitis. *Am J Ophthalmol* 2008;146:56–9.
- [11] Moon EK, Kim SH, Hong Y, Chung DI, Goo YK, Kong HH. Autophagy inhibitors as a potential anti-amoebic treatment for *Acanthamoeba* keratitis. *Antimicrob Age Chemother* 2015;59:4020–5.
- [12] Chindera K, Mahato M, Sharma AK, Horsley H, Kloc-Muniak K, Kamaruzzaman NF, et al. The antimicrobial polymer PHMB enters cells and selectively condenses bacterial chromosomes. *Sci Rep* 2016;6:23121.
- [13] Siddiqui R, Aqeel Y, Khan NA. The development of drugs against *Acanthamoeba* infections. *Antimicrob Age Chemother* 2016;60:6441–50.
- [14] Huang P, Tepelus T, Vickers LA, Baghdasaryan E, Huang J, Irvine JA, et al. Quantitative analysis of depth, distribution, and density of cysts in *Acanthamoeba* keratitis using confocal microscopy. *Cornea* 2017;36:927–32.
- [15] Huang FC, Shih MH, Chang KF, Huang JM, Shin JW, Lin WC. Characterizing clinical isolates of *Acanthamoeba castellanii* with high resistance to polyhexamethylene biguanide in Taiwan. *J Microbiol Immunol Infect* 2017;50:570–7.
- [16] Shi L, Stachon T, Seitz B, Wagenpfeil S, Langenbacher A, Szentmary N. The effect of anti-amoebic agents on viability, proliferation and migration of human epithelial cells, keratocytes and endothelial cells, in vitro. *Curr Eye Res* 2018;43:725–33.
- [17] Huang FC, Liu TS, Li SC, Shih MH, Shin JW, Lin WC. The effect of the disulfide isomerase domain containing protein in the defense against polyhexamethylene biguanide of highly tolerant *Acanthamoeba* at the trophozoite stage. *Int J Parasitol Drugs Drug Resist* 2016;6:251–7.