

CONGENITAL ANOMALIES IN NATIVE BREEDS OF SHEEP AND GOATS: A REPORT ON 120 CASES OF 24 VARIETIES

**N.A. SENNA, A.M. ABU-SEIDA, S.M. GADALLAH, INAS N. EL-HUSSEINY
and G. M. RAKHA ***

Department of Surgery, Anaesthesiology and Radiology, Fac. Vet. Med., Cairo Uni. Giza.

* Department of Internal Medicine and Infectious diseases, Fac. Vet. Med., Cairo Uni., Giza.

Received: 8.3.2003.

Accepted: 10.4.2003.

SUMMARY

Among 1428 examined native breeds of sheep (658) and goats (770) during the period from August 2000 to February 2003, the incidence of congenital anomalies was 8.4%. The prevalence was higher in sheep (9.4 %) than in goats (7.5 %). Local Osemi sheep breed and mixed goats breed showed the highest incidence. Twenty-four patterns of congenital anomalies were diagnosed with predomination of pelvic and perineal regions. Congenital anomalies of the urogenital and digestive systems showed the highest incidence than those of other body systems. The recorded congenital anomalies were reviewed and discussed. Accurate diagnosis and surgical management were found helpful in the correction of some congenital anomalies in sheep and goats.

INTRODUCTION

Congenital anomalies are structural or functional abnormalities present at birth. These anomalies may result in fetal deaths: intra-uterine fetal death, abortion and still-birth or decreased economic value. They may affect a part of body system, whole system or parts of several systems (Dennis and Leipold, 1976 & 1979; Roberts, 1986; Saperstein, 1993; Radostitis, et al., 2000). Definitive etiology of congenital anomalies in small ruminants is unknown, however, during gestation, genetic, environmental (toxic, infectious and nutritional) or inherited factors were suggested to be the causes (Saperstein et al., 1975; Basrur and Yadav, 1990; Radostitis, et al., 2000).

Many varieties of congenital anomalies have been reported (Binns, et al., 1972; Dennis and Leipold, 1976 & 1979; Dennis, 1979; Hawkins et al., 1983; Roberts, 1986; Gohar, et al., 1987; Soliman et al., 1987 a&b & 1988; Bauomy, 1988; Ragab, 1989; Attia and Ismail, 1990; Harper, et al., 1990; Ramadan, 1991; Ladds, 1993; Leil, 1993; Doherty et al., 2000; Farghali, 2001) in sheep and (Gidding, 1976; El-Hariri and Shawki, 1980; Roberts, 1986; El-Keicy and Abdel-Hamid, 1987; Makady et al., 1987; Kenawy, 1988; Ragab, et al., 1988; Basrur and Yadav, 1990; Panter, et al., 1990; Ramadan, 1994&1996; Karras, et al., 1992; Basrur, 1993; Kaneps, 1996; Ramadan et al., 1998; Berbish et al., 2000; Newman, et al., 2000) in goats.

The aim of the present study was to elucidate the encountered patterns of congenital anomalies and their surgical management in native breeds of sheep and goats.

MATERIAL AND METHODS

A total number of 1428 native breeds of sheep (658) and goats (770) were under their routine clinical examinations in the clinics of Surgery and Internal Medicine Clinics, Fac. of Vet. Med., Cairo Uni., Giza, and in three private farms (in Al-Fayoom and EL-kaliobia provinces, Egypt) during the period from August, 2000 to February,

2003. The examined animals were traced for the existence of congenital anomalies. The age of the examined animals ranged between one day and one year old. They were of both sexes (Tab. 1).

Diagnosis of the congenital anomalies depended upon anamnesis, observations, clinical and radiological examinations. Tabulation of congenital anomalies was according to topographic regions (head, neck, thorax, abdomen, pelvis, perineum and limbs) and body systems. Arthrogyrosis of both carpi was graded according to Doherty et al., (2000).

Anaesthesia of the operated cases (atresia ani, atresia ani and associated fistulae, different types of hernias, and urethral dilatation) included IM Rompun (Bayer), when needed, at a dose rate of 0.05-0.22 mg/kg b.wt. associated with local infiltration and/or lumbosacral epidural analgesia using Xylocaine HCl 2% solution (Astra Sodertalje, Sweden). Surgical management of the operated cases were performed according the techniques described by Wright, (1963); Oehme and Prier, (1976); Aanes, (1980); Jennings, (1984); Ragab, (1989); El-Sayad, (1991) and Gadallah, (1995). Cases with large abdominal hernial defects were surgically treated by prosthetic herniorrhaphy using commercial polyester fabric (C.P.F.) (Shokry et al., 1997).

Tab. 1: Breed and sex of the examined sheep and goats.

Species/Number	Breed				Sex		Total
					Males	Females	
Sheep (658)	Osemi 411	Rahmani 82	Barki 70	Mixed 95	245	413	658
Goats (770)	Zaraibi 90	Damascus 50	Mixed 630		340	430	770

RESULTS

Animals with congenital anomalies represented 8.4 % of the examined sheep and goats (1428). The incidence among the examined sheep (658) and goats (770) were 9.4% and 7.5% respectively. The age of high incidence in the affected sheep (32 / 50.0 %) and goats (33 / 56.9%) was

found between 1-7 days old.

Osemi sheep and mixed breed goats showed the highest incidence of the total diagnosed anomalies (62.9% and 82.7%) respectively. Out of the affected sheep (41 / 66.1%) and goats (46 / 79.3%) were males (Tab. 2).

Tab. 2: Incidence of congenital anomalies in sheep and goats according to breeds and sex

Species/Number	Breed				Sex		Total
					Males	Females	
Sheep (62)	Osemi (62.9%)	Rahmani 11(17.7%)	Barki 5 (8.1%)	Mixed 7 (11.3%)	41 (66.1%)	21 (33.9%)	62 (100%)
Goats (58)	Zaraibi 7 (12.1%)	Damascus 3 (5.2%)	Mixed 48 (82.7%)		46 (79.3%)	12 (20.7%)	58 (100%)

Table 3 showed the incidence of the diagnosed congenital anomalies in different body regions of sheep and goats. Congenital anomalies of pelvic and perineal regions represented the predominant ones (82 / 68.3%) followed by anomalies of head and neck (16 / 13.3%), thorax and abdomen (16 / 13.3%) and appendicular skeleton (6 / 5.0%).

Among 24 diagnosed patterns of congenital anomalies, urogenital and digestive systems anomalies represented the most common cases (49 / 40.8% and 32 / 26.7% respectively). Urogenital system defects were greater by triple folds in goats (37 / 75.5%) than in sheep (12 / 24.5%) cases. Digestive system defects were greater by two folds of total sheep cases (21 / 33.9%) than

Tab. 3: Congenital anomalies of different body regions of sheep and goats.

Body regions	Sheep	Goats	Total
Head & neck:	10	6	16 (13.3%)
Thorax & abdomen	15	1	16 (13.3%)
Pelvis & perineum	36	46	82 (68.3%)
Appendicular skeleton	1	5	6 (5.0%)
Total	62 (51.7%)	58 (48.3%)	120 (100%)

in goats (11 / 18.9% of the total goats cases). Out of 111 affected cases of sheep and goats, 9 of them showed two main congenital anomalies.

Congenital anomalies of the head and neck

Exencephaly (defective cranium with brain exposure) (one case)

A three-day-old female mixed breed kid was unable to stand and showed exencephaly characterized by cranioschisis (5x7cm). The brain tissues were exposed through this defective cranium (cranium bifidum) but without prolapse. No other body abnormalities were observed in that kid. The radiographic images showed concave, radiolucent cranial defect in the parietal bones and the rostral neural tube (Fig.1). This kid died two days later.

Cyclopic deformities (one case)

A complete alopecic stillbirth female mixed breed kid had several head deformities. The left ear was hard limb-like shape and the right one was relatively long. The kid had unilateral anophthalmia; one eye with bluish cloudy cornea was

centrally located (cyclopia) with fissured lower eyelid, the nostrils and nasal cavity were absent. The lower jaw was curved upward, longer 5 cm than the upper compact one (prognathism). There were two prominent incisors on the lower jaw and the tongue protruded centrally (Fig. 2).

Micro-otia (absence of the concha) (7 cases)

The concha of both ears was absent in seven Osemi sheep (11.3%) of the total cases.

Torticollis (wry neck) (2 cases)

Two male Osemi lambs were born with twisted neck. The neck showed curved stiff bending and muscle contraction. There was malformation in the proximal cervical articulation. One lamb was found with an excessive flexion of the right carpus. The radiographic investigation showed atlanto-axial subluxation (Fig. 3).

Tassel (wattle) cysts (5 cases)

This defect was diagnosed in the tassels of one Osemi lamb and a mixed breed kid (unilateral swelling) and in 3 mixed breed kids (bilateral

swellings). The size of swellings ranged between lemons to orange sizes causing degrees of mechanical hindrance to head movement. These fluctuating swellings contained straw yellow serous-like fluid except for one infected, which had purulent material. Contrast radiographic images

(Fig.4) showed a round swelling (average 5x5 cm), which had no connection with any structures. The affected animals overcame the mechanical head hindrance after surgical excision of these cysts.

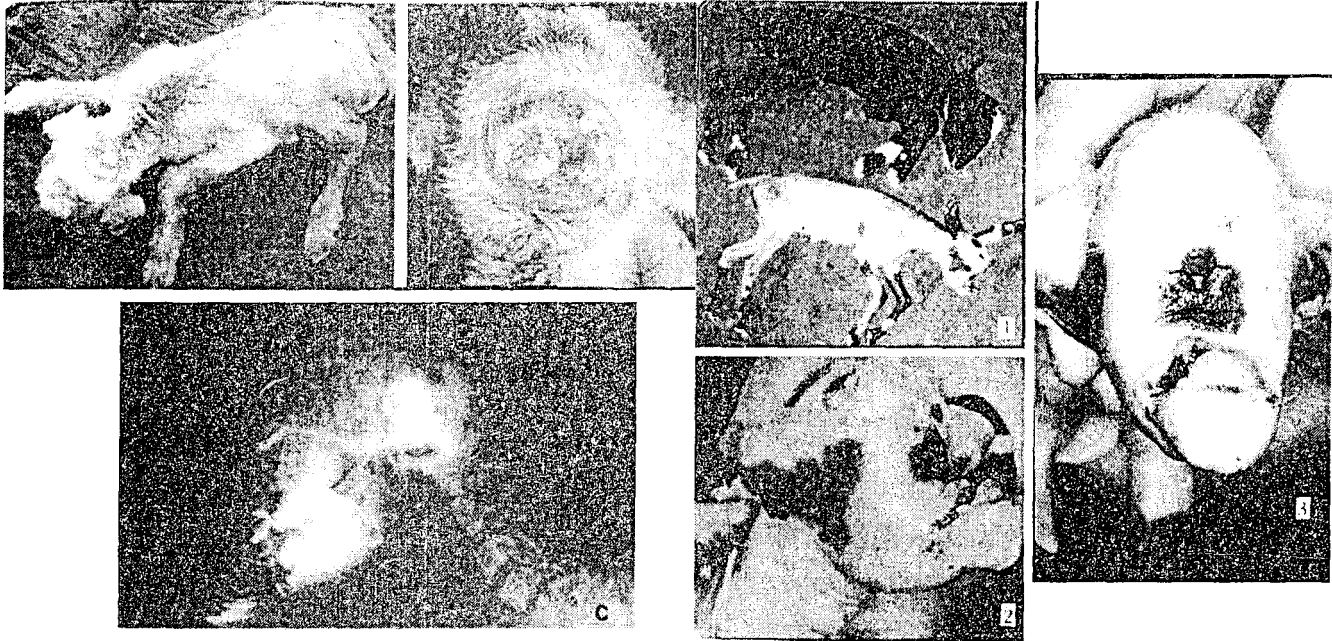


Fig.1: Exencephaly in 3-day-old kid (a&b)The radiographic image shows a concave radiolucent cranial defect in the parietal bones and the rostral neural tube (c).

Fig.2: Cyclopan deformities; note complete alopecia, ear deformities, prognathism (1&2). anophthalmia with the other eye centrally located (3).

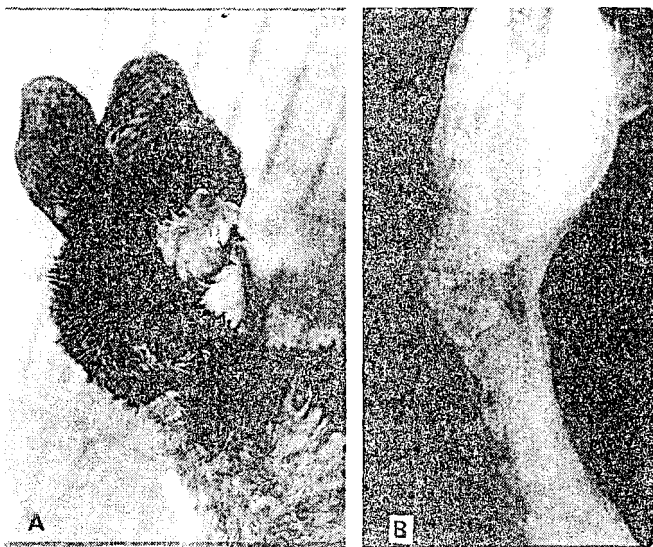


Fig.3: Torticollis in an Osemi lamb, note the marked deviation of the neck(A). (B): An x-ray image shows atlanto-axial subluxation.

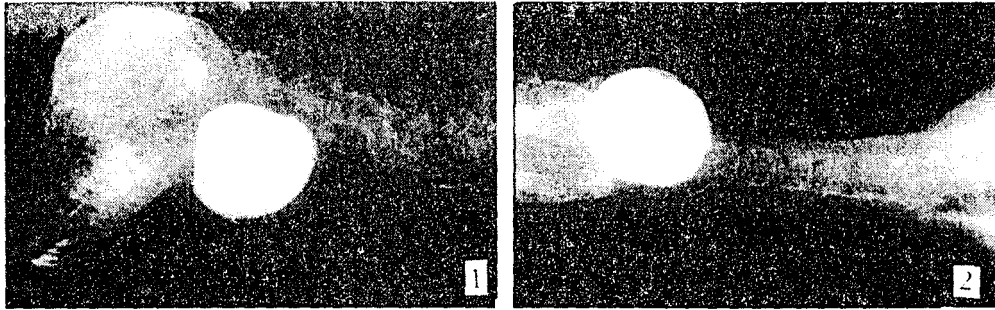


Fig. 4: Lateral and ventro-dorsal contrast radiographic images of a unilateral tassel cyst in an Osemi lamb (1&2).

Congenital anomalies of the thorax and abdomen

Ectopic heart (ectopia cordis pectoralis) (one case)

A pulsating swelling was palpated, pre-sternally, outside the chest in a three-day-old male Osemi lamb. The lamb showed dyspnoea and stood with slight abduction. The ectopic heart appeared normal in its anatomical features, strangulating through the sternum and beating regularly. No other abnormalities were found in this lamb. The radiographic examination revealed an abnormal conformation of the chest, the heart was protruded through a defective unfused sternum and the lung lacks the cardiac notch (Fig.5). Two days later, the lamb died.

Epitheliogenesis imperfecta with visceral eversion at umbilicus (2 cases)

Two cases (two-day-old females mixed breed lamb and kid) were born with a portion of small intestine and omentum prolapsed at the umbilical region. These cases showed general weakness and had a slit-like opening (2x3 cm) devoid of

skin at the umbilical region. The prolapsed parts were surgically reduced as usual (Fig.6).

Umbilical hernias (4 cases)

Eight lambs (four Osemi, two Rahmani and two mixed breed) represented 1.2% of the total examined sheep (658) and 12.9% of the total diagnosed cases (62) had umbilical hernias. Soft, fluctuating and painless reducible swellings of different sizes (lemon to water-melon size) were detected. The hernial rings ranged in diameter between one to three fingers. At surgery, the intestine / omentum were the contents. Open reduction was carried out and recovery was uneventful in all operated cases (Fig.7).

Ventral abdominal hernias (5 cases)

Ventral abdominal hernias were diagnosed in five lambs (8.1%) of the total cases (62). The hernial sacs varied in sizes between an orange to a child-head size (Fig.7) and extended laterally in two cases. The diameter of hernial rings ranged between two fingers and two handbreadth. The hernial contents were reducible in all cases. In two

cases with large ventral abdominal hernial defects, prosthetic herniorrhaphy using commercial polyester fabric and the external hernial sac as

flap was successfully performed. All operated cases recovered without complications or recurrences.




Fig. 5: Ectopic cordis pectoralis in a 3-day-old male Osemi lamb (1). Lateral and ventro-dorsal radiographic images show the ectopic heart protruding through a thoracic defect (2&3).




Fig.6: Epitheliogenesis imperfecta with omental prolapse in a kid (A) and intestinal eventration a lamb (C). The same cases after operations (B & D).

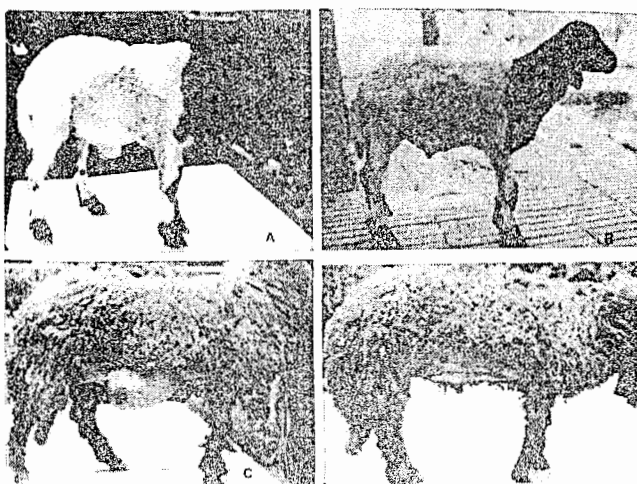


Fig. 7: Umbilical (A) and ventral abdominal (C) hernias in sheep. The same cases after operations (B & D).

Congenital anomalies of the pelvis and perineum

Urethral dilatation (25 cases)

Twenty-five kids (43.1%) of the total cases (58) and six lambs (9.7%) of the total cases (62) were presented with a history of dysurea. There were dilatations of the urethra extending at variable distances between the scrotum and the free portion of the penis. These painless, fluctuating dilatations took different sizes (small bean or duck's egg size) and might be divided into compartments (Fig.8). Urine dribbles from the tip of the penis by pressure on these diverticuli was noticed. In three affected kids, double scrotum were also observed. Recovery was uneventful after surgery.

Scrotum bifidum (Bifid scrotum; double scrotum) (5 cases)

Double scrotums, complete scrotal bifurcations, was diagnosed in five mixed breed kids. Urethral dilatation was associated with three of them (Fig.9a). Diagnosis of three cases was by coincidence during examination for castration.

Ectopic testicles (cryptorchidism) (2 cases)

Subcutaneous abdominal ectopic testicles (unilateral and bilateral) were diagnosed in 2 mixed breed kids. These cases were referred of castration. Ectopic testicles were surgically removed (Fig.9b &10).

Abnormalities of the penile length and situation (4 cases)

The penis was ended at the level of the scrotum

in two mixed breed kids and post-scrotal situation in the other two cases. In two affected kids, double scrotums were also noticed (Fig.9 c & d).

Scrotal hernia (7 cases)

Four Rahmani and three Osemi rams had scrotal hernias. The swelling filled the scrotum totally (Fig.11). Open reductions of the prolapsed omentum / intestine with castration in 5 cases and without castration in 2 cases were performed.

Inguinal hernia (3 cases)

Three female Barki lambs suffered from unilateral reducible inguinal hernias. The hernial contents were omentum and a portion of intestine. Herniorrhaphy was performed with success (Fig.12).

Atresia ani (25 cases)

This anomaly was diagnosed in 15 newly born male lambs (24.2% of 62 total cases) and 10 male kids (17.2% of 58 total cases). Artificial orifices were surgically created.

Atresia ani with rectovaginal fistula (4 cases)

Faeces and urine came from vulva through the vagina in four female lambs. No anal openings were found (Fig.13a). Vaginal examination revealed the presence of fistulous tracts (one to two fingers in diameter) at varying distances from the vulva (3-5 cm). Reconstruction of the perineal area, creation of an anal opening, repairing of the ventral rectal wall was performed successfully in all cases.

Rectal fistula into the fatty tail (one case)

A one-month-old female Osemi lamb showed swelling in the fatty tail since birth. The swelling was increasing in size gradually while the general condition was good. The lamb had an anal opening. The fatty tail was swollen and doughy in

consistency. By exploratory puncture a green, watery, offensive fluid was aspirated. Surgical reconstruction of the perineal area, repairing of the dorsal rectal wall and amputation of the fatty tail were performed (Fig.13 b, c & d).

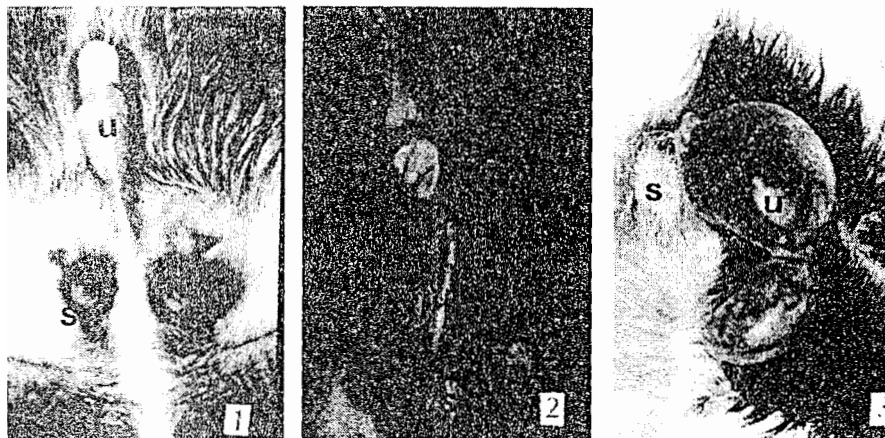


Fig.8: kids with urethral dilatations (u) (1) of different sizes (2) or with compartmental divisions (3) and scrotum bifidum (s) in all kids.

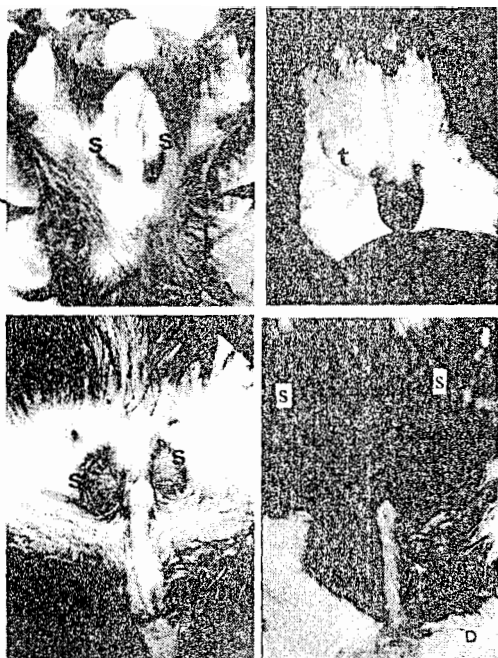


Fig.9: Kids with scrotum bifidum (S) (a.c&d), unilateral ectopic testicle (t) (B), scrotal and post-scrotal termination of the penis (c&d).

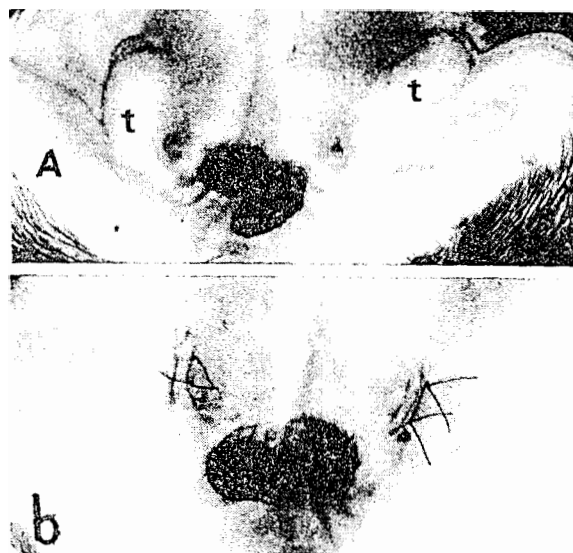


Fig10: Bilateral ectopic testicles (t) in a kid(A). The same case after operation (b).



Fig.11: Scrotal hernias of different sizes in sheep. Note the hernial sac reach the ground (3) and after operation (4).

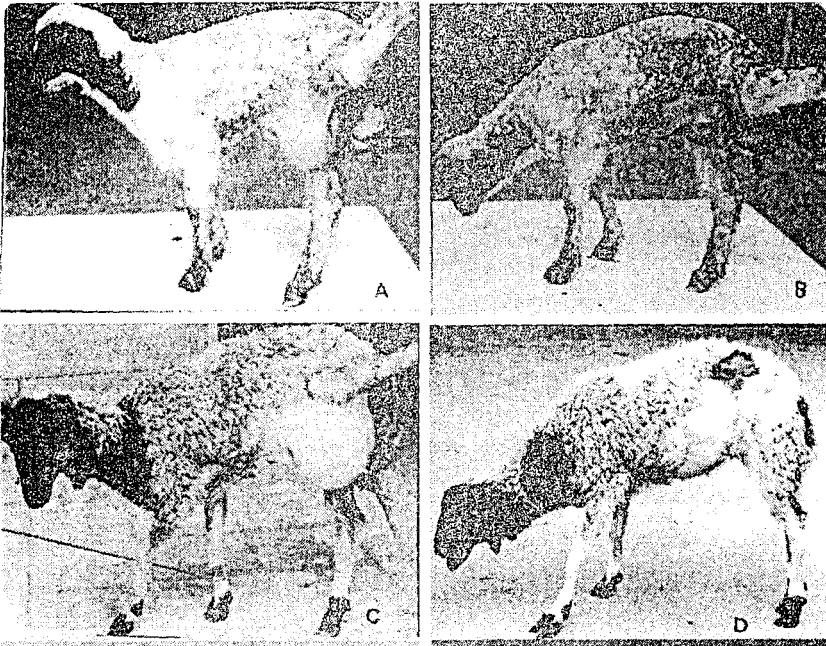


Fig.12: Inguinal hernias in female lambs (A&C). The same cases after operations (B&D).

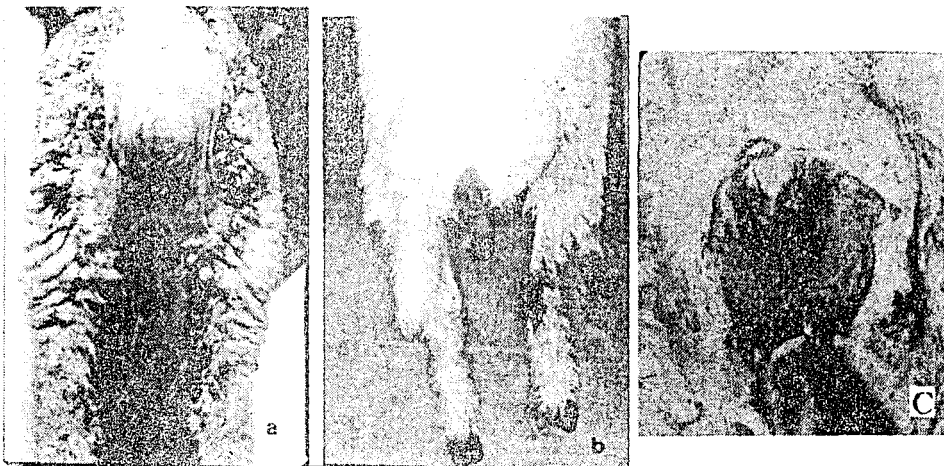


Fig.13: Atresia ani and recto-vaginal fistula in a 2 month-old female lamb (a). Rectal fistula into fatty tail and surgical repair (b&c).

Appendicular anomalies

Unilateral tibial hemimelia with ventral abdominal hernia (one case)

A three-week-old female Osemi lamb supported its weight on three limbs. Standing was difficult and recumbency was frequent. The right femur was present normally while the tibia/fibula were found rudimentary in size. The rest of limb; tarsus, metatarsus and phalanges were missed. Also, there was reducible ventral abdominal hernia (child-head size and five fingers hernial ring) (Fig.14) that was managed surgically. The lamb was fattened and slaughtered six months later.

Unilateral carpal flexion (one case)

In a three-week-old Osemi lamb, the right carpus showed flexion rigidity. There was difficulty in passive extension of the limb. This lamb showed also torticollis (Fig.15).

Arthrogryposis (crooked joints) (2 cases)

Twins mixed breed female kids (one-month old) showed bilateral flexion rigidity of both carpi with outward rotation of forelimbs. The condition was severe in one kid and moderate in the other one (Fig.16). Passive extension of the limbs was difficult. Both cases were alert, fed normally and had no neurogenic abnormalities.

Femoral bending, scoliosis and ventro-lateral abdominal hernia (one case)

A four-week-old female mixed breed kid with lateral deviation of the right hind limb and medial deviation of the left one. The kid suffered also

ventro-lateral abdominal hernia. It was unable to stand normally. X-ray examination revealed right pelvic / sacral deviation, left hip subluxation (flattening / lipping of left acetabulum) and right femoral deformity (diaphyseal bending) (Fig.17).

Angular limb deformities (one case)

A three-week-old male mixed breed kid showed angular limb deformities. Hind limbs were abducted, placed in back position and showed bilateral metatarso-phalangeal valgus deformities. All joints (stifle, hock and digital joints) were severely extended. The radiographic image revealed medial deviation of both hock joints (Fig.18).

Hip subluxation, joint laxity, tibial/ fibular agenesis and polydactyly (one case)

A 14-day-old female mixed breed kid was unable to bear weight on both hind limbs and showing frog-sitting posture. It was possible to move both hind limbs, passively, in all directions. Both stifle joints were flexed and the planter aspect of both hocks were touching the ground in severe extension. Polydactyly (supernumerary digit) were seen in both hind limbs. The radiographic investigations showed bilateral hip subluxation (flattening and lipping of acetabular margins), bilateral absence of tibia and fibula (agenesis)(replaced by a rudimentary bone) and malformation in both hocks. The large metatarsal bone (Mt III and IV) and lateral small one (Mt V) were well developed (Fig.19).

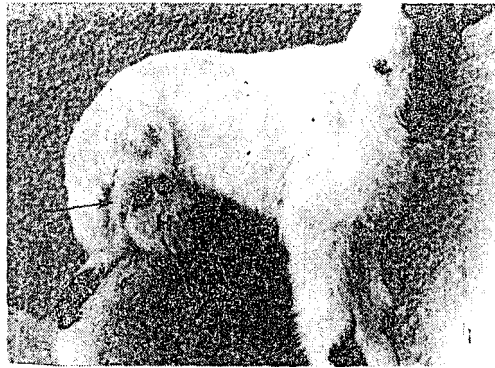


Fig.14: Unilateral tibial hemimelia with ventral abdominal hernia (H) in 3-week-old female Oseme lamb. The right femur is normally present but the right tibia is malformed.




Fig.15: Unilateral carpal flexion and torticollis in a 3-week-old Oseme lamb.



Fig.16: Twins mixed breed female goats show bilateral carpal flexion rigidity.


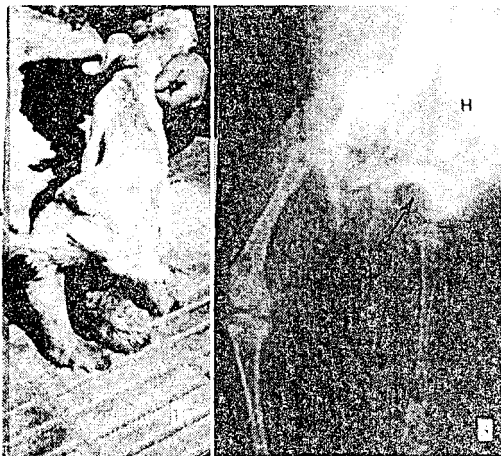


Fig.17: Femoral bending, scoliosis and ventrolateral abdominal hernia (H) in a 4-week-old kid (1&2). X-ray image shows multiple appendicular deformities (3).



Fig.18: A three-week-old male kid shows angular limb deformities (1&2). X-ray image shows medial deviation of both hocks (3).

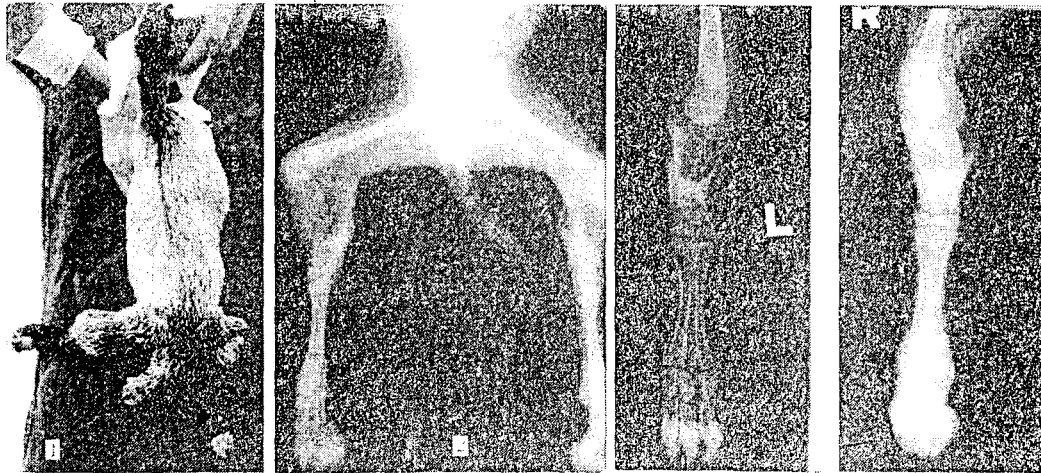


Fig.19: A 14-day-old female kid with hip subluxation, joint laxity, tibial/ fibular agenesis and polydactyly (arrows).

DISCUSSION

In the present work, the incidence of congenital anomalies among the examined native breed of sheep and goats was 8.4%. It was higher in sheep (9.4 %) than in goats (7.5 %). Contrary to a previous study (Leil,1993) who found that the incidence was higher in goats (50 / 4.5% of 1100 examined goats) than in sheep cases (13 / 0.9% of 1400 examined sheep). Anyhow, such incidences may reflect the economic importance of congenital anomalies regarding these food animals (Saperstein et al., 1975 and Dennis and Leipold, 1976 & 1979; Leil,1993; Radostitis, et al., 2000).

In spite of the fact that congenital anomalies present at birth, some of them assumed their clinical importance later on. Scrotal and ventral abdominal hernias, ectopic testicles, scrotum bifidum, rectovaginal fistulae and rectal fistula into

the fatty tail did not attract the owner's attention until castration or mating (Ragab, 1989) or numbering of sheep (micro-otia).

Data taken from farm's records, rather than sporadic cases, are incomplete to follow the possible teratogens / cross mating. Such problems were also reported by Dennis, et al., (1975); Ojo, et al., (1981); Nigam, et al., (1984). However, most of the anomalies reported here could be due to the interaction between genetic and environmental (toxic, infectious and nutritional) factors.

Classification of congenital anomalies was according to the affected topographic region and body systems. It was found that nine cases showed more than one congenital anomalies. However, there are other tabulations according to teratogenic and chromosomal aberrations (Saperstein et al., 1975).

Osemi sheep and mixed breed goats showed the highest incidence of congenital anomalies. This may be due to the prevalence of such breeds among the examined animals. On the other hand, Barki sheep and Damascus goat as they showed the lowest incidence of congenital anomalies.

Most of the affected sheep and goats were males. A similar findings was documented by Nigam, et al., (1984).

In the present work, congenital anomalies of pelvic and perineal regions represent the most predominant ones followed by those of head and neck. In this respect, Leil, (1993) reported that head and neck anomalies showed the highest incidence. Regarding body systems, urogenital and digestive systems represented the most common ones. These findings were more or less in agreement with Ragab, (1989) however, musculoskeletal and digestive systems were greatly involved in a previous study (Dennis, 1975).

Urethral dilatation represented the most common anomaly in kids and it could be easily differentiated from ruptured urethra. However, the presented cases responded well to surgical interferences. These findings were more or less similar to those of (El-Keiey and Abdel-Hamid, 1987; Makady, et al., 1987; Bauomy,1988; Ragab, 1989; Karras, et al., 1992). Congenital termination of the penis at the level of the scrotum or

post-scrotal was also reported by Cohrs, (1970); Makady, et al., (1987); Ragab, (1989).

Atresia ani represented the most common defect in lambs and the second rank in kids. All cases of atresia ani were diagnosed in males while in females this condition was associated with recto-vaginal fistulae. In a previous study (Monzaly, 1974) found that the sex ratio of ano-rectal anomalies were 1:1 in lambs and 2 males: 1 female in kids. Early surgical creation of an anal opening was found adequate in these animals (El-Sheikh, 1979; Misk, et al., 1983&1985; Nigam, et al., 1984; kenawy, 1988).

In the present study, all types of hernias (umbilical, ventral abdominal, inguinal and scrotal) were diagnosed in sheep. In a previous study (Gohar et al., 1987) found that the incidence of congenital umbilical hernias was higher in goats than in sheep. In cattle, the inbreeding coefficient and chromosomal analysis indicated recessive inheritance of all previous types of hernias (Hayes, 1974; Takahashi, et al., 1993 and Bisla and Bhaskar, 1996).

According to Cohrs, (1970), non-closure of the cranial portion of the neural tube and failure of cranial development resulted in defective cranium (cranioschisis) with exposed brain (exencephaly). On the other hand, the present cyclopiam deformities in a stillbirth goat kid is a rare

condition (Ali et al., 1987). A more or less similar to these cycloplan deformities were induced by feeding pregnant goats on roots and leaves of *Veratrum californicum* (Binns, et al., 1972).

Ectopia cordis pectoralis is a very rare anomaly in sheep. A case of primitive ectopia cordis fissisternalis was reported in a newborn goat kid (Hago et al., 1992). However, ectopia cordis cervical is relatively common in cattle (Gopal et al., 1986; Ragab, 1993; Reef and McGuirk, 1996; Jackson and Slater, 1997) and in pigs (Jubb, et al., 1993). The original defect is probably due to closure malformation of the thorax. These observations were in agreement with those of (Else, 1980; Reef and McGuirk, 1996; Jackson and Slater, 1997; Radostitis, et al., 2000).

Tibial hemimelia was diagnosed in an Osemi female lamb. The right tibia / fibula were much reduced in size while the tarsus, metatarsus and phalanges were missed. Such defects were recorded in goats (Gidding, 1976; El-Hariri and Shawki, 1980; EL-Mezyen et al., 1992), sheep (Hawkins et al., 1983; Ramadan, 1991) and cattle (Lapointe, et al., 2000).

Arthrogryposis and unilateral carpal flexion were diagnosed in twins goat kids and in a lamb. In this respect, ovine arthrogryposis was inherited through an autosomal recessive gene (Dennis and Leipold, 1979; Doherty et al., 2000). However, Panter, et al., (1990) reported that congenital

multiple skeletal contractures and cleft palate was induced in goats by ingestion of *Lupinus* and *Nicotiana* species. The present defective twins showed no neurogenic abnormalities so, the condition could be myogenic in origin (Hulland, 1993).

Congenital angular limb deformities may be caused by incomplete carpal / tarsal cuboidal bone ossification, uterine mal-positioning, or nutritional imbalance during gestation (Binns, et al., 1972; Baird et al., 1994; Smith and Sherman, 1994; Kaneps, 1996).

In conclusion, accurate diagnosis and surgical management were found helpful in the correction of some congenital anomalies in sheep and goats.

REFERENCES

- Aanes, W.A.,(1980): Herinorrhaphy. In: *Bovine Medicine and Surgery*, Vol. II, 2nd. Ed., Am. Vet. Publ., pp:1221.
- Ali, M.A., Misk, N.A. and Hifny,A., (1987): Congenital abnormalities at the head of a newly born goat. *Assiut Vet. Med. J.* 18 (36): 189-190.
- Attia, M. and Ismail, S.F.,(1990): Acrania in a sheep-lamb. *Assiut Vet. Med. J.* 23 (46): 249-251.
- Baird A.N., Wolfe, D.F., Bartels, J.E. and Carson, R.L., (1994): Congenital mal-development of the tibia in two calves. *J.A.V.M.A.*, 204 (3): 422-423.
- Basrur, P.K. (1993): Congenital abnormalities of the goat. *Vet. Clin. North Am. Food Anim. Pract.* 9 (1): 183-202.

- Basrur, P.K. and Yadav, B.R.,(1990): Genetic diseases of sheep and goats. *Vet. Clin. North Am. Food Anim. Pract.* 6 (3): 779-802.
- Bauomy, A.I.A.,(1988): Prevalent surgical affections in sheep and goats in Behira province. M. V. Sc. Thesis, Fac. Vet. Med., Alex. Uni.
- Berbish. E.A., Rahka, G. M., Senna, N.A., and Shalaby, A.A.,(2000): Congenital goiter in goat kids: Diagnosis and surgical management. *Vet. Med. J.* 48(3): 413-423.
- Binns, W., Keeler, R.F. and Balls, L.D.,(1972): Congenital deformities in lambs, calves and goats resulting from maternal ingestion of *Veratrum californicum*: harelip, cleft palate, ataxia and hypoplasia of metacarpal and metatarsal bones. *Clinical-Toxicology*, 5 (2): 245-261.
- Bisla, R.S. and Bhaskar, V.V.,(1996): Congenital ventral hernia and its surgical management in a crossbred calf - a case report. *Indian Vet. J.*, 73: (9): 977-978.
- Cohrs, P., (1970): Textbook of special pathological anatomy of domestic animals. By Nieberle and Cohrs, Pergamon Press, Oxford.
- Dennis, S.M.,(1975): Perinatal lamb mortality in Western Australia. VII. Congenital defects. *Aust. Vet. J.*: 80-82.
- Dennis, S.M.,(1979): Hypospadias in merino lambs. *Vet. Rec.*, 4: 94-96.
- Dennis, S.M. and Leipold, H.W.,(1976): Diagnosing congenital defects in sheep. *Zuchthygiene*, 11 (3) :105-112.
- Dennis, S.M. and Leipold, H.W.,(1979): Ovine congenital defects. *Vet. Bull*, 49 (4): 233-239.
- Doherty, M.L., Kelly, E.P., Healy, A.M., Callanan, J.J., Crosby, T.F., Skelly, C. and Boland, M.P., (2000): Congenital arthrogryposis: an inherited limb deformity in pedigree Suffolk lambs. *Vet. Rec.*, 146(26): 748-753.
- EL-Mezycn, A.F., Kandecl, A. and Abd-Rabou, M. A., (1992): Hemimelia with congenital scrotal hernia in a lamb. *Egypt. J. Appl. Sci.*,7 (4): 888-895.
- Else, R.W., (1980): Clinico-pathology of some heart diseases in domestic animals. In: Scientific Foundation of Veterinary Medicine. Ed. By Phillipson, A.T, Hall, L.W. and Pritchard, W.R., 1st. ed., William Heinemann medical books limited. London.
- Farghali, H.A., (2001): Studies on udder affections of small ruminants. M. V. Sc. Thesis, Fac. Vet. Med., Cairo Uni. Giza.
- El-Hariri, M.N.E. and Shawki, H., (1980): Amelia and hemi-melia in two goats. *J. Egypt. Vet. Med. Ass.* 40 (4): 89-98.
- El-Keiey, M.T. and Abdel-Hamid, M.A., (1987): Congenital anomalies of the urethra in male goats. *J. Egypt. Vet. Med. Ass.* 47 (3): 671-676.
- El-Sayad, G.A.A., (1991): Surgical studies on the common affections of the abdominal region in some farm animals. M. V. Sc. Thesis. Fac. Vet. Med. Alex. Univ.
- El-Sheikh, A.H., (1979): Atresia ani among newly born camels. *Zagazig Vet. J.*, II: 193-207.
- Gadallah, S., M.,(1995): Surgical management of hernial rings in animals: Experimental and clinical studies. M.V.Sc. Thesis, Fac. Vet. Med., Cairo Uni. Giza.
- Gidding, R.F.,(1976): Tibial agenesis in a toggenburge kid. *JAVMA*, 169:1306-1307.
- Gopal, T., Leipold, H.W., and Dennis, S.M., (1986): Congenital cardiac defects in calves. *Am. J. Vet. Res.*, 47: 1120-1121.
- Gohar, H.M., Ramadan, R.O., and Moghal, H.,(1987): Umbilical and abdominal hernias in ruminants. *J. Egypt. Vet. Med. Ass.*, 47 (1&2): 563-574.

- Hago, B.E.D., Lotfi, H.A., Abd EL Magied and Abu-Samra, M.T., (1992): Ectopia cordis in a goat. *Bull. Anim. Prod. Afr.*, 40:189-291.
- Harper, P., Plant, J.W. and Unger, D.B., (1990): Congenital biliary atresia and jaundice in lambs and calves. *Aust. Vet. J.*, 67 (5): 18-22.
- Hawkins, C.D., Skirrow, S.Z., Wybuen, R.S. and Howell, J. Mc., (1983): Hemimelia and low marking percentage in a flock of merino ewes and lambs. *Aust. Vet. J.*, 60: 22-24.
- Hayes, H.M., (1974): Congenital umbilical and inguinal hernias in cattle, horses, swine, dogs and cats: Risk by breed and sex among hospital patients. *Am. J. Vet. Res.*, 35 (6): 839-842.
- Hulland, T.J., (1993): Muscle and tendon. In: *Pathology of Domestic Animals*. Eds. Jubb, K.V.F., Kennedy, P.C., and Palmar, N., San Diego, Academic Press. pp: 198-201.
- Jackson, P. and Slater, J., (1997): Cardiovascular disease in cattle. In *practice*: 472-483.
- Jennings, P.B., (1984): *Practice of large animals surgery*. W.B. Saunders Co. Philadelphia.
- Jubb, K. V. F., Kennedy, P.C., and Palmar, A., (1993): *Pathology of Domestic Animals* 4th ed. Academic Press INC, Harcourt Brace Jovanovich Publ.
- Kaneps, A., (1996): Orthopedic conditions of small ruminants: Llama, sheep, goats and deer. *Vet. Clin. North Am.: Food Anim. Pract.* 12 (1): 211-231.
- Karras, S., Mondransky, P. and Welker, B., (1992): Surgical correction of urethral dilatation in an intersex goat. *J.A.V.M.A.*, 201 (10): 1584-1586
- Kenawy, A. A., (1988): Prevalent surgical affections of newly born farm animals with special reference to their treatment. PH.D. Thesis, Fac. Vet. Med. Alex. Univ.
- Ladds, P.W., (1993): Congenital abnormalities of the genitalia of cattle, sheep, goats and pigs. *Vet. Clin. North Am.: Food Anim. Pract.* 9 (1): 127-144.
- Lapointe J.M., Lachance, S. and Steffen, D.J., (2000): Tibial hemimelia, meningocele and abdominal hernia short-horn cattle. *Vet. Pathol.* 37 (5): 508-511.
- Leil, A.Z.A., (1993): Incidence of surgical affections among sheep and goats in Damietta province. M. V. Sc. Thesis, Fac. Vet. Med., Cairo Uni. Giza.
- Makady, F.M., Youssef, H.A. and Mahmoud, A., (1987): Some congenital anomalies of the penis in goat. *Assiut Vet. Med. J.*, 18 (36): 168-172.
- Misk, N.A., Bhargava, A.K. and Singh, G.R., (1983): Congenital sacral deformity, taillessness and atresia ani in a calf. *M.V.P.*, 64 (4): 312-314.
- Misk, N.A., Ali, M.A., and Youssef, H.A., (1985): Unusual swelling at the perineal region with atresia ani in a newborn calf. *Agri-Practice-Bovine Anatomy*, 6 (9): 25-27.
- Monzaly, M., EL-M., (1974): Ano-rectal anomalies in newly born sheep and goats. *Assiut Vet. Med. J. Vol. 1(1&2)*.
- Newman, S.J., leichner, T., Crisman, M. and Ramos, J., (2000): Congenital cystic disease of liver and kidney in a pygmy goat. *J. Vet. Diagn. Invest.*, 12(4): 374-378.
- Nigam, J.M., Misk, N. A. and Rifat, J. F., (1984): Surgical management of congenital anomalies of ruminants. *Agri-practice*, 5 (7): 38-47.
- Oehme, F.W. and Prier, J.E., (1976): *Textbook of large animals surgery*. Baltimore, Williams & Wilkins Co., U.S.A., pp: 445.
- Ojo, S.A., Biol, M.I. and Leipold, H.W., (1981): Epiphyseal chondrodystrophy in a neonatal Holstein Friesian calf. *J. Egypt. Vet. Med. Ass.* 41 (1): 5-10, 15th. Arab

- Vet. Congress, Panter, K.E., Keeler, R.F., Bunch, T.D., and Callan, R.J., (1990): Congenital skeletal malformations and cleft palate induced in goats by ingestion of Lupinus, Conium and Nicotiana species. *Toxicon*, 28 (12): 1377-1385.
- Radostits, O.M., Gay, C.C., Blood, D.C. and Hinchcliff, K.W., (2000): *Veterinary Medicine. A textbook of the diseases of cattle, sheep, pigs, goats and horses.* 9th ed. By ELBS with Bailliere Tindall.
- Ragab, G.A.,(1989): Some studies on the surgery of the urogenital system in small ruminants. Ph.D. Thesis, Fac. Vet. Med., Cairo Uni. Giza.
- Ragab, G.A.,(1993): Developmental abnormalities in buffalo-calves. *Egyptian J. Comparative Pathology and Clinical Pathology*, 6 (1); 207-209.
- Ragab, R.S.A., Scrur, B.H. and Eissa, H.M.,(1988): A case of schistosoma reflexus in a she goat. *Assiut Vet. Med. J.*, 20 (40): 192.
- Ramadan, R.O., (1991): Hemimelia and ectrodactyly in a Najdi sheep. *Accept. for Publ. in Agri-Practice* March,7 1991.
- Ramadan, R.O., (1994): Agenesis of the radius in a goat. *Agri-Practice*, 15: 33-34.
- Ramadan, R.O., (1996): A diccephalic goat with other defects of the radius in a goat. *Zentralbl. Veterinarmed.*43 (6):337-343.
- Ramadan, R.O., Gameel, A.A., Mohamed, G. E. E. AL-Hammadi. M.H. and AL-Kalifa, M.,(1998): Ectromelia and peromelia in goats in Saudi Arabia. *Pakistan Vet. J.*, 18 (20): 104-106.
- Reef, V.B. and McGuirk, S.M., (1996): Diseases of the cardiovascular system. In: *Large Animal Internal Medicine. Diseases of horses, cattle, sheep and goats.* 2nd. Ed. By; Bradford, P. Smith, Mosby-Year Book Inc., Philadelphia.
- Roberts, S. J.,(1986): *Veterinary obstetrics and genital diseases.* Published by the author, Ithca, New York.
- Saperstein, G., (1993): Congenital abnormalities of internal organs and body cavities. *Vet. Clin. North Am.: Food Anim. Pract.* 9 (1): 115-125.
- Saperstein, G., Leipold, H.W., Dennis, S.M., (1975): Congenital defects of sheep. *JAVMA*, 167: 314-322.
- Shokry, M., EL-keiey, M.T., Hamouda, M. and Gadallah, S., (1997): Commercial polyester fabric repair of abdominal hernias and defects. *Vet. Rec.*, 140 (6): 606-607.
- Smith, M.C. and Sherman, D.M., (1994): *Goat medicine,* Philadelphia, Lea and Febiger.
- Soliman, A.S., Abid, T.A. and AL-Badrany, M.S., (1987a): A congenital bilateral anophthalmia and atresia ani in a lamb (case report). *J. Egypt. Vet. Med. Ass.* 47(4):803-804.
- Soliman, A.S., Esho, S.M. and Abid, T.A., (1987b): Supernumerary horns in an ewe (case report). *J. Egypt. Vet. Med. Ass.* 47 (4): 805-806.
- Soliman, A.S., Esho, S.M. and Yasin, M.I., (1988): Unusual horny teratoma in an ewe (case report). *Alex. J. Vet. Sci.*, 4 (2): 469-471.
- Takahashi, K.; Hirano, T.; Ono, H.; Katsumata, S.; Yashima, T., (1993): Congenital ventral hernia and its surgical treatment in Japanese Black calves. *J. -Japan-Vet. -Med.-Assoc.*, 46: 8: 635-638.
- Wright, J.G., (1963): The surgery of the inguinal canal in animals. *Vet. Rec.*75 (50): 1352-1367.