

## INCIDENCE OF ALVEOLOPLASTY AND ITS INDICATIONS – PROTOCOL TO REDUCE THE INCIDENCE

<sup>1</sup>ASMA PARVEZ, BDS

<sup>2</sup>MAMOONA A MALIK, BDS

<sup>3</sup>M AZHAR SHEIKH, BDS, MSC (London), FDS RCS (Eng), FFD RCS (Ire), FDS Oral Surg (UK)

### ABSTRACT

*Alveoplasty is one of the common pre prosthetic surgical procedure carried out in dental surgical practice setups. The aim of pre-prosthetic surgery is to improve the quality of oral supporting structures, which can provide better retention and stability to dental prosthesis. It also prevents any further hard or soft tissue loss. Alveoplasty procedure is used for recontouring of bony irregularities at time of extractions or after initial healing. Simplest form includes squeezing of socket walls at time of extraction, which reduces the incidence of secondary alveoplasty at later stages when patient requires denture rehabilitation. It may involve more complex procedures such as maxillary tuberosity reduction, removal of excessive undercuts, and bony exostosis like mandibular and palatal tori. It also reduces the chances of post-operative discomfort and complications. Mucosa covering the alveolar arches after alveoplasty should be of uniform thickness and density so that occlusal load is distributed equally throughout the dental arches, making it more comfortable for patients to wear prosthesis.*

*This study includes data consisting of number of patients requiring secondary alveoplasty at Oral & Maxillofacial Surgery department of Islamic International Dental Hospital in last 3 years (2009, 2010 and 2011). It also includes the symptoms with which patients present and suggestions/ protocols to reduce the incidence of this second surgical procedure. We have implemented these protocols in this department, to reduce the need of secondary alveoplasty because this procedure causes extra financial and surgical burden on patients. It also delays the rehabilitation of oral health. Second arm of this study is being planned after implementation of these protocols to evaluate their outcome.*

**Key Words:** Alveoplasty, Secondary Alveoplasty, Alveolar Ridge Recontouring, Pre-prosthetic Surgery.

### INTRODUCTION

Alveoplasty is one of the common pre-prosthetic surgeries done in dental practice. The aim of pre-prosthetic surgery is to improve the quality and condition of the hard and soft oral supporting structures, so that they can provide better retention, support and stability to the dental prosthesis.<sup>1</sup> It involves recon-

touring and smoothening of alveolar arches and then covering the arches with healthy soft tissue which helps in providing a stable and retentive oral prosthesis. The objective of alveoplasty is to round off sharp bony edges and to remove any gross bony irregularities and undercuts present after the extractions. Mucosa covering the alveolar arches after alveoplasty procedure should be of uniform thickness and density so that occlusal load is distributed equally throughout the dental arches.<sup>2</sup>

Alveoplasty can be as simple as the compression of socket walls after closed extraction.<sup>3,4</sup> Intraseptal alveoplasty is another type of alveoplasty which

<sup>1,2</sup> Demonstrators, Dept of Oral & Maxillofacial Surgery

<sup>3</sup> Professor & Head of Department of Oral & Maxillofacial Surgery, Islamic Int'l Dental College & Hospital, G-7/4, 7<sup>th</sup> Avenue, Islamabad. Email: azhar60@gmail.com, Office: 051-2891835-38

Received for Publication: April 10, 2013

Revision Received: May 22, 2013

Revision Accepted: May 25, 2013

includes removal of septal/ interdental bone and results in the close approximation of labial and lingual cortical plates and relieves the undercut.<sup>3,4</sup> It can be done at the time of tooth extraction.<sup>3,4</sup> This technique is helpful in preserving the alveolar ridge height but results in the decreased width and thickness of alveolar ridge.<sup>4</sup> Intraseptal alveoplasty and non-surgical extractions with properly squeezed sockets results in good long term preservation of alveolar ridge height in comparison to the labial bone reduction which is usually done in secondary alveoplasty.<sup>5</sup>

Radical alveoplasty is normally required in cases where severe undercuts are present and in pre radiation extraction cases.<sup>6</sup> In this technique, whole buccal or labial cortical plate is removed after extraction in order to reduce the chances of osteoradionecrosis post radiation.<sup>6</sup>

Secondary alveoplasty is a second surgical procedure that is carried out after the post extraction healing to eliminate the gross bony irregularities.<sup>7</sup>

The reason behind conducting this study was that an increase in number of alveoplasty procedures was observed during the last 3 years at Islamic international dental hospital. Since, no literature has been published on this topic in this country before; the present study was carried out to find out the factors that were responsible for increased incidence of alveoplasty procedure and to suggest possible measures and guidelines to reduce the number of second surgical procedures in future.

## METHODOLOGY

A retrospective study was done in the Oral Surgery Department at Islamic International Dental Hospital, Islamabad. Patient records from January 2009 till December 2011 were collected. This study was set out to assess the trend in secondary alveoplasty procedures being performed in the Oral Surgery Department.

From the patient records of three years 2009-2011, the total number of extractions and post-extraction alveoplasty procedures performed were counted. The total numbers of extractions were further grouped into number of quadrants of the oral cavity in which the extractions were done. Analysis showed that alveolo-

plasty was required in quadrants where at least two or more extractions were performed simultaneously. Therefore, total number of quadrants from where two or more extractions had been done at one sitting was calculated.

The numbers of alveoplasty procedures performed each year were calculated as a percentage of the total number of quadrants in which two or more extractions were performed. These percentages were described for each year.

ANOVA test was done to compare the frequency of alveoplasty procedures performed. On getting a significant result for ANOVA, the Post hoc Tukey test was performed to compare the year wise comparison of the alveoplasty procedures performed.

## RESULTS

The numbers of extractions performed and quadrants treated where two or more extractions were performed were about the same in the years 2009 and 2011. However, an increased number of extractions were performed in 2010. These differences have been illustrated in Table 1.

TABLE 1: FREQUENCY OF EXTRACTIONS AND QUADRANTS WHERE EXTRACTIONS WERE PERFORMED

Year	Total number of extractions performed	Total number of quadrants in which two or more extractions were performed
2009	8622	2874
2010	9533	3198
2011	8407	2802

In 2009, only 41 alveoplasty procedures were performed which was about 1.43% of the total number of quadrants in which at least two extractions were performed. In 2010, there was an increase in alveoplasty procedures (n = 62; 1.94%). However, in 2011 there was sharp increase in the number of alveoplasty procedures (n = 107; 3.82%). These frequencies have been illustrated in Table 2 and Fig 1.

On applying the ANOVA test for comparing the alveoplasty procedures between three years, a highly

TABLE 2: FREQUENCY AND COMPARISON OF ALVEOLOPLASTY PROCEDURES

Year	Number of quadrants in which two or more extractions were performed	Number of alveoloplasty procedures	Percentage of alveoloplasty procedures
2009	2874	41	1.43%
2010	3198	62	1.94%
2011	2802	107	3.82%

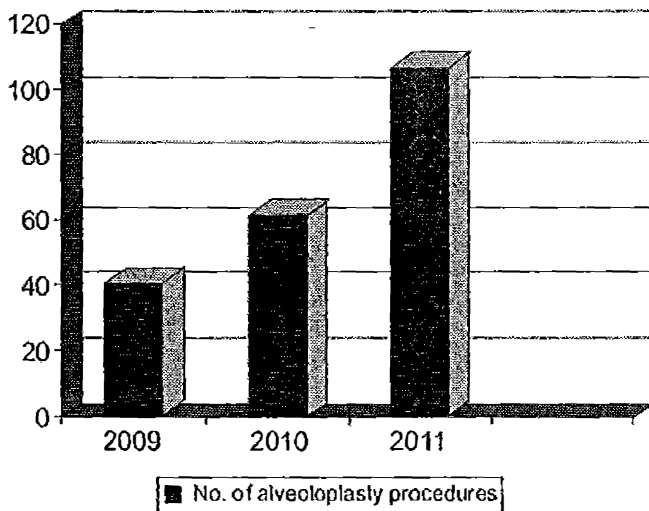


Fig 1: Frequency of Alveoloplasty Procedures Performed Per Year

TABLE 3: PER YEAR PERCENT INCREASE IN ALVEOLOPLASTY PROCEDURES

Years	Percent Increase in Alveoloplasty Procedures
2009 - 2010	0.51%
2010 - 2011	1.88%
2009 - 2011	2.39%

significant difference was calculated between three years ( $p < 0.001$ ). On further investigation using the post hoc Tukey test, a significant difference in the frequencies of alveoloplasties was found between the years 2009 and 2011 ( $p < 0.001$ ) and the years 2010 and 2011 ( $p < 0.001$ ). However, the difference was not significant for the years 2009 and 2010 ( $p = 0.388$ ).

**DISCUSSION**

Results showed an increase of 2.39% in the rate of

alveoloplasty procedures from year 2009 till 2011, which is alarming. A number of causative factors have been identified which are responsible for the increased rate of secondary alveoloplasty.

- Squeezing the socket improperly after tooth extraction results in expanded buccal and lingual cortical plates and irregular alveolar ridges after initial healing.
- Sharp bony fragments left after tooth extraction results in continuous mucosal irritation and ulceration after healing and denture loading.
- Fracture of buccal cortical plate during simple extraction or excessive bone guttering during removal of fractured or deeply carious tooth leads to irregularity in alveolar ridge.
- Alveolar resorption at the site of extraction continues to occur if site is not preserved by some bone augmentation procedures at the time of extraction.<sup>8</sup> This prolonged edentulous area undergoes horizontal and vertical bone loss resulting in the irregularity in contour of alveolar ridge.<sup>8</sup>
- Undergraduate students carried out majority of extractions under strict supervision. In spite of this, they may have not looked into fine details like squeezing sockets after extraction that contributed in increased requirement of secondary alveoloplasty procedures.

Simple guidelines followed at the time of extractions can significantly decrease the rate of secondary alveoloplasty procedures. These guidelines/ protocols include:

- Properly squeezing or compressing the extraction socket with thumb and index finger after extraction.<sup>4</sup> It results in compression of expanded cortical plates and contour the underlying cortical bone, thus reducing the need of second surgical procedure.<sup>4</sup>
- To remove sharp bony spicules with the help of bone rounders and smoothening of rough edges of bone with the help of bone file at the time of multiple extractions.<sup>3</sup>

- Patients with severe undercuts and horizontal jaw discrepancies, intra-septal alveoplasty should be performed at the time of extraction.<sup>3</sup>
- Undergraduate students are taught about the importance of maintaining alveolar bone contours after extractions with special attention in cases where multiple extractions are carried out in same quadrant.
- Preservation of the socket immediately after extraction with the help of grafts such as beta tri-calcium phosphate (bTCP) and covering it with resorbable membrane.<sup>9</sup> It is a simple and effective technique to prevent bone loss following extraction and maintain the normal height and width of alveolar ridge.<sup>9</sup>
- Plan bone augmentation in areas of severe bone resorption with the help of bone grafts or guided bone regeneration with barrier membrane.<sup>8</sup>

If above-mentioned measures are taken on time then second surgical procedure may be avoided and early rehabilitation of patient functions and aesthetic is possible.

Secondary alveoplasty procedure requires crestal incision with or without releasing incisions and reflection of full thickness mucoperiosteal flap. Gross bony defects are removed under copious saline irriga-

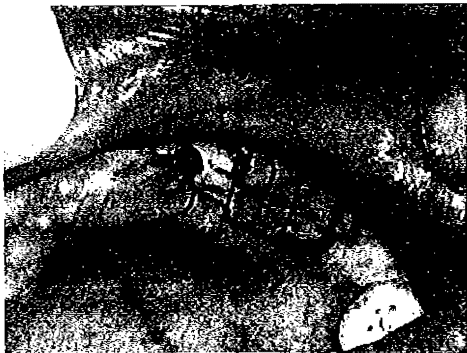

Fig 2: Replaced Flap with Continuous Interlocking Sutures.

tion.<sup>7</sup> Minor bony defects can be removed with the help of bone ronguers and files to prevent over reduction of arches. After correction of hard tissues, excessive and hypermobile soft tissue is excised.<sup>7</sup> Flap is replaced with the help of tension free sutures (Fig. 2).

Second surgical procedure results in increased morbidity like post-operative discomfort, swelling and require almost a month for good healing. This leads to delay in prosthesis fabrication and is inconvenient for the patients due to increased appointments and extra financial and surgical burden.

## CONCLUSION

Incidence of secondary alveoplasty can be reduced by following the guidelines and protocols mentioned above in discussion i.e. compression of socket and removing sharp bony edges at the time of extraction and by properly supervising and guiding the students while doing extractions.

## REFERENCES

- 1 Gandevala AM, Kaul DD, Gupta AK. Premaxillary alveolar recontouring- A case report of secondary alveoplasty. *Universal Research Journal of Dentistry*. 2011; 1(1): 46-48.
- 2 Malik NA. *Textbook of oral and maxillofacial surgery*. 2<sup>nd</sup> Edition. 2008: 419.
- 3 Sarandha DL. *Textbook of complete denture prosthodontics*. 1<sup>st</sup> Edition. 2007: 35-36.
- 4 Hupp JR, Ellis E, Tucker MR. *Contemporary oral and maxillofacial surgery*. 5<sup>th</sup> Edition. 2009: 217-19.
- 5 Michael CG, Barsoum WM. Comparing ridge resorption with various surgical techniques in immediate dentures. *Journal of Prosthetic Dentistry*. 1976; 35: 142-55.
- 6 Sanghai S, Chatterjee P. *A concise textbook of oral and maxillofacial surgery*. 1<sup>st</sup> Edition. 2009: 148-49.
- 7 Peterson LJ. *Peterson's Principles of oral and maxillofacial surgery*. 2<sup>nd</sup> Edition. 2004: 168-69.
- 8 Salama MA, Keith JD. Ridge preservation and augmentation using regenerative materials to enhance implant predictability and esthetics. *Compendium of Continuing Education in Dentistry*. 2007; 28(11): 614-21.
- 9 Abadzhiev M. Ridge preservation technique. *Journal of IMAB*. 2009; 2: 58-60.