

Case report

Low bifurcation of the common carotid arteries: an anatomical and radiological study

M.A. Bakheit¹ and F.M. Al Gahatani²

Introduction

The common carotid artery (CCA) usually bifurcates at the level of the upper border of the thyroid cartilage (C3–4 cervical vertebrae) or the body of the hyoid bone (C3) [1]. Despite the fact that bifurcation can occur at any level in the neck, low level bifurcation occurs far less frequently than at higher levels [2,3]. The CCA is close to many vital structures in the neck, including the trachea, oesophagus, inferior thyroid and vertebral arteries, and recurrent laryngeal nerves. Injury to these structures might be experienced during carotid endarterectomy or in neurosurgical approaches to the anterior aspect of the neck, as in anterior discectomy of the cervical vertebrae [4]. This case demonstrates the level of bifurcation of the CCA and its importance in neck surgery.

Case report

A 57-year-old Asian man presented to King Fahad Educational Hospital in Al Khobar, Saudi Arabia in April 2010 complaining of dizziness and sleep disturbance for 2 years. He presented initially to the Neurology Clinic and was then referred to the Radiology Department for further investigations. The patient underwent carotid angiography (Figures 1 and 2). The left CCA was only 2–3 cm long. It divided at the level of the C7–T1

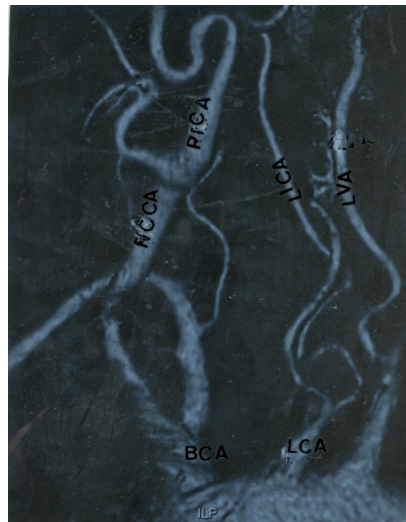


Figure 1 Angiography of the common carotid artery (low magnification $\times 300$) BCT: brachiocephalic artery; LCCA: left common carotid artery; LSA: left subclavian artery; RCCA: right common carotid artery

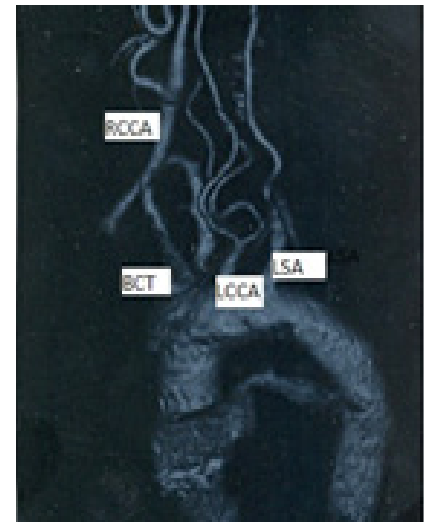


Figure 2 Angiography of the common carotid artery (high magnification) BCA: brachiocephalic artery; LCA: left common carotid artery; LICA: left internal carotid artery; LVA: left vertebral artery; RCCA: right common carotid artery; RICA: right internal carotid artery

vertebrae into the external carotid artery (ECA) and internal carotid artery (ICA). The left ECA and ICA looked smaller than those on the right side. The right CCA showed a marked stricture in the middle region and a well marked carotid sinus. The right ICA was tortuous.

Discussion

The stricture of the right CCA and tortuous right ICA and/or the smaller left ECA and ICA may have precipitated the dizziness in our patient.

The level of bifurcation of the CCA has been found to vary considerably in different countries (Table 1). In a study of 67 CCAs in 36 New Zealand cadavers [2], 27 (40%) showed bifurcation at the body of the hyoid bone (C3), 26 (39%) at the superior border of the thyroid cartilage (C3–4), 10 (15%) at the tip of the greater horn of the hyoid bone (C2), and four (6%) at the body of the thyroid cartilage (C5). In 15 of 36 cadavers (48%) the level of bifurcation of the CCA was asymmetrical between the left and right side. In a study of 80 adult Kenyan cadavers,

¹Al Ghad International Colleges for Health Sciences, Buraidah, Saudi Arabia (Correspondence to M.A. Bakheit: mbakheit50@hotmail.com).

²Department of Radiology, King Fahad Educational Hospital, Dammam University, Al Khobar, Saudi Arabia (F.M. Al Gahatani: drfad.n.q@gmail.com).

Received: 29/11/12; accepted: 02/03/13

Table 1 Level of bifurcation of the common carotid artery in different nationalities

Nationality	Level of bifurcation			
	C3 %	C4 %	High bifurcation %	Low bifurcation %
New Zealander (n = 36) [2]	40.0	39.0	15.0	6.0
Kenyan (n = 80) [3]	38.8	22.5	25.4	13.3
Japanese (n = 80) [7]	57.5	0	31.2	11.3

38.8% showed bifurcation at C3, 22.5% at C4, and 25.4% at higher levels [3]. CCA bifurcations were quite variable in Japanese studies. Hayashi et al. [5] reported that bifurcation was around the inferior part of the body of C3. Lo et al. [2] described CCA bifurcation in relation to the thyroid cartilage and hyoid bone. They found bifurcation at the level of the body of the hyoid bone in 40% of cases, and the level of the bifurcation was asymmetrical between the left and right sides. Inamasu and

associates showed individual variation regarding CCA bifurcation [6]. Ito and associates reported a high level of CCA bifurcation in 25 (31.2%) patients, standard bifurcation in 46 (57.5%), and low bifurcation in nine (11.3%) [7].

In the present case, the patient was Asian, so the level of bifurcation of the CCA was expected to be at C3–C4, similar to that in Japanese patients. However, it occurred at the level of C7–T1, which is lower than the usual Asian pattern.

Low bifurcations at C5 and C6 and thoracic bifurcations have been reported by some authors [4,8,9]. The CCA may be trifurcated [10] or it might be absent [11,12]. Low bifurcation of the CCA at C7–T1, as in the present case, might be accompanied by other carotid artery anomalies. It might cause injury to the lung cupola, lymphatic ducts or blood vessels at the root of the lungs, or the stellate ganglion during anterior neck surgery.

Competing interests: None declared.

References

1. Sinnatamby CS. *Last's anatomy: regional and applied*, 11th ed. London, Elsevier/Churchill Livingstone, 2006:354.
2. Albert LO et al. Anatomical variations of the common carotid artery bifurcation *Australia and New Zealand Journal of Surgery*, 2006, 76:970–972.
3. Anangwe D et al. Anatomical variations of the common carotid arteries in adult Kenyans. *East African Medical Journal*, 2008, 85:244–247.
4. Gulsen S, Caner H, Altinors N. An anatomical variant: low-lying bifurcation of the common carotid artery, and its surgical implications in anterior cervical discectomy. *Journal of the Korean Neurosurgical Society*, 2009, 45:32–34.
5. Hayashi N et al. Surgical anatomy of the cervical carotid artery for carotid endarterectomy. *Neurologia Medico-Chirurgica*, 2005, 45:25–29.
6. Inamasu J, Guiot BH. Iatrogenic carotid artery injury in neurosurgery. *Neurosurgery Review*, 2005, 28:239–247.
7. Ito H et al. Clinical anatomy in the neck region – the position of external and internal carotid arteries may be reversed. *Oka-jimas Folia Anatomica Japan*, 2006, 82:157–167.
8. Vitek JJ, Reaves P. Thoracic bifurcation of the common carotid arteries. *Neuroradiology*, 1973, 5:133–139.
9. Rielly JP. Intrathoracic bifurcation in Klippel–Fiel syndrome. *Journal of Vascular Surgery*, 2008, 47:1071–1073.
10. Chitra R. Trifurcation of the right common carotid artery. *Indian Journal of Plastic Surgery*, 2008, 41:85–88.
11. Maybody M et al. Absence of the common carotid artery: a rare vascular anomaly. *American Journal of Neuroradiology*, 2003, 24:711–713.
12. Roberts LK, Gerald B. Absence of both common carotid arteries. *American Journal of Roentgenology*, 1978, 130:961–962.