

## Case report

# Hydatid cyst of the right atrium wall

F. Sabzi,<sup>1</sup> F. Ghasemi,<sup>1</sup> H. Madani<sup>2</sup> and R. Faraji<sup>3</sup>

## Introduction

Hydatid disease (echinococcosis) is caused by the larvae of *Echinococcus granulosus*. Sheep are the intermediate hosts of the cystic stages of these tapeworms. Dogs, another host, defecate outside, and further spread may be via streams, effluent or flies. Thick egg shells protect them from environmental extremes. Sheep acquire strong resistance against new cysts developing but this has little effect on existing cysts. The cycle is perpetuated as carcasses of infected sheep are eaten by dogs. Small cysts are susceptible to desiccation but large hydatid cysts are very resilient. Cool, moist conditions are most favourable for survival. Freezing is not likely to be severe enough in the field to kill a significant number of cysts. After ingestion, larvae pass the intestine and reach the right side of the heart through the thoracic duct and superior vena cava; from the right ventricle the embryo passes through the pulmonary vascular bed into the left ventricle, from where it could reach any part of the body through systemic circulation [1–3]. The first successful surgical intervention on hydatid cyst was reported by Long in 1932 [4].

Intracavitary hydatid cyst in the right atrium is rare and potentially has a fatal outcome but isolated right atrial wall hydatid cyst is an exceedingly rare presentation. In most patients, heart hydatidosis is calcified and become asymptomatic. It may cause right or left

ventricular outflow obstruction, mitral regurgitation, tricuspid regurgitation, aortic stenosis, myocardial dysfunction, conduction disturbances, stroke, lower limb ischaemia, or may lead to congestive heart failure. The symptoms may be nonspecific and hence establishing an early diagnosis is difficult.

Cardiac hydatid cysts are uncommon in cases of hydatid disease. The most frequent location of the cyst is the myocardial region, particularly the interventricular septum and left ventricular free wall. Right atrial wall involvement due to paucity of vascular bed and myocardial fibre is extremely uncommon.

Clinical presentation of cardiac echinococcosis depends on the site, size, calcification and number of cysts, integrity of the cyst, and effect of the cysts, palpitations and presence of complications as result of cyst rupture [5].

The location of the cyst in myocardial tissue is subepicardial, subendocardial or intramyocardial. However, when a cyst is located in subendocardial endothelium, depending on the potency of the immune system, patients may be asymptomatic, silent or catastrophic and lethal as seen in Sinha's and Perez-Gomez et al.'s studies [6,7]. Di Bello and Menendez [8] reported that in subepicardial cyst rupture, rupture may be asymptomatic or it may cause acute pericardial tamponade, secondary pericardial cysts or constructive pericarditis. Madariaga and colleagues [9] showed

that the rupture of subendocardial cysts may be silent, may cause anaphylactic shock and sudden death, peripheral and cerebral embolism, or pulmonary embolism. Agarwal and colleagues [10] reported that intracavitary expansion of hydatid cyst caused dyspnoea or right or left outflow obstruction. In the right ventricle, local intracavitary rupture is more frequent than in the left ventricle and can cause pulmonary embolism, pulmonary hypertension and death. Ameli and colleagues reported [11] that acute coronary syndrome secondary to the compression of a coronary artery or germinative layer embolism to coronary artery may mimic coronary artery disease. Di Bello and Menendez [8] showed that chest pain may arise secondary to intrapericardial rupture and acute pericarditis and mimic acute coronary syndrome or acute aortic dissection. In Dighiero et al.'s [12] case report, the resulting pain of pericarditis may radiate to the epigastrium and it may closely mimic acute abdomen.

Most patients with calcification of the cyst wall remain asymptomatic for a long time or have nonspecific symptoms, such as thrush, pruritus, fever, chest pain and muscle weakness. In Uysalel and colleagues's study [13], infected myocardial hydatid cyst mimicked left ventricular aneurysm. Anaphylactic shock may develop due to cyst rupture into the bloodstream. Other complications include systemic or pulmonary germinative layer embolism, valve obstruction, mitral regurgitation

<sup>1</sup>Department of Cardiovascular Surgery, Imam Ali Cardiovascular Centre, Kermanshah University of Medical Sciences, Kermanshah, Islamic Republic of Iran.

<sup>2</sup>Department of Pathology, Faculty of Medicine, Kermanshah University of Medical Sciences, Kermanshah, Islamic Republic of Iran.

<sup>3</sup>Yazd Cardiovascular Research Centre, Shahid Sadoughi University of Medical Sciences, Yazd, Islamic Republic of Iran (Correspondence to R Faraji: rezafaraji60@yahoo.com).

Received: 17/01/13; accepted: 19/02/13

secondary to distortion of valve or papillary muscle involvement, or papillary muscle ischaemia. Atrioventricular conduction defects and arrhythmias was report in a study by Agarwal et al. [10]. Symptoms of a pericardial hydatid cyst are generally due to the intrapericardial cyst expansion pressure effect of the cyst on the myocardium or on the internal table of the sternum or rupture of cyst.

### Case report

A 57-year-old female from a rural sheep farm presented with history of dyspnoea, cough, atypical left-side chest pain and weakness. Her pulse rate was irregular and blood pressure was 140/60 mmHg. Physical examination of chest and abdomen was normal, and there was no murmur. The complete blood count was normal except for mild iron deficiency anaemia. A chest X-ray was unremarkable, and a localized calcification or abnormal cardiac silhouette was not seen. ECG revealed no bundle block or T wave change in inferior, lateral and anterior cardiac leads. Transthoracic echocardiography demonstrated a mixed echogenic mass of 60 × 50 mm on the lateral aspect of the right atrial free wall. Transoesophageal echocardiography confirmed the findings of a mass lesion with areas of hypoechogenicity. The thoracic contrast enhanced computed tomography (CT) scan revealed a well defined smooth margined lesion on the right atrial free wall with compressive effect on lung and right atrium (Figure 1). The CT scan of the abdomen shows non-involvement of the liver (Figure 2). In the present case, the disease manifested with dyspnoea, atrial fibrillation and chest pain.

### Surgical procedure

Cardiopulmonary bypass with bicaval venous cannulation (superior and inferior vena cava were cannulated to

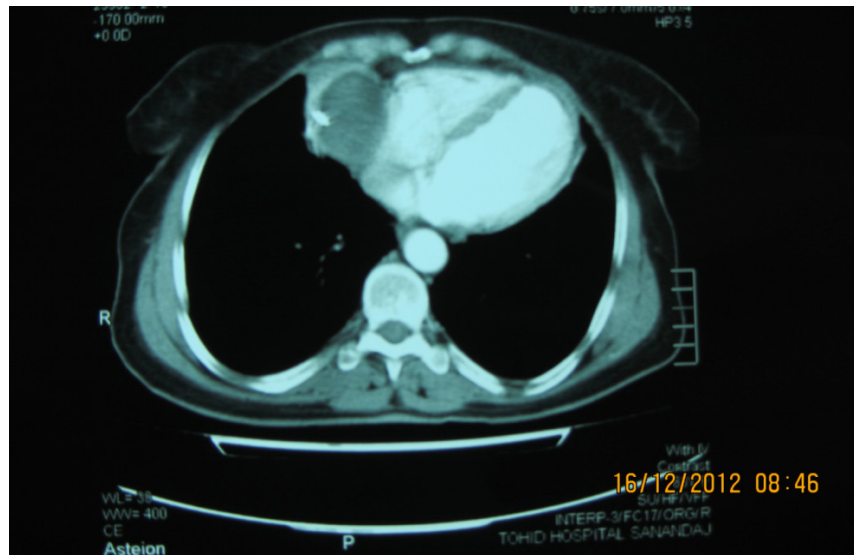

Figure 1 Thoracic CT scan showing right atrial wall hydatid cyst

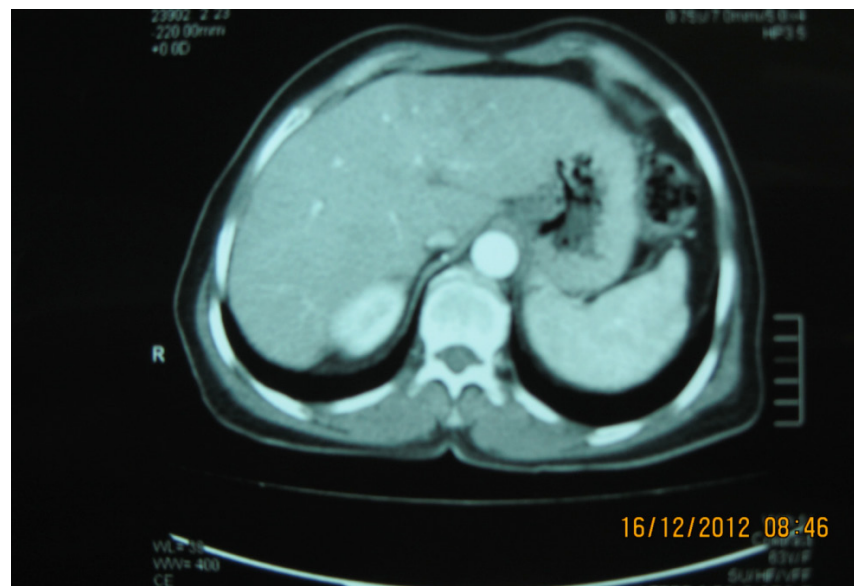


Figure 2 Abdominal CT scan showing non-involvement of hepatobiliary system

avoid injury and rupture of the cyst) and moderate hypothermia of 28 °C were initiated, and the aorta along with pulmonary artery was cross-clamped, and cardioplegia delivered through the aortic root. Under cold potassium and blood cardioplegic and ischaemic arrest, a right atriotomy was performed. The cystic mass had intracavitary expansion and was not connected to bloodstream. The wall

of the cyst was fibrotic and attached to the pericardium, inferior vena cava and pulmonary vein. The surface of the cyst was rough with small pieces of clots adhering to it. Enucleation of the cyst from the right atrium was attempted, but the cyst was fragile and ruptured; we were not able to cut away the cyst successfully. The cyst wall was fibrotic with thick non-purulent fluid, and many smaller daughter cysts,

grape-like, were seen inside (Figure 3). Needle aspiration of the cystic contents was performed after sterilization with ethanol. Ethanol 96% was injected intracavitarily, and after six minutes the entire germinative cyst was removed under cardiopulmonary bypass. The opening of cyst wall was closed without capitonage. Ameli et al. [11] advised the placement of an additional filter on the venous side of the circuit to prevent the passage of hydatid particles to the pump, especially in rupture cases. Pathological examination of the daughter cysts and fluid revealed many numbers of free hooklets and scolices. Gram stain showed numerous white cells, and there were no organisms on the smear. Culture on multiple culture media was negative. Pathological examination also confirmed the diagnosis of hydatid cyst. The blood serum was positive by ELISA for echinococcosis. The patient was started on albendazole and discharged on the seventh postoperative day. She was advised to continue albendazole for three months.

## Discussion

Kaplan et al. and Matossian et al. have suggested transmigration of embryos through the septum of the atrium or ventricle to the left side of the heart, and embryos nesting in the interatrial septum or interventricular septum may cause interatrial or interventricular septum hydatid cyst [14,15]. The right atrial free wall hydatid cyst caused by direct transmigration of larvae through the right atrial cavity to the atrial wall or indirectly by migration of embryos to the pulmonary artery, pulmonary vascular bed, pulmonary vein, left atrium, left ventricle or aorta and through the coronary circulation to the atrial wall. Larvae usually reach the myocardium through the coronary circulation, although the intestinal



**Figure 3** Germinative layer and doughier cyst

lymphatic vessels, the thoracic duct, the superior and inferior venae cavae and the haemorrhoidal veins of the large intestine may also be pathways. Di Bello and Menendez suggest that cardiac involvement occurs through pulmonary veins [8]. Miralles et al. documented that the distribution of echinococcosis in the heart depends on the blood supply to that part of the heart [16]. The prevalence of invasion of the left ventricle, which has the most myocardial mass and abundant blood supply, by hydatid cyst, is 55%–60% of the time followed by involvement of the interventricular septum, reported in 5%–9% of cardiac cases. The right atrium is involved in 3%–4% of cases, and the right ventricle in 15%. Distribution in the left atrium, pulmonary artery and pericardium occurs in 8%, 7%, and 8% of cardiac cases, respectively. In Marato et al.'s study, hydatid disease of the heart occurred in 0.5%–2% of all cases hydatidosis in humans [17]. There does not appear to be any age limit at presentation. In Agarwal et al.'s case series report, cyst caused obstruction in the chamber of the heart or induced conduction disturbance [10].

Di Bello and Menendez showed that rupture of a cardiac cyst may result in anaphylactic shock, pulmonary embolism and systemic metastasis [8]. Hydatid cyst of the left ventricle is usually localized subepicardially and rarely ruptures into the pericardial space. In our patient, the cyst was localized to the free wall of the right atrium. In Kulan et al.'s study involvement of the interventricular septum was reported in 5%–9% of cases [18].

Transthoracic or transoesophageal echocardiography, computerized tomography and magnetic resonance imaging are valuable diagnostic methods. In our patient, the diagnosis was considered preoperatively, and, intraoperatively, the possibility of hydatid cyst was considered, and necessary precautions like pad package moistened with ethanol 96%, were taken during the excision of the mass. Eren and colleagues believes that pads soaked in an aqueous sodium chloride solution can also be used to good effect in protecting the surgical field [19]. Risks in surgery from leakage of fluid include anaphylaxis and dissemination of the infected scolices or localized



intrapericardial cyst. The latter complication can be minimized by the instillation of scolicalid solutions like iodine, methylene blue, hypertonic saline or ethanol. In our patient, before opening the cyst wall, ethanol was injected into cyst; the contents were sucked out and ethanol was repeatedly instilled into the cyst cavity. After the removal of cyst, the whole pericardial cavity was washed with ethanol. Ethanol 96% does not have any effect on the conduction system of the heart but causes haemolysis; after instillation of the pericardial space with ethanol it was washed with copious amount of normal saline [20–24].

## Conclusion

The present unusual and exceedingly rare case exemplifies that one has to keep hydatid cyst in the differential diagnosis of a mixed echogenic mass in the right atrium wall on echocardiography. The present case is unusual in that the site of hydatidosis was the free wall of the right atrium. Paucity of myocardial fibre and blood flow mean that infestation of this location is rare. In this case, embryos reached the atrial wall via two unusual mechanisms, via the coronary artery or direct transmigration to the free wall. Incision of the right atrium revealed a

large abnormal atrial artery that had not been documented in angiography. This abnormal large artery, by increasing atrial wall flow, may predispose to larval nidation in this specific location.

## Acknowledgement

The authors would like to acknowledge the kind efforts made by the pathology department and nurses at Emam Ali Heart Hospital, Kermanshah University of Medical Sciences, Kermanshah, Islamic Republic of Iran.

**Competing interests:** None declared.

## References

1. Tandon S, Darbari A. Hydatid cyst of the right atrium: a rare presentation. *Asian Cardiovascular & Thoracic Annals*, 2006, 14:e43–e44. <http://dx.doi.org/10.1177/021849230601400324>
2. Ipek G et al. Large cardiac hydatid cyst in the interventricular septum. *Texas Heart Institute Journal*, 2011, 38:719–722.
3. Yilmazkaya B et al. Direct approach to hydatid cyst of the interventricular septum. *Texas Heart Institute Journal*, 2009, 36:174–176.
4. Long WJ. Hydatid disease in the left ventricular wall of the heart. *Medical Journal of Australia*, 1932, 19:701.
5. Yaliniz H et al. Surgical treatment of cardiac hydatid disease. *Texas Heart Institute Journal*, 2006, 33:333–339.
6. Sinha PR, Jaipuria N, Avasthey P. Intracardiac hydatid cyst and sudden death in a child. *International Journal of Cardiology*, 1995, 51:293–295.
7. Perez-Gomez F et al. Cardiac echinococcosis: clinical picture and complications. *British Heart Journal*, 1973, 35:1326–1331.
8. Di Bello R, Menendez H. Intracardiac rupture of hydatid cysts of the heart. A study based on three personal observations and 101 cases in the world literature. *Circulation*, 1963, 27:366–374.
9. Madariaga I et al. Cardiac echinococcosis and systemic embolism. Report of a case. *Thoracic and Cardiovascular Surgeon*, 1984, 32:57–59.
10. Agarwal DK, Agarwal R, Barthwal SP. Interventricular septal hydatid cyst presenting as complete heart block. *Heart (British Cardiac Society)*, 1996, 75:266.
11. Ameli M, Mobarhan HA, Nouraii SS. Surgical treatment of hydatid cysts of the heart: report of six cases. *Journal of Thoracic and Cardiovascular Surgery*, 1989, 98:892–901.
12. Dighiero J et al. Echinococcus disease of the heart. *Circulation*, 1958, 17:127–132.
13. Uysalel A et al. Cardiac echinococcosis with multivisceral involvement. *Pediatric Cardiology*, 1996, 17:268–270.
14. Kaplan M et al. Cardiac hydatid cysts with intracavitary expansion. *Annals of Thoracic Surgery*, 2001, 71:1587–1590.
15. Matossian RM, Rickard MD, Smyth JD. Hydatidosis: a global problem of increasing importance. *Bulletin of the World Health Organization*, 1977, 55:499–507.
16. Miralles A et al. Cardiac echinococcosis. Surgical treatment and results. *Journal of Thoracic and Cardiovascular Surgery*, 1994, 107:184–190.
17. Maroto LC et al. Hydatid cyst of the interventricular septum in a 3.5-year-old child. *Annals of Thoracic Surgery*, 1998, 66:2110–2111.
18. Kulan K et al. Hydatid cyst of the interventricular septum and contribuion of magnetic resonance imaging. *Acta Cardiologica*, 1995, 50:323–3326.
19. Gómez-Arnau J et al. Iatrogenic myocardial dysfunction after formalization of the heart. *Cardiovascular Diseases*, 1981, 8:558–561.
20. Tuncer E et al. Surgical treatment of cardiac hydatid disease in 13 patients. *Texas Heart Institute Journal*, 2010, 37:189–193.
21. Sogunuru G et al. Cardiac hydatidosis presenting as an acute coronary syndrome. *BMJ Case Reports*, 2010, 2010:bcr0220102752.
22. Apaydin AZ et al. Hydatid cyst confined to the papillary muscle: a very rare cause of mitral regurgitation. *Texas Heart Institute Journal*, 2009, 36:598–600.
23. Shehatha J et al. Surgical management of cardiac hydatidosis. *Texas Heart Institute Journal*, 2009, 36:72–73.
24. Ercan S et al. Isolated invasive endomyocardial cystic echinococcosis presenting with heart failure. *Case Reports in Medicine*, 2012, 2012:603087.