

# Induction of leukaemia in chloramphenicol-treated toads

M.M. El-Mofty,<sup>1</sup> N.E. Abdelmeguid,<sup>1</sup> I.A. Sadek,<sup>1</sup> A.E. Essawy<sup>1</sup> and E.A. Abdel Aleem<sup>1</sup>

## تحريض ابيضاض الدم في العلاجم (الضفادع) المعالجة بالكلورامفينيكول محمد المفتي ونبيلة عبد المجيد وإسماعيل صادق وأمنية عيسوي وإيمان عبد العليم

خلاصة: عُرف الكلورامفينيكول بارتباطه بحدوث فقر الدم اللاتنسجي. ولما كان هذا الدواء لا يزال يستعمل على نطاق واسع في مصر فقد درسنا تأثيره على مئة علاجوم (ضفدع) مصري أعطيت جرعات من الكلورامفينيكول تبلغ 5 ميليغرام لكل 40 غرام من وزن الجسم لمدة 12 أسبوعاً. وقد وجدنا أنه أحدث عدداً من التغيرات الوحيمية في البنية المستدقة لكل أنواع الكريات البيض تقريباً. وكانت هذه التغيرات مشابهة لتلك التي أحدثها المركب الكيماري المسرطن 7، 12- ديميثايل بنز (أ) أنتراسين في مئة علاجوم (ضفدع) استخدمت كمجموعة تجريبية شاهدة. كما كانت مشابهة للتغيرات التي تحدث في الكريات البيض في المرضى المصابين بابيضاض الدم. ونحن نوصي بتطبيق أنظمة رقابية على استعمال هذا المضاد الحيوي في البلدان التي مازال يستعمل فيها على نطاق واسع.

**ABSTRACT** Chloramphenicol has been associated with the development of aplastic anaemia. As it is still widely used in Egypt, we studied its effect on 100 Egyptian toads (*Bufo regularis*) given a dose of chloramphenicol of 5 mg/40 g body weight for 12 weeks. We found it induced numerous, severe ultrastructural changes in almost all types of leukocytes. These changes were similar to those induced by the chemical carcinogen 7,12-dimethylbenz(a)anthracene in 100 toads used as the carcinogen control group, and similar to those in leukocytes reported in humans with leukaemia. We recommend regulations be applied on the use of this antibiotic in countries where it is still widely used.

### Induction de la leucémie chez des crapauds traités au chloramphénicol

**RESUME** Le chloramphénicol a été associé au développement de l'anémie aplastique. Étant donné qu'il est encore très largement utilisé en Égypte, nous avons étudié son effet sur 100 crapauds égyptiens (*Bufo regularis*) avec une dose de 5 mg/40 g de poids corporel pendant 12 semaines. Nous avons constaté qu'il provoquait de nombreux changements ultrastructurels sévères dans presque tous les types de leucocytes. Ces changements étaient semblables à ceux provoqués par la substance carcinogène 7,12- diméthylbenz[a]anthracène chez 100 crapauds utilisés comme groupe témoin à titre expérimental ainsi qu'à ceux des leucocytes signalés chez les êtres humains atteints de leucémie. Nous recommandons que des réglementations soient appliquées à l'utilisation de cet antibiotique dans les pays où il est encore largement utilisé.

<sup>1</sup>Department of Zoology, Faculty of Science, University of Alexandria, Alexandria, Egypt.

Received: 12/08/99; accepted: 16/01/00

## Introduction

Chloramphenicol was first employed clinically for typhus fever [1]. The toxicity of chloramphenicol has been studied since the drug's introduction and the most serious hazard to man is bone marrow toxicity [2]. Administration of chloramphenicol has also been found to be associated with wild thrombocytopenia [3] and the development of aplastic anaemia [4]. It is well known that certain agents capable of producing aplastic anaemia in man can induce leukaemia [5].

Toads have been used as models to study the development of tumours in relation to carcinogens [6] and cocarcinogens [7]. It is worth mentioning that similarities between toad and human tumours have been reported [8]. The present work was undertaken to study the pathological effect of prolonged administration of chloramphenicol, which is widely used in Egypt, on the blood cells of the Egyptian toad.

## Materials and methods

Sexually mature male and female toads, *Bufo regularis*, (40 g each) were used. The animals were provided by a regular supplier. They were kept in large glass aquariums with small amounts of water that was changed twice daily and were fed earthworms once every 3 days.

The toads were divided into three groups of 100 (50 males and 50 females). Each toad of the first group (experimental) was force-fed 5 mg chloramphenicol in 0.5 mL amphibian saline daily for 3 months. This dose represents the human therapeutic dose. Chloramphenicol was obtained from Mistr Company for Pharmaceutical Industries, Mataria, Cairo, Egypt. Each toad of the second group (carcinogen control group) was force-fed 7,12-dimethylbenz(a)anthracene (DMBA) at a

dose of 0.5 mg twice a week for 3 months as described before [7]. DMBA was obtained from Sigma Chemical Company, St Louis, Missouri, United States of America. Toads of the third group (normal control group) were force-fed 0.5 mL amphibian saline daily.

## Haematological studies

Blood samples were obtained from the ventricle of the heart, and blood smears were fixed in methyl alcohol and stained with buffered Giemsa stain. Blood cells of all groups were examined for alterations by an oil immersion lens. Statistical analysis using the *t*-test was performed to determine the level of significant difference between blood alterations in toads treated with chloramphenicol or DMBA compared with the control group.

The blood of experimental and control groups (5mL, with 1% heparin) was centrifuged for 20 minutes at 1200 g. A white buffy coat was formed between red blood cells below and plasma above. After removing the plasma, 2.5% glutaraldehyde buffered with 0.1 M phosphate buffer was added. The buffy coat tube was allowed to stand for 18 hours at 4 °C. A 1 mm slice of the plug was cut into small pieces, post-fixed in 1% OsO<sub>4</sub>, washed in buffer, dehydrated in acetone, followed by propylene oxide and embedded in araldite. The sections were double stained with uranyl acetate and lead citrate and were examined under a Jeol × 100 electron microscope.

## Results

Administration of 5 mg chloramphenicol daily for 12 weeks or 0.5 mg DMBA twice per week for 12 weeks resulted in alterations in the peripheral blood of the treated toads (Table 1). No significant difference was found in the overall incidence of leu-

kaemia between the chloramphenicol group (21%) and the DMBA group (27%) ( $\chi^2 = 0.99$ ,  $P = 0.321$ ). Analysis for trend showed a significant slope for the chloramphenicol group ( $\chi^2 = 5.02$ ,  $P = 0.025$ ) and for the DMBA group ( $\chi^2 = 12.22$ ,  $P = 0.000$ ). Thus, in both groups the incidence of leukaemia tended to increase with time.

About 40% of the erythrocytes examined were at immature stages. They were highly vacuolized and showed rouleaux formation, anisocytosis and poikilocytosis (Figure 1). Examination of the stained blood smears after 12 weeks of treatment revealed a profound increase in the number of leukocytes with numerous mitotic figures. Most leukocytes present were granulocytes, mainly neutrophils, which were

present in different stages of maturation (Figure 1).

Ultrastructural studies of leukocytes of chloramphenicol-treated toads revealed several alterations, which involved both the nucleus and cytoplasmic organelles. Neutrophils with extensive segmented nuclei, invaginated nuclear envelope, abundant heterochromatin and numerous pleomorphic cytoplasmic granules and vacuoles were seen (Figure 2). Also basophils with numerous, pleomorphic granules were seen and the nucleus was eccentric (Figure 3).

Lymphocytes displayed some features of lymphocytic leukaemia; they had large, dark nuclei with abundant heterochromatin. The nucleus was convoluted and deeply invaginated with cytoplasmic materials.

Table 1 Effect of administration of chloramphenicol and DMBA on the peripheral blood of Egyptian toads after 12 weeks

Group <sup>a</sup>	Time elapsed after start of experiment (weeks)	Number of toads autopsied		Number of toads with leukaemia		Incidence of leukaemia (%)	Overall incidence <sup>b</sup>
		M	F	M	F		
Chloramphenicol-treated animals	2	5	5	0	0	0.0	21.0%
	4	6	6	1	0	8.3	
	6	6	6	2	1	25.0	
	8	8	8	2	1	18.8	
	10	12	13	4	2	24.0	
	12	13	12	3	5	32.0	
DMBA-treated animals	2	5	5	0	0	0.0	27.0%
	4	5	5	1	0	10.0	
	6	8	7	1	1	13.3	
	8	10	8	3	2	27.8	
	10	12	13	4	4	32.0	
	12	10	12	5	6	50.0	

<sup>a</sup>No leukaemia developed in the control group and therefore it was not included in the table.

<sup>b</sup>Comparison of overall leukaemia incidence showed no significant difference between the two groups ( $\chi^2 = 0.99$ ,  $P = 0.321$ ).

$\chi^2$  for slope for chloramphenicol = 5.02,  $P = 0.025$ .

$\chi^2$  for slope for DMBA = 12.22,  $P = 0.000$ .

DMBA = 7,12-dimethylbenz(a)anthracene.

The lymphocytes also showed a narrow perinuclear zone of cytoplasm with prominent cytoplasmic vacuoles, in addition to the fusion of their plasmalemma projections to form endocytic vesicles (Figure 4). Sézary-like lymphocytes and lymphocytes with totally cleaved nuclei and abundant heterochromatin were observed (Figure 3).

The nuclei of monocytes had a convoluted U- or W-shaped appearance; they were beset by invagination and occupied by

heterochromatin. The cytoplasm showed numerous pleomorphic granules, scant organelles and numerous endocytic vesicles (Figure 5).

Plasma cells of unusual shapes were seen in the chloramphenicol-treated toads. They had nuclei with abundant heterochromatin, swollen sacs of rough endoplasmic reticulum, large mitochondria with dense matrix and cytoplasm with numerous ribosomes (Figure 6).

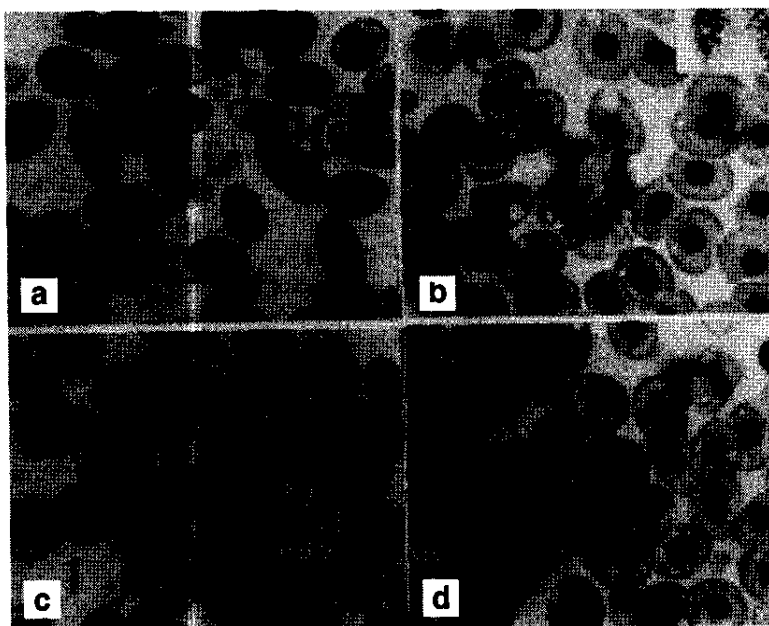


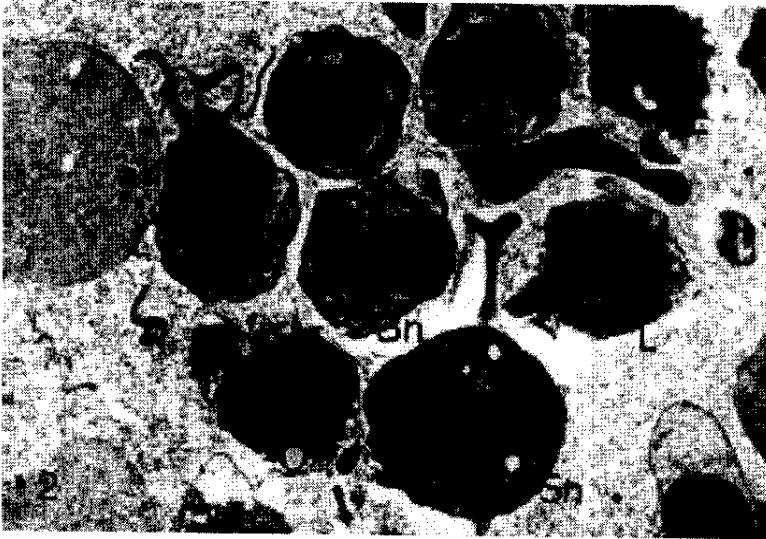
Figure 1 (a-d) Light micrographs of blood films of chloramphenicol-treated toads (Giemsa stain)

(a) Marked anisocytosis and polychromasia can be seen. Arrow points show "cigar-shaped" erythrocytes. Le: late erythroblast showing deformed shape ( $\times 1160$ )

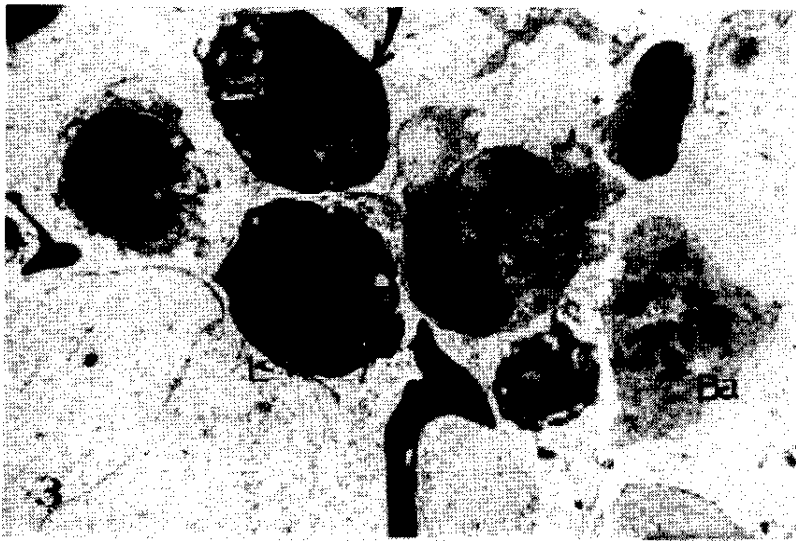
(b) Anaphase of mitotic division and prominent vacuolation of surrounding mature erythrocytes can be seen. ( $\times 1160$ )

(c) A non-granular segmented neutrophil can be seen. The nucleus shows a "pince-nez" configuration and the cytoplasm shows numerous vacuoles. ( $\times 1160$ )

(d) A band neutrophil can be seen showing two unsegmented nuclei enclosing cytoplasmic material. The surrounding erythrocytes contain numerous vacuoles. ( $\times 1160$ )



**Figure 2** Electron micrograph of peripheral blood of chloramphenicol-treated toads showing extensive segmentation, lobulation and hyperchromatism of nuclei in neutrophils and lymphocytes (L); Bn: band neutrophil; Sn: segmented neutrophil ( $\times 8000$ )



**Figure 3** Electron micrograph of peripheral blood of chloramphenicol-treated toads, showing basophils (Ba) containing large pleomorphic granules, Sezary-like lymphocytes (arrow) and a lymphocyte with cleaved nucleus (L) ( $\times 8000$ )

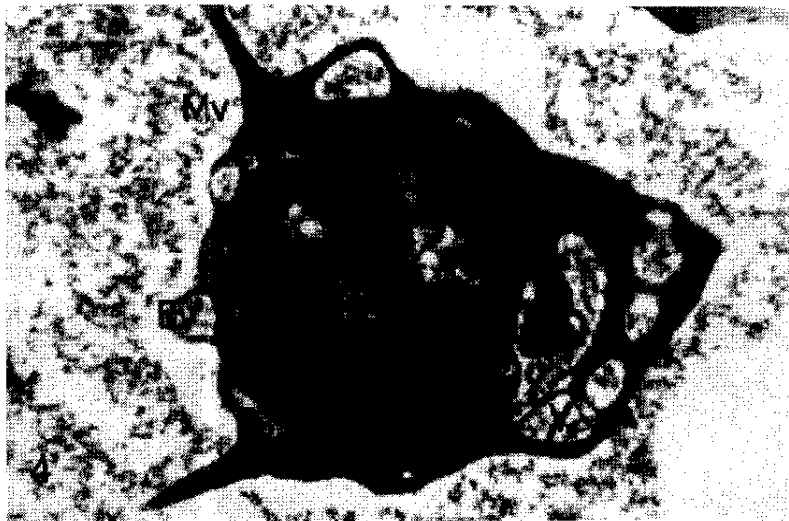
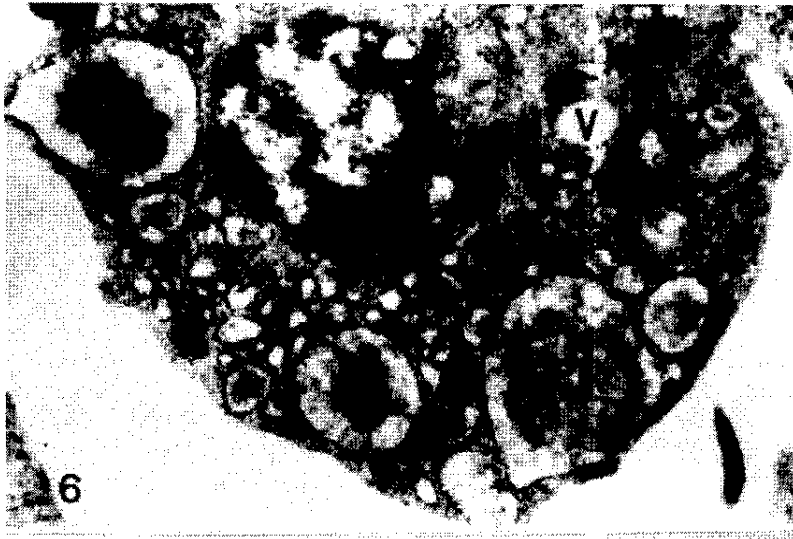
Figure 4 Electron micrograph of peripheral blood of chloramphenicol-treated toads which shows a lymphocyte with a deeply invaginated nucleus. Arrow points to nuclear vacuoles. Note the protrusion of microvilli (Mv) from the plasma membrane and the formation of endocytic vesicles from their fusion. G: granules (x20 000)



Figure 5 Electron micrograph of peripheral blood of chloramphenicol-treated toads showing a monocyte with a W-shaped nucleus and an amorphous inclusion (arrow); F: filopodia; G: granules; M: mitochondria (x18 000)



**Figure 6** Electron micrograph of peripheral blood of chloramphenicol-treated toads showing a plasma cell with abundant swollen cisternae of rough endoplasmic reticulum containing a grey matrix; M: mitochondria; V: vacuole (x20 000)

## Discussion

In our study, administration of chloramphenicol, or its carcinogenic control DMBA, was found to cause significant abnormality in the erythrocytes and leukocytes of Egyptian toads.

In the majority of erythrocytes, anisocytosis, poikilocytosis, polychromasia and vacuolization were observed. These defects are likely to occur in aplastic anaemia [9].

Leukocytes showed certain ultrastructural features that were similar to those of granulocytic leukaemic cells. Most cells showed irregularities in nuclear configuration, cytoplasmic vacuolation, pleomorphic granules, numerous ribosomes and a paucity of organelles. Lymphocytes showed round-to-indented nuclear profiles with abundant margined heterochromatin, cytoplasm with abundant free ribosomes and

plasma membrane with many protrusions and endocytic vesicles. Some lymphocytes were Sézary-like. Similar findings have been reported by Komiyama et al. in human acute leukaemia [10].

Monocytes in our study revealed indented, U- or W-shaped nuclei, ruffled cell surface and pleomorphic cytoplasmic granules. Similar features have been described by Ghadially [11] and Dickersin [12] in mammalian leukaemic monocytes, including human.

After chloramphenicol was introduced into clinical practice in 1948, it was soon associated with reports of aplastic anaemia [13]. Reversible bone marrow suppression has been observed in cats given chloramphenicol orally [14]. This lesion is a consequence of mitochondrial injury [15].

Because chloramphenicol inhibits the synthesis of mitochondrial proteins, impor-

tant membrane-associated enzymes become depleted, ultimately leading to suppressed mitochondrial respiration, compromised cellular synthetic machinery and a cessation of cellular proliferation [16].

## Conclusion

Chloramphenicol had a serious impact on the haematopoietic system of the Egyptian toad. These hazardous effects were similar to those induced by the potent carcinogen

7,12-dimethylbenz(a)anthracene. The leukaemic transformations that occurred in the leukocytes of toads are similar to those described by Ghadially [11] in leukaemic leukocytes of humans. Our findings should alert physicians to the possibility of an association of chloramphenicol with a therapy-related preleukaemia/leukaemia syndrome. Prospective investigations are required to re-evaluate the risk of leukaemia in countries where widespread use of chloramphenicol continues. Regulations concerning the use of chloramphenicol should be updated to prohibit its use.

## References

1. Payne EH, Knandt JA, Palacios S. Treatment of epidemic typhus with chloromycetin. *Journal of tropical medicine*, 1948, 15:68.
2. Rosenthal RL, Blackman A. Bone-marrow hypoplasia following use of chloramphenicol eye drops. *Journal of the American Medical Association*, 1965, 191(2):136-7.
3. Scott JL et al. A controlled double-blind study of the hematologic toxicity of chloramphenicol. *New England journal of medicine*, 1965, 272:1137-42.
4. Best WR. Chloramphenicol-associated blood dyscrasia. *Journal of the American Medical Association*, 1967, 201:99.
5. Vigliani EC, Sata G. Benzene and leukemia. *New England journal of medicine*, 1964, 271:872-6.
6. El-Mofty MM et al. The use of toads (*Bufo regularis*) in a new biological assay for screening chemicals or drugs which induce leukemia in man. *Oncology re-port*, 1997, 4:657-60.
7. Sadek IA, Abdul-Salam F. Effect of dietary fat on toad liver tumor induced by DMBA: ultrastructural studies. *Histology and histopathology*, 1994, 9:423-6.
8. Abdelmeguid NE et al. Ultrastructural criteria that prove the similarities between amphibian and human tumors. *Oncology*, 1997, 54(3): 258-63.
9. Thompson RB. *A short textbook of haematology*, 5th ed. London, The English Language Book Society and Pitman, 1983.
10. Komiya A et al. Unusual cytoplasmic inclusions in blast cells in acute leukemia. *Archives of pathology and laboratory medicine*, 1976, 100:590-4.
11. Ghadially FN. *Diagnostic electron microscopy of tumours*, 2nd ed. London, Butterworths, 1985.
12. Dickersin GR. *Diagnostic electron microscopy: a text/atlas*. New York, Igaku-Shoin Medical Publishers, 1988.
13. Aksoy M et al. Aplastic anemia due to chemicals and drugs: a study of 108 patients. *Sexually transmitted diseases*, 1984, 11(4 suppl.):347-50.
14. Watson ADJ, Middleton DJ. Chloramphenicol toxicosis in cats. *American jour-*



- nal of veterinary research*, 1978, 39: 119-203.
15. Yunis AA, Smith US, Restrepo A. Reversible bone marrow suppression from chloramphenicol. *Archives of internal medicine*, 1970, 125:272-5.
16. Yunis AA. Chloramphenicol toxicity: 25 years of research. *American journal of medicine*, 1989, 87(3N):44N-8N.

#### **Rational use of drugs**

Improving the use of drugs by prescribers, dispensers and the general public is crucial to reduce morbidity and mortality from both communicable and noncommunicable diseases, as well as to contain drug expenditure. Although most countries have essential drug lists and standard treatment guidelines, and a large proportion reports the existence of therapeutic committees and continuing education programmes, irrational drug prescribing, dispensing and self-medication continue to be major problems in most of the countries of the Region.

*Source:* The Work of WHO in the Eastern Mediterranean Region. Annual Report of the Regional Director. 1 January-31 December 2000. Pages 55-6.