

***In situ* characterization of B- and T-lymphocytes in basal cell carcinoma of the head and neck region**

Sanaa M.A. Saleh,¹ Azza A. El-Sissy² and Lawahez El-Sayed M. Ismail²

تميز اللمفاويات البائية والثائية في موضعها في سرطان الخلايا القاعدية بمنطقة الرأس والعنق
سناء محمود أنيس صالح وعزة عباس السيسي ولواحق السيد إسماعيل

خلاصة : تم فحص عشرين حالة من حالات سرطان الخلايا القاعدية بمنطقة الرأس والرقبة بطرائق مناعية نسيجية كيميائية من أجل اكتشاف اللمفاويات الثائية والبائية . وأظهرت النتائج أن الارتشاح اللمفاوي الكثيف الذي يحيط بالخلايا الورمية في سرطان الخلايا القاعدية ، يتكون أساساً من لمفاويات نائية . وفي بعض الأجزاء اتخذ الارتشاح اللمفاوي شكل جريب صغير من الخلايا اللمفاوية ، توجد الخلايا الثائية حول محيطه بينما تتركز الخلايا البائية في مركزه . إن هيمنة اللمفاويات الثائية في سرطان الخلايا القاعدية لتدل على حدوث تفاعل مناعي خلوي موضعي . ومن ناحية أخرى يشير وجود اللمفاويات البائية إلى احتمال حدوث تفاعل مناعي خلطي . وربما كانت الخلايا الثائية هي المسؤولة عن تنظيم تكاثر الخلايا الظهارية الحبيشة في سرطان الخلايا القاعدية وعن نموها بالتالي .

ABSTRACT Twenty cases of basal cell carcinoma (BCC) of the head and neck region were examined immunohistochemically for the detection of T- and B-lymphocytes. The results showed that the dense lymphocytic infiltrate surrounding neoplastic cells of BCC consisted chiefly of T-lymphocytes. The lymphocytic infiltrate revealed in parts a pattern of a small lymphocytic follicle with peripherally situated T cells and central B cells. The predominance of T-lymphocytes in BCC suggests a local cell-mediated immune response. However, the presence of B-lymphocytes indicates a possible humoral immune reaction. T cells may be responsible for regulating the proliferation, and thus the growth, of malignant epithelial cells in BCC.

La caractérisation *in situ* des lymphocytes B et T dans les carcinomes basocellulaires de la région de la tête et du cou

RESUME Vingt cas de carcinomes basocellulaires de la région de la tête et du cou ont fait l'objet d'un examen immunohistochimique pour la détection des lymphocytes T et B. Les résultats ont montré que les infiltrats lymphocytaires denses qui entourent les cellules néoplasiques des carcinomes basocellulaires étaient constitués principalement de lymphocytes T. Les infiltrats lymphocytaires présentaient, dans certaines parties, l'aspect d'un petit follicule lymphocytaire avec des lymphocytes T à la périphérie et des lymphocytes B au centre. La prédominance des lymphocytes T dans les carcinomes basocellulaires suggère une réponse immunitaire à médiation cellulaire locale. Toutefois, la présence de lymphocytes B indique une réaction immunitaire humorale possible. Les lymphocytes T pourraient être responsables de la régulation de la prolifération, et donc de la croissance, des cellules épithéliales malignes dans les carcinomes basocellulaires.

¹ Associate Professor, Oral Pathology Department, Faculty of Dentistry, University of Tanta, Tanta, Egypt.

² Associate Professor; ³ Lecturer, Oral Pathology Department, Faculty of Dentistry, University of Mansoura, Mansoura, Egypt.

Received: 22/04/96; accepted: 04/11/96

Introduction

Basal cell carcinoma (BCC) is a malignant epithelial neoplasm and is the most common cancer in the head and neck region. Although it is a slow growing tumour that rarely metastasizes, it is capable of causing extensive local tissue destruction [1]. It is primarily recognized as a skin neoplasm; however, occasional cases of BCC arising on the oral mucous membrane have been reported [2-4]. The tumour is most common on those parts of the skin exposed to sunlight, which is thought to be a possible etiological factor [1]. The majority of the reported cases arise on the face and neck, particularly on the nose, cheek and nasolabial fold [5].

BCC of the skin is generally believed to arise from the basal cell layer of the epithelium associated with epidermal adnexal structures. The origin of the oral cases is still uncertain, but the carcinoma is thought to arise from pluripotential cells in the basal layer or from heterotrophic sebaceous glands [2].

Lymphocytic infiltration of the tumour tissue in BCC is a commonly observed microscopic finding and is regarded as evidence of a "host versus tumour" immunological response [6,7]. It could be of importance to identify the immunologically competent cells among the mononuclear cell infiltration as they might signify an immunological reaction around the tumour. However, the *in situ* phenotype identification of the two main cells of the immune system cannot be reliably done on morphological grounds as they are morphologically identical [8]. Immunohistochemical techniques using monoclonal antibody recognition of B and T cells have been shown to solve this problem in various pathological conditions [9-11].

In order to gain more insight into the tumour-host relationship, the present study was conducted to characterize the *in situ* phenotype of the lymphocytic infiltrate surrounding tumour tissue of BCC through the use of monoclonal antibodies against B and T cell populations.

Materials and methods

Selection of cases

Twenty cases of BCC of the head and neck region were retrieved from the records of the Oral Pathology Department, Faculty of Dentistry, Tanta University and the Pathology Department, Faculty of Medicine, Mansoura University. The retrospectively studied cases were obtained from specimens that were conventionally embedded in paraffin blocks.

Sections of 3-4 µm thickness were deparaffinized, rehydrated and stained with haematoxylin and eosin (H&E) for re-evaluation.

Immunohistochemical staining

Sequential serial paraffin sections from each specimen were prepared for immunohistochemical staining using an avidin biotin-complex (ABC) technique [12].

Monoclonal antibodies

For each case, primary monoclonal antibodies directed against T- and B-lymphocytes diluted to 1:25 were applied to two separate slides.

Positive and negative controls

As positive controls, paraffin sections obtained from a case of inflamed hyperplastic lymphadenitis were used as a guide in evaluating any false negative results. Serial sections served as negative controls and were employed with each batch by omitting the

primary antibody and replacing it with non-immune swine serum to help evaluate any false positive results.

Results

The present study examined 20 cases of BCC (16 men and 4 women); the ages ranged from 38 to 73 years, with a mean age of 56.8 years. The lesions were found on the nose (9 cases), lower lip (5 cases), the region of the inner canthus of the eye (4 cases) and the cheek (2 cases).

Histopathological findings

The tumour tissue was chiefly composed of islands and strands of malignant epithelial cells invading the underlying connective tissue. The islands were formed of uniformly dark stained cells with basophilic cytoplasm. The peripheral cells often showed a palisading arrangement (Figure 1). Some cases revealed areas of cystic changes within the clumps of tumour cells (Figure 2). The connective tissue was infiltrated with mononuclear inflammatory cells containing scarce plasma cells (Figure 1).

Immunohistochemical findings

All cases of BCC included in the present study revealed positive staining with each of the employed markers separately, i.e. on two different slides. The positive immunostaining for either B or T phenotype was identified as a reddish-brown intracytoplasmic reaction product. The recognized B and T cells revealed variable distribution in the tissue involved. Positively stained cells for each phenotype were present at variable frequencies, which was evaluated according to an arbitrary semiquantitative method.

As summarized in Table 1, the positively stained T-lymphocytes identified were

Table 1 Semiquantitative evaluation of the relative frequency of B- and T- lymphocytes in the mononuclear infiltrate

Phenotype	+		++		+++	
	No.	%	No.	%	No.	%
B (n = 20)	14	70	6	30	—	—
T (n = 20)	—	—	3	15	17	85

+ = relatively rare reactive cells

++ = common

+++ = numerous

numerous in the mononuclear infiltrate in most of the cases examined (85%) (Figure 3), whereas the positively stained cells identified of the B cell phenotype were relatively rare in a large percentage of the cases (70%) (Figure 4).

The T-lymphocytes identified were found mainly as irregularly dispersed focal aggregates in between the tumour tissue (Figure 5); some aggregates were found in close proximity to tumour cells (Figures 6 and 7). T cells could frequently be detected interepithelially among the neoplastic cells (Figure 8). Wherever a follicular pattern of lymphoid tissue was found, the T cells were localized peripherally (Figure 5).

The positive B-lymphocytes were distributed in the form of a small aggregation in the connective tissue stroma (Figure 9). In some fields, the positively stained B cells were found as focal collections near to tumour tissue (Figure 10) or even the tumour islands (Figure 11). Among follicular collections of mononuclear cell infiltrations, the immunoreactive B-lymphocytes exhibited the central position (Figure 12).

Discussion

In the present study, the use of monoclonal antibodies by the immunohistochemical

technique made it possible to differentiate between T and B cells in the lymphocytic infiltrate in paraffin tissue sections. This is not possible with conventionally (H&E) stained sections.

The predominance of the T-lymphocytes over the B cell derived lymphocytes was the notable feature of the lymphocytic infiltrate in BCC. This suggests that the mononuclear cell infiltrate surrounding BCC represents mainly a cell-mediated immune response, as postulated in other studies [6,7,9,13,14].

These results are in agreement with studies of delayed hypersensitivity which have demonstrated a greatly reduced circulatory T cell population indicating depressed cell-mediated immunity in head and neck neoplasms [15]. The *in situ* T cell concentration might contribute to the relatively depleted circulation of the same cell type.

In light of the notion that ultraviolet light incident on the skin causes perturbation of the Langerhans cells and induces suppressor T cells [16], the T cell predominance could thus be explained as a cofactor in neoplasm development. Although the T cell subsets were not identified in the present work, the T cell predominance identified partially supports this view. If the predominant T cells were found to be of the T-suppressor subset, this might explain the scarcity of the B cells, as well as plasma cells, identified in the tumour tissue.

However, this supposition was not valid when applied to oral cases of BCC. A possible alternative etiological factor in these cases is based on the hypothesis that impairment of the immune system appears to permit the pathogenesis of skin cancer in immunodeficient patients [16]. However, clinical data concerning the immunological state of the patients did not allow confirmation of this hypothesis.

The detection of lymphocytes infiltrating the tumour islands interepithelially would not be possible without using the immunohistochemical technique. They could not be reliably distinguished from the densely packed tumour cells using H&E stained sections as both exhibit dense nuclei [14,17,18].

As reported by other investigators [19,20], the close proximity of T cells to the neoplastic epithelial cells suggests they could be considered as effector cells. This proposal is based on the previously reported findings that T cells expressing activation antigens were often in close proximity to tumour nests [9,19,20]. Moreover, the peripherally situated epithelial cells in many tumour nests have been shown to react to growth activation antigens secreted by T cells such as OKT9. Based on these data, it was supposed that the peripherally situated intraepithelial T cells might be playing a role in regulating the proliferative activity of peripheral epithelial tumour cells. It has been previously suggested that these tumour cells are responsible for tumour growth and proliferation within the nests [19,20].

A recent study of class II major histocompatibility (HLA-DR) antigen in BCC revealed a strong reaction to this antigen in neoplastic epithelial cells as well as in the inflammatory infiltrate, wherever they were in close proximity to each other [18]. It has been suggested that this may be evidence of the participation of T cells in a cellular immune response against the proliferation of BCC [18].

Although in this study B cells were less frequently observed than T cells, their presence might indicate a possible role of B cells in the immune reaction in the tumour-host relationship. This is in agreement with the idea that spontaneous

tumours may elicit antibody responses to tumour-associated antigens [21].

The identification of lymphoid follicles in some cases with the normal distribution of central B cells and peripheral T-lymphocytes might represent a partially organized immune reaction against tumour antigens [22]. Similar data have provided additional support for this suggestion [7].

Two mechanisms by which antibodies may participate in tumour cell destruction have been suggested. First, complement activation through complement-fixing antibodies that bind to the tumour cell membrane, leading to lysis of the tumour cell. An alternative mechanism of tumour cell destruction is antibody-dependent cell-mediated cytotoxicity by natural killer cells [8,23].

It has previously been reported that B-lymphocytes are among the wide spectrum of antigen-presenting cells as they can express major histocompatibility complex (MHC) class II molecules, which interact with T cell receptor cells and CD4 or CD4+ (helper) T cells. As antigen-presenting cells, they can bind to a specific antigen, internalize it and then degrade the antigen into peptides, which become associated with MHC class II molecules. These are the critical fragments involved in triggering T cells, i.e. causing their differentiation and proliferation. Since T cells cannot be triggered by free antigens, presentation of antigens is obligatory for induction of cell-mediated immunity [21].

The currently observed proximity of the B-lymphocytes to the tumour islands might represent the closeness essential for the performance of the above-mentioned mechanism.

Other investigators have reported that, with tumours induced by retroviruses, immunization with the virus can elicit an antibody response that protects against the

Figure 1 Photomicrograph of BCC showing islands of densely packed basoloid cells with prominent peripheral palisading. The connective tissue stroma in between the islands is infiltrated with mononuclear cell infiltrate (H&E x 100)

Figure 2 A: Photomicrograph of BCC showing cystic changes in association with solid islands (H&E x 40). B: Higher magnification showing the cystic changes in the tumour islands and the mononuclear cell infiltrate (H&E x 100)

Figure 3 Photomicrograph of BCC immunostained section of the T cell phenotype showing abundant T-lymphocytes. The positively stained T cells are distributed in the connective tissue stroma as focal collections in the stroma, perivascularly and in between the neoplastic epithelial cells of the tumour islands (ABC DAB x 40)

Figure 4 Photomicrograph showing BCC with scarce, positively immunostained lymphocytes of the B cell phenotype, represented as small aggregates (ABC DAB x 100)

Figure 5 Photomicrograph of BCC immunostained section showing positively stained lymphocytes of the T cell phenotype among the neoplastic epithelial islands. The positively stained cells were peripherally situated in the follicularly collected mononuclear cell infiltrate (ABC DAB x 200)

Figure 6 Photomicrograph of BCC immunostained section showing the close proximity of the identified immunostained T-lymphocytes to the tumour tissue (ABC DAB x 200)

development of tumours caused by the virus, but the antibody response contributes little to the control of tumours that have already been induced. However, antibodies that have minimal activity against the primary tumour can bind to circulating tumour cells and may interfere with the establishment of distant metastases [8].

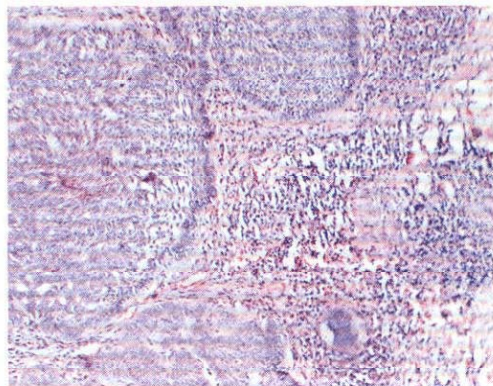


Figure 1

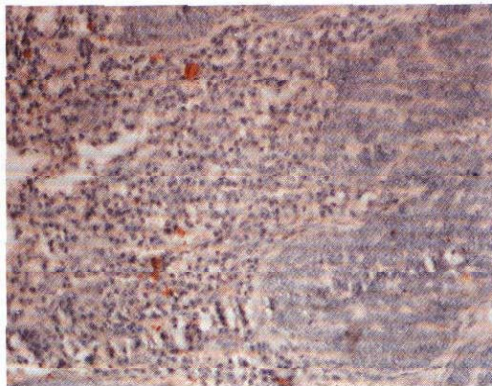


Figure 4

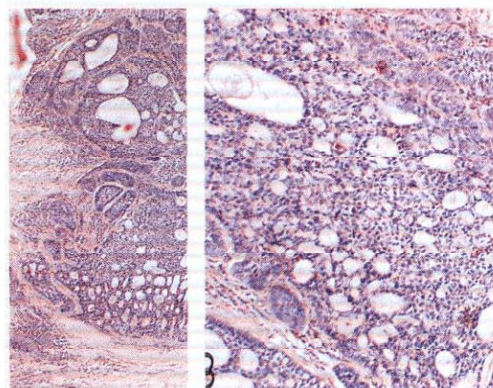


Figure 2 A

B

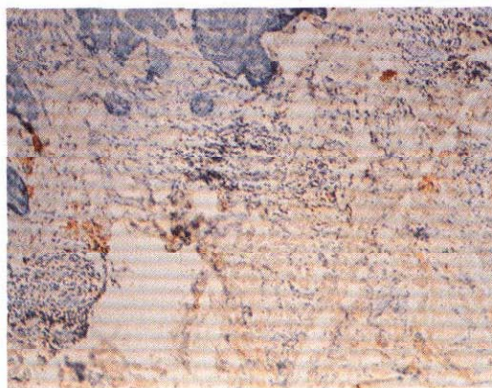


Figure 5

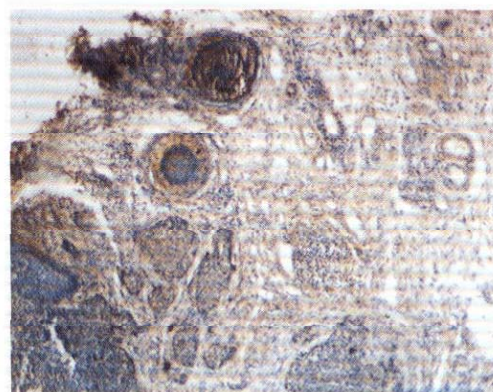


Figure 3

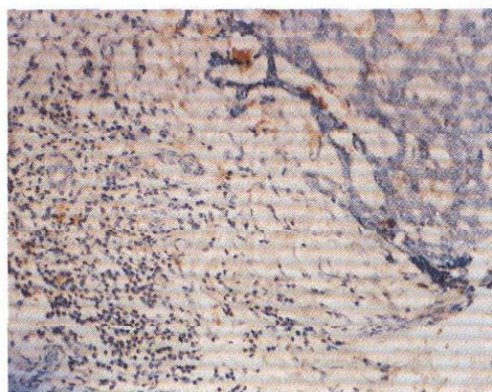


Figure 6

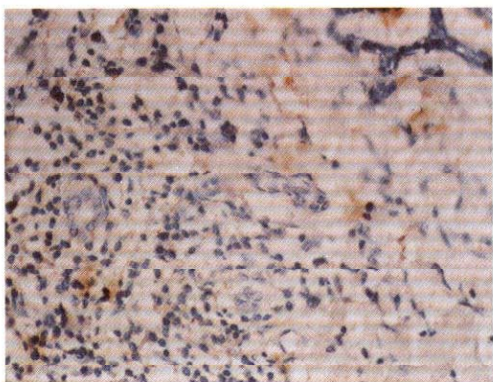


Figure 7



Figure 10

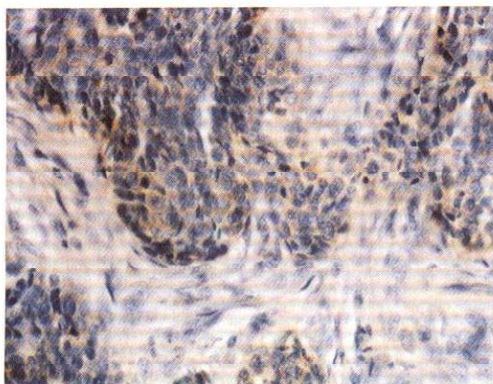


Figure 8

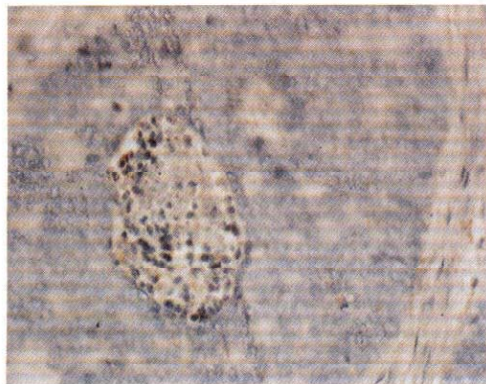

Figure 11

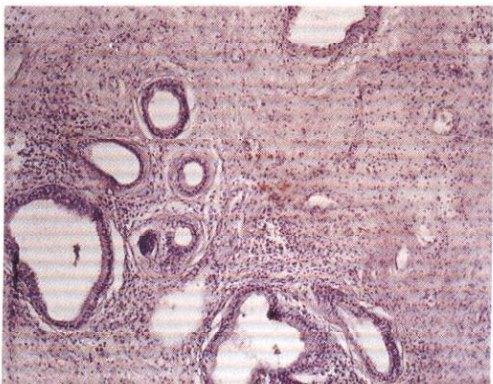


Figure 9

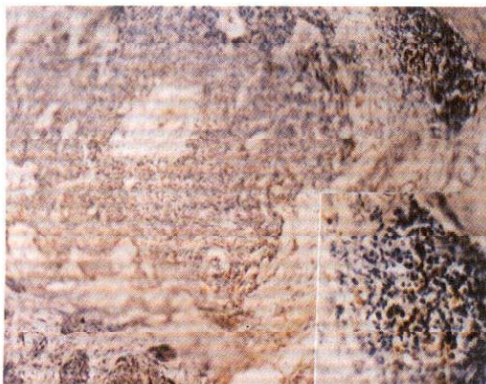


Figure 12

Figure 7 Higher magnification of the previous section showing the abundant T-lymphocytes among the mononuclear cell infiltrate in close proximity to the tumour islands (ABC DAB $\times 400$)

Figure 8 Photomicrograph of BCC immunostained section of the T cell phenotype showing interepithelially infiltrating T-lymphocytes among the neoplastic cells (ABC DAB $\times 400$)

Figure 9 Photomicrograph of BCC immunostained section (with cystic changes) showing occasionally positive lymphocytes of the B cell phenotype as small aggregates (ABC DAB $\times 100$)

Figure 10 Photomicrograph showing the positively stained B- lymphocytes in follicular mononuclear cell infiltrate near to the tumour islands of BCC (ABC DAB $\times 200$)

Figure 11 Photomicrograph of BCC immunostained section showing positively stained lymphocytes of the B cell phenotype among the neoplastic epithelial cells (ABC DAB $\times 200$)

Figure 12 Photomicrograph of BCC immunostained section showing positively stained lymphocytes of the B cell phenotype located centrally in the lymphoid follicle (ABC DAB $\times 100$). The inset is the higher magnification showing the centrally located B cells (ABC DAB $\times 400$)

Accordingly, the currently observed B-lymphocytes among the tumour islands might provide an explanation for the well known localized nature of BCC, being a slow growing tumour that is generally nonmetastasizing.

Conclusions

Twenty cases of basal cell carcinoma of the head and neck region were examined immunohistochemically for the detection

of both T- and B-lymphocytes with monoclonal antibodies.

The results showed that the dense lymphocytic infiltrate surrounding neoplastic cells of BCC consisted chiefly of T-lymphocytes. Fewer positive B-lymphocytes were found. In part, the lymphocytic infiltrate revealed a pattern of a small lymphocytic follicle with peripherally situated T cells and central B cells. Moreover, other patterns of distribution of both T and B cells were noticed in relation to epithelial neoplastic cells. Based on the results of the present work it might be concluded that:

- The *in situ* characterization of the lymphocytic infiltrate provided a further dimension to the exploration of the immune reaction in the tumour-host relationship in BCC.
- The predominance of T-lymphocytes in BCC suggests a local cell-mediated immune response.
- The presence of B-lymphocytes indicates that humoral immune reactions may also play an immunological role in such tumours which cannot be ignored.
- The T cells in close proximity to the neoplastic epithelial cells may be responsible for regulating the proliferation, and thus the growth, of such malignant epithelial cells in BCC.
- The B-lymphocytes detected *in situ* among the tumour islands might contribute to the localized, generally non-metastasizing nature of BCC.

Recommendations

1. Prospective studies of a larger sample of BCC are recommended to reveal the clinical relevance of the *in situ* characterization of the T- and B-lymphocytes.

2. Further studies are needed for *in situ* characterization of the T cell subsets among the T cells distributed in the tu-

mour tissue to elucidate further the tumour-host relationship.

References

1. Batsakis JG. Tumors of the head and neck. In: Headington JT, ed. *Epidermal carcinoma of the integument of the nose and ear*, 2nd ed. Baltimore, Williams and Wilkins Company, 1982:420.
2. Edmondson HD, Browne RM, Potts AJ. Intraoral basal cell carcinoma. *British journal of oral surgery*, 1982, 20:239-47.
3. Hume WJ, Turner EP. Basal cell carcinoma of lip mucosa. *British journal of oral surgery*, 1982, 20:248-55.
4. Van der Wal KG, Mulder JW, Betestra A. Basal cell carcinoma of the vermilion border of the upper lip. A case report. *International journal of oral surgery*, 1982, 11:77-9.
5. Allen AC. *The skin: a clinicopathological treatise*, 2nd ed. New York, Grune and Stratton, 1967.
6. Bustamante R et al. Immunoglobulin-producing cells in the inflammatory infiltrates of cutaneous tumors. Immunocytologic identification *in situ*. *Journal of investigative dermatology*, 1977, 68:346-9.
7. De Panfilis G et al. *In situ* identification of mononuclear cells infiltrating cutaneous carcinoma: an immunohistochemical study. *Acta dermatovener* (Stockholm), 1979, 59:219-22.
8. Stites DP, Stobo J, Wells JV. *Basic and clinical immunology*, 6th ed. Norwalk, Connecticut, Appleton and Lange, 1987: 14-17, 192.
9. Schoorl R et al. Identification of T and B lymphocytes in human breast cancer with immunohistochemical techniques. *American journal of pathology*, 1976, 84:529-44.
10. Lukle A et al. Quantitative analysis of the immunocompetent cells in periapical granuloma. *Journal of endodontology*, 1990, 61:119-23.
11. El-Sissy AA. *Immunohistochemical study of non-Hodgkin's lymphoma of the head and neck region* [PhD thesis]. Alexandria, Egypt, University of Alexandria, 1990.
12. Wranke R, Levy R. Detection of T and B cell antigens with hybridoma monoclonal antibodies. A biotin-avidin horseradish peroxidase method. *Journal of histochemistry and cytochemistry*, 1980, 28:1771-6.
13. Fernandez-Bussy R et al. T cell subsets and Langerhans cells in skin tumours. *European journal of cancer and clinical oncology*, 1983, 19:907-13.
14. Viac J, Bustamante R, Thivolet J. Characterization of mononuclear cells in the inflammatory infiltrate of cutaneous tumours. *British journal of dermatology*, 1977, 97:1-9.
15. Mason JM et al. T-lymphocytes and survival of head and neck squamous cell carcinoma. *Archives of otolaryngology*, 1977, 103:223-7.
16. Friedman RJ et al. *Cancer of the skin*. London, WB Saunders Company, 1991: 35-73.
17. Syukowski DR, Schuster P, Orlando JC. The immunobiology of basal cell carcinoma.

- noma: an *in situ* monoclonal study. *British journal of dermatology*, 1985, 113:441–6.
18. Zyada MM. *Human lymphocyte antigen HLA-DR expression on basal cell carcinoma of the head and neck region* [Thesis]. Mansoura, Egypt, Mansoura University, 1994.
 19. Guillen FJ et al. Expression of activation antigens by T cells infiltrating basal cell carcinomas. *Journal of investigative dermatology*, 1985, 85:203–6.
 20. Murphy GF et al. Local immune response in basal cell carcinoma: characterization by transmission electron microscopy and monoclonal anti-T6 antibody. *Journal of the American Academy of Dermatology*. 1983, 8:477–85.
 21. Roitt I. *Immunology*, 4th ed. London, Mosby, 1995:7.8–7.9.
 22. *Bloom and Fawcett: a textbook of histology*, 12th ed. London, Chapman and Hall Ltd., 194.
 23. Cotran RS et al. *Pathologic basis of disease*, 5th ed. London, WB Saunders Company, 1994:292–3.



World Health
Organization
Geneva



The first edition of this book, published in 1986, proposed a method for the relief of cancer pain, based on a few relatively inexpensive drugs, including morphine. Since then, the method has been tested and adopted in many countries around the world, providing pain relief to millions of cancer patients.

This second edition takes into account the advances in understanding and practice that have occurred since the mid-1980s. Each part of the book has been thoroughly revised and updated, and a new section added, describing the international system by which morphine and other opioids are made available to patients who need them. This part will be of interest not only to health care workers but also to drug regulators responsible for implementing the Single Convention on Narcotic Drugs at national level.

This publication can be ordered from Distribution and Sales Unit, World Health Organization, 1211 Geneva 27, Switzerland. Telephone: (22) 791 2476; Fax: (22) 791 4857.

Price: Sw.fr. 17.– / US\$ 15.30 (In developing countries: Sw.fr. 11.90)

It will be available in Arabic from the Regional Office for the Eastern Mediterranean in 1998.