

## Case report

# Amniotic constriction band sequence

A. Abu-Zeid<sup>1</sup> and H.E. Agrabawi<sup>1</sup>

## Introduction

Congenital constriction band sequence is a rare entity with a wide spectrum of associated congenital anomalies [1]. In this paper we present the case of a female neonate with amniotic constriction band, causing almost complete amputation of her right leg. We also review the pertinent literature.

## Case report

A full-term female neonate, a result of an uneventful pregnancy and normal vaginal delivery to a 24-year-old primigravida Jordanian mother is presented.

Her Apgar score was 9/10 and her anthropometric measurements were normal (head circumference 34 cm; weight 2.8 kg; length 48 cm). Physical examination showed multiple constriction bands causing severe deformity of her right leg and foot (Figures 1–3); otherwise she was free of deformity.

## Discussion

Morphogenesis is the complex process by which developmentally regulated genes form the structures necessary for survival. Birth defects are those abnormalities of morphogenesis that affect bodily function and integrity. They are evident in 2%–3% of infants and up to 7% of people later in

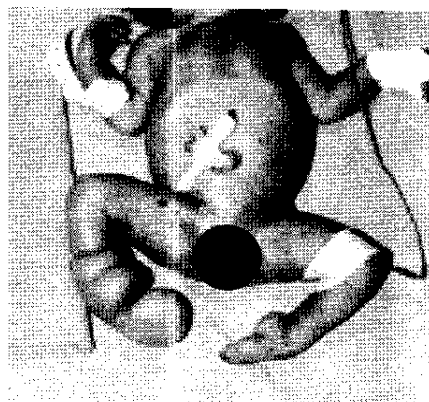


Figure 1 Female neonate with amniotic constriction band

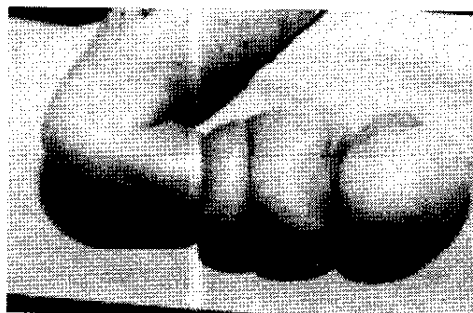



Figure 2 Right-leg deformity caused by amniotic constriction band

life, and are the leading cause of death in the first year of life [2].

<sup>1</sup>Neonatal Unit, Department of Paediatrics, King Hussein Medical Centre, Amman, Jordan.  
Received: 16/07/00; accepted: 06/03/01



**Figure 3 Right-leg deformity caused by amniotic constriction band**

Environmental factors that produce birth defects are called teratogens. Most birth defects are multifactorial, i.e. they are the product of genetic, environmental and developmental interactions. Single etiologic factors are recognized in only about 30% of cases [3]. Birth defects are etiologically classified as malformations, disruptions, deformations and dysplasias. Amniotic constriction band sequence is a good ex-

ample of deformation that results from extrinsic mechanical forces.

Rupture of the amniotic membrane in early gestation may lead to loss of fluid and entrapment of the developing conceptus. Early rupture is often associated with major structural abnormalities that are incompatible with life [4]. Later rupture may lead to complex deformations of the head and limbs or to amputation of structures by constricting amniotic bands. It may be difficult to distinguish these deformations from malformations unless the placenta is carefully examined for the presence of amniotic bands. If the head has escaped significant deformation, neurological development proceeds normally. The amniotic rupture sequence is a sporadic condition that occurs in approximately 1:1200 to 1:15 000 live births, and its recognition allows counselling for low recurrence risks [5]. Antenatal diagnosis using Doppler ultrasonography is now feasible and there are reported cases that have been successfully treated using novel minimally invasive surgical techniques prenatally [6,7].

### References

1. Paletta CE, Huang DB, Sabeiro AP. An unusual presentation of constriction band syndrome. *Plastic and reconstructive surgery*, 1999, 104:171-4.
2. Emery AEH, Rimoin DL, eds. *Principles and practice of medical genetics*, 2nd ed. Edinburgh, Churchill Livingstone, 1990.
3. Gorlin RJ, Cohen MM, Levin LS. *Syndromes of the head and neck*, 3rd ed. New York, Oxford University Press, 1990.
4. Woods T, Romansky N. Congenital constriction band syndrome. *Journal of the American Podiatric Medical Association*, 1995, 85:310-4.
5. Light TR, Ogden JA. Congenital constriction band syndrome. *Pathophysiology and treatment*. *Yale journal of biology and medicine*, 1993, 66:143-55.
6. Tadmor OP et al. Limb amputation in amniotic band syndrome: serial ultrasonographic and Doppler observations. *Ultrasound in obstetrics and gynecology: the official journal of the International Society of Ultrasound in Obstetrics and Gynecology*, 1997, 10:312-5.
7. Quintero RA et al. *In utero* lysis of amniotic bands. *Ultrasound in obstetrics and gynecology: the official journal of the International Society of Ultrasound in Obstetrics and Gynecology*, 1997, 10:316-20.