

# Primary Realignment of Posterior Urethral Rupture

Mehdi Salehipour, Abdolaziz Khezri, Rashid Askari,\* Parham Masoudi

*Department of Surgery, Division of Urology, Faghihi Hospital, Shiraz University of Medical Sciences, Shiraz, Iran*

## ABSTRACT

**Introduction:** We report the results of treatment of posterior urethral rupture (PUR) by primary realignment with some modifications of the technique.

**Materials and Methods:** In this prospective study, 25 patients (mean age, 33.5 years; range, 18 to 70 years) in whom PUR had been proved underwent primary urethral realignment. All patients were evaluated postoperatively for urinary incontinence, erectile dysfunction, and urethral stricture. They were followed for a mean of 20 months (range, 9 to 27 months).

**Results:** In 20 of 25 patients (80%), posterior urethral rupture was associated with pelvic fractures and in 2 (8%), bladder rupture was also present. None of the patients had urinary incontinence. Six patients (24%) had evidence of postoperative stricture that required urethral dilatation and/or direct vision internal urethrotomy in 2 or 3 procedures under local anesthesia. Erectile dysfunction was reported by 4 patients (16%) as a decreased quality of erection, all of whom responded to sildenafil.

**Conclusion:** We believe that primary realignment of PUR is a simple procedure associated with low morbidity. It is recommended for patients who are stable and have no other significant intra-abdominal and pelvic organ injuries.

**KEY WORDS:** urethra, urethral distraction, urethroplasty, injuries, primary realignment

## Introduction

Of patients with pelvic fractures, 4% to 14% also have posterior urethral rupture (PUR), which is associated with considerable morbidities such as incontinence, erectile dysfunction, and urethral stricture.<sup>(1)</sup>

Management of PUR continues to evolve. Some urologists advise initial placement of a suprapubic cystostomy followed by delayed urethroplasty 3 to 6 months later, while others suggest immediate realignment.<sup>(2)</sup> The definition of primary realignment of urethral distraction injury has changed over the years. The current definition of primary realignment refers to immediate stenting of urethral distraction with a catheter without pelvic dissection or suture.<sup>(3)</sup> In

the present study, we review our experience with primary realignment of PUR and report its outcome and complications.

## Materials and Methods

Between March 2002 and August 2004, there were 25 men (mean age, 33.5 ± 14.5 years; range, 18 to 70 years) with PUR due to injury who underwent primary realignment in our medical center. Posterior urethral ruptures were diagnosed and confirmed by history, physical examination, and retrograde urethrography. We prospectively selected those patients with no visceral injuries to undergo primary realignment.

**Surgical technique.** A lower midline abdominal incision is made. If the patient is hemodynamically stable with no other genitourinary tract injuries, a vertical cystotomy incision is made under direct vision, and a urethral Foley catheter is gently passed in a retrograde fashion. If the catheter is easily

Received January 2005

Accepted July 2005

\*Corresponding Author: Department of Urology,  
Faghihi Hospital, Zand Ave, Shiraz, Iran.

Tel: ++98 711 233 0724, ++98 711 235 5397,

Fax: ++98 711 233 0724

E-mail: rashidaskari@yahoo.com

brought into the bladder, its tip is sewn to the tip of a Nelaton catheter using a nonabsorbable suture, and the latter catheter is brought out from the bladder and the anterior abdominal wall and fixed to the abdominal wall. A suprapubic tube is placed in the dome of the bladder and the bladder is closed in 2 layers using a standard technique (Figure 1A).

If retrograde catheter placement fails, a 20-F Nelaton catheter is gently passed from the urethral meatus to the urethral disrupted area and the space of Retzius. A second 18-F Nelaton catheter is also gently passed from the bladder neck and the prostatic urethra to the disrupted area and the space of Retzius, in an antegrade fashion. The ends of these catheters are tied together, and the antegrade catheter is manipulated through the anterior urethra by pulling the retrograde catheter back to the urethral meatus. Subsequently, the antegrade catheter is secured to a Foley catheter by a nonabsorbable suture, which is then pulled back into the bladder. The antegrade catheter is brought out the anterior wall of the bladder and abdominal wall and fixed to the skin. The Foley catheter balloon is filled with 20 mL fluid. A suprapubic cystostomy tube is placed using a standard technique as previously described. No traction is applied on the Foley catheter.

The Foley catheter is left in place for 4 weeks and replaced by another one based on the guidance of the antegrade catheter. The Foley

catheter is retracted until the tip of the antegrade catheter are seen via the urethral meatus. The suture is removed from tips of both catheters, and a new Foley catheter is sewn to the tip of the antegrade catheter. The antegrade catheter is retracted through the bladder and the abdominal wall and removed by cutting the sutures (Figure 1B). The new Foley catheter is retracted gently while its balloon is filled with 20 mL fluid (Figure 1C). The new Foley catheter is left in place for another 4 weeks and removed when a retrograde urethrography around the Foley catheter shows no extravasation of contrast medium. The suprapubic cystostomy is clamped, but left in place. If the patient voids normally and without difficulty, the cystostomy tube may be removed 2 weeks later.

**Follow-up.** After the removal of catheters, the patients were followed at 3, 6, and 12 postoperative months with physical examination, uroflowmetry studies, and, if needed, retrograde urethrography and/or a voiding cystourethrography. Potency and continence were evaluated subjectively by interviews with the patients. Patients were considered *potent* if they were able to have intercourse with vaginal penetration. If the patients had decreased firmness of erection compared with the preinjury status, this was considered *decreased potency*. *Continence* was defined as no requirement to use a pad to protect against urine loss. Eventually, the need for additional urologic procedures was assessed.

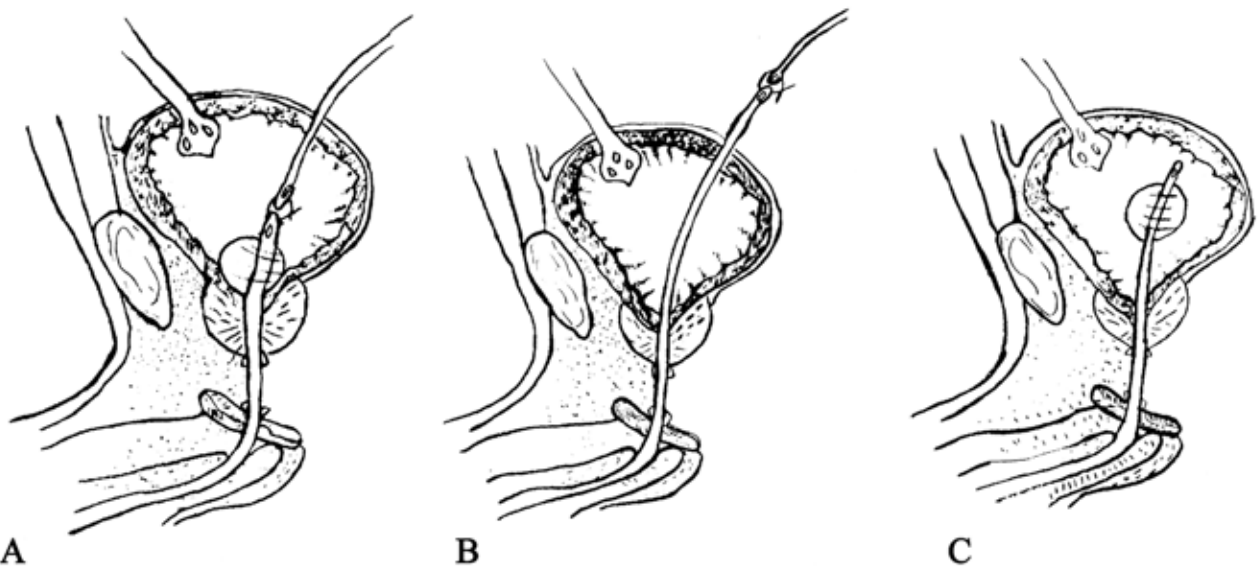


FIG. 1. Primary realignment of posterior urethral rupture, A. A 20-F Foley catheter is inserted, its tip is sewn to a Nelaton catheter, and cystostomy is placed. B and C. After 4 weeks, the Foley catheter is exchanged with another one, and the Nelaton catheter is retracted from the bladder and abdominal wall and removed. A Foley catheter is placed for another 4 weeks.

## Results

Mean follow-up was  $20.0 \pm 5.6$  months (range, 9 to 27 months). Twenty patients (80%) had pelvic fractures, and 2 (8%) had both pelvic fracture and bladder rupture. They had no visceral injury. All patients underwent surgical operation within 12 hours after injury. Twenty-one patients were followed for more than 12 months. The most common mechanisms of injury in our patients, in order of frequency, are shown in Table 1.

On follow-up, 19 patients (76%) had no symptoms or radiologic evidence of urethral stricture. All patients reported good urinary continence with no need for a pad. Six (24%) had strictures that were treated with urethral dilatation and/or direct vision internal urethrotomy. Of these, 3 patients required 3 procedures, and 3 required 2 procedures. None required open urethroplasty.

Twenty-one (84%) patients reported a normal erection, while 4 (16%) had decreased firmness of erection (all of which responded to sildenafil, 50 mg to 100 mg, daily).

The mean operative time for primary realignment was  $50 \pm 3$  minutes (range, 45 to 60 minutes). The estimated blood loss was 300 mL to 700 mL, and 3 patients received 500 mL blood transfusion.

**TABLE 1.** Mechanisms of posterior urethral rupture in 25 patients

Mechanisms of injury	Number of patients (%)
Car accident	12 (48)
Falling	5 (20)
Crushing	4 (16)
Motorcycle accident	3 (12)
Tractor rollover	1 (4)
<b>Total</b>	<b>25 (100)</b>

## Discussion

The PUR is one of the worst types of genitourinary trauma with 3 significant complications: erectile dysfunction, urethral stricture, and urinary incontinence. Management of PUR remains controversial. In the present study, we showed that primary realignment was

associated with no urinary incontinence, a low rate of erectile dysfunction, and a relatively low rate of urinary tract strictures that were treated successfully. Some studies have shown that initial suprapubic cystostomy and delayed urethroplasty, 3 to 6 months later produces less complication than does primary realignment, while other studies have shown the opposite.

In 1972, Morehouse and colleagues<sup>(4)</sup> reported high impotence and incontinence rates in patients treated with primary realignment. Webster and coworkers<sup>(5)</sup> have compared delayed urethroplasty and primary realignment in the treatment of PUR and noted a significant advantage with delayed urethroplasty. On the other hand, Follis and colleagues<sup>(6)</sup> have compared the operative outcomes of complete prostatomembranous disruptions in 20 men with delayed repair and 13 with immediate realignment. They reported potency rates of 50% and 80%, respectively, and an increased need for a secondary operation when the repair was delayed. Elliott and Barrett<sup>(3)</sup> analyzed the long-term (10-year) results of treatment of PUR with primary realignment in 57 men and showed that primary realignment resulted in low incidence of erectile dysfunction (21%, mostly mild), incontinence (3.7%), and stricture (34%, but with no requirement for intervention).

The main disadvantages of delayed urethroplasty are urethral stricture (in approximately 100% of patients<sup>(1)</sup>) and the need for a second operation with its potential complications such as impotence and incontinence. Conversely, primary realignment reduces the requirement for secondary open urethroplasty, and in addition, the majority of strictures can be treated with urethral dilatation and/or direct vision internal urethrotomy as an outpatient procedure. Compared with other studies,<sup>(3,6)</sup> the rate of urethral stricture in our study was relatively low. We think that the low urethral stricture rate is probably due to the minor modifications we made in our procedure. We connect the tip of the retrograde catheter to the tip of the antegrade Nelaton catheter for 2 reasons: first, because it can prevent unwanted disconnection of the retrograde catheter that acts as a stent and is important to the healing processes; and second, because passage of the Nelaton catheter after 4 weeks (when we change the retrograde Foley catheter with another one, while the antegrade catheter is connected to it)

may result in mild urethral dilatation.

Urinary continence depends on intact internal and external urethral sphincters. In PUR, the bladder neck is separated from the urethra, and so it seems that continence is dependant on the external sphincter function. During urethroplasty, the possibility of damage to the external urethral sphincter is high. Consequently, the rate of incontinence is higher than that in primary realignment. The reported rate of urinary incontinence with delayed urethroplasty has been 2% to 8%.<sup>(4,6)</sup> In 2 studies on primary realignment, urinary incontinence was present in 0% and 3.7% of the patients, and none of the patients in the latter study needed treatment.<sup>(3,6)</sup> We had no cases of incontinence. Thus, it seems that primary realignment can be done with no serious impact on the patient's continence. We speculate that this is due to less manipulation of the external sphincter during primary realignment and repair of bladder neck and prostatic urethra with a good exposure. In addition, we used no traction on the urethral Foley catheter, which prevents ischemic damage to the internal urethral sphincter, which is very important in maintaining continence.<sup>(7)</sup>

Causes of erectile dysfunction following PUR are not understood. Dhabuwala and associates have noted that impotence is caused by the original injury and is not due to the urethral repair.<sup>(8)</sup> In a report by Tunc and colleagues,<sup>(9)</sup> erectile dysfunction was attributed to delayed urethral reconstruction in 16.2% of patients. It is likely that injury to the autonomic plexus in

patients with pelvic fractures, or injury to the nervi erigentes in the neurovascular bundles dorsolateral to the prostatomembranous urethra contributes to erectile dysfunction.<sup>(6)</sup> In our study, no patient developed permanent erectile dysfunction, and 4 patients with decreased firmness of erection responded to sildenafil and gradually improved significantly. We suppose that minimal manipulation of pelvic viscera and a low incidence of hematomas contributed to the low rate of erectile dysfunction in our study. The complication rates of primary realignment in our study and some other studies are shown in Table 2.

### Conclusion

We believe that primary realignment of PUR is a simple procedure associated with low morbidity. This technique is useful for patients who are stable with no other significant intra-abdominal or pelvic organ injuries.

### Acknowledgement

We gratefully acknowledge Ms. Mersedeh Feradoni for her drawings in this article. We would also like to thank the Office of Research Development of Nemazee Hospital and Dr. Hooman Yarmohammadi for his editorial assistance.

### References

1. McAninch JW, Santucci RA. Genitourinary trauma, In: Walsh PC, Retik AB, Vaughan ED Jr, et al, editors. Campbell's urology. 8th ed. Philadelphia: WB Saunders; 2002. p. 3707-44.

**TABLE 2.** Results of primary realignment versus delayed urethroplasty of posterior urethral rupture in different studies

Study	Technique	Number of patients	Stricture No. (%)	Incontinence No. (%)	Erectile dysfunction No. (%)
Elliott and Barrett <sup>(3)</sup>	PR	57	18 (34)	2 (3.7)	12 (21)
Webster and colleagues <sup>(5)</sup>	PR	19	18 (95)	1 (5.2)	10 (53)
Follis and colleagues <sup>(6)</sup>	PR/DU	20/13	3/11 (15/85)	0/1 (0/8)	4/5 (20/39)
Tunc and colleagues <sup>(9)</sup>	DU	77	77 (100)	7 (9.1)	7/58 (16.2)
Patterson and colleagues <sup>(10)</sup>	PR	29	11(38)	1 (3.4)	4 (14)
Husmann and colleagues <sup>(11)</sup>	DU	17	16 (94)	2 (12)	8 (47)
The present study	PR	25	6 (24)	0 (0)	4 (16)

2. Koraitim MM. Pelvic fracture urethral injuries: the unresolved controversy. *J Urol.* 1999;161:1433-41.
3. Elliott DS, Barrett DM. Long-term follow-up and evaluation of primary realignment of posterior urethral disruptions. *J Urol.* 1997;157:814-6.
4. Morehouse DD, Belitsky P, Mackinnon K. Rupture of the posterior urethra. *J Urol.* 1972;107:255-8.
5. Webster GD, Mathes GL, Selli C. Prostatomembranous urethral injuries: a review of the literature and a rational approach to their management. *J Urol.* 1983;130:898-902.
6. Follis HW, Koch MO, McDougal WS. Immediate management of prostatomembranous urethral disruptions. *J Urol.* 1992;147:1259-62.
7. McAninch JW. Traumatic injuries to the urethra. *J Trauma.* 1981;21:291-7.
8. Dhabuwala CB, Hamid S, Katsikas DM, Pierce JM Jr. Impotence following delayed repair of prostatomembranous urethral disruption. *J Urol.* 1990;144:677-8.
9. Tunc HM, Tefekli AH, Kaplancan T, Esen T. Delayed repair of post-traumatic posterior urethral distraction injuries: long-term results. *Urology.* 2000;55:837-41.
10. Patterson DE, Barrett DM, Myers RP, DeWeerd JH, Hall BB, Benson RC Jr. Primary realignment of posterior urethral injuries. *J Urol.* 1983;129:513-6.
11. Husmann DA, Wilson WT, Boone TB, Allen TD. Prostatomembranous urethral disruptions: management by suprapubic cystostomy and delayed urethroplasty. *J Urol.* 1990;144:76-8.