

# Laparoscopic Cyst-Gastrostomy for Pancreatic Pseudocyst

Muhammad Shahid Shamim<sup>1</sup>, Farah Hanif<sup>2</sup>, Asra Hashmi<sup>2</sup> and Shumaila Muhammad Hanif<sup>2</sup>

## ABSTRACT

Pancreatic pseudocyst is a complication following resolution of pancreatitis. The optimum treatment for this condition has been under much debate. Laparoscopic surgery has changed the outlook of surgical management for the condition by reducing the operation related morbidity. The procedure has not been reported in local literature and is relatively new for the medical-surgical community. We report a case of pseudocyst gastrostomy and explain the procedure through laparoscopic approach.

**Key words:** *Pancreas. Pseudocyst. Cyst-gastrostomy. Laparoscopy.*

## INTRODUCTION

Pancreatic pseudocysts are the most common cystic lesions of the pancreas accounting for 75-80% of such masses.<sup>1</sup> Unlike true cysts, it is formed by walling off of areas of peripancreatic haemorrhagic fat necrosis with fibrous tissue as its capsule. Pseudocyst are formed as a result of localized collections of necrotic material rich in pancreatic enzymes: amylase, lipase and enterokinase.<sup>2</sup> It is most frequently located in the lesser sac in proximity to the pancreas. The most common etiologies for pancreatic pseudocyst include chronic pancreatitis, acute pancreatitis, gall stones and pancreatic trauma. In addition, it can be associated with pancreatic ductal obstruction and pancreatic neoplasm.

The incidence of pseudocyst formation following an episode of acute pancreatitis is lower, approximately 10-20%,<sup>3</sup> compared to as seen in 40-70% of patients undergoing surgical therapy for chronic pancreatitis.<sup>4</sup>

Many of these cysts do not require surgical intervention. They may resolve spontaneously in a significant number of patients. In patients with small (less than 6 cm) asymptomatic cysts, careful observation with periodic CT scans is indicated to monitor progressive resolution. In the era of minimally invasive surgery, laparoscopy has an emerging role in the management of pseudocyst of pancreas.<sup>5,6</sup>

We report on the application of a laparoscopic cyst-gastrostomy approach for internal drainage of pancreatic pseudocysts and discuss the merits of this technique. To the best of authors' knowledge, this

innovation in treatment of pseudo pancreatic cyst has not been published in local literature.

## CASE REPORT

A 55-year-old male chef, with not known comorbidities, presented to outpatient with complaints of mass in upper abdomen since three months, associated with nausea, recent onset of vomiting after every meal and significant weight loss. Six months ago, he had an episode of acute pancreatitis, for which he was admitted and underwent open cholecystectomy prior to discharge. Examination revealed a generous right subcostal incision scar and approximately 6x6 cm globular mass in the epigastrium. Computed tomography confirmed the clinical diagnosis of pseudo pancreatic cyst in the region of lesser sac (Figure 1).

After counseling and pre-operative work-up, laparoscopic cyst-gastrostomy was performed. Procedure was carried out in with patient under general anaesthesia, was completely paralysed with endotracheal intubation. A 10 mm supraumbilical camera port was made by open technique and pneumoperitoneum was created. After a thorough inspection of peritoneal cavity, patient was placed in reversed trendelenburg position with legs apart in extended lithotomy. Operating surgeon stood between patient's legs, while camera assistant on patient's right and another assistant stood on the left side of patient. Two 5 mm working ports were then made under direct vision, one each in right and left mid-clavicular line, approximately 8 cm below costal margin. Two more 5 mm ports were made for retraction in right and left lumbar region. Approximately 5 cm incision was made in long axis of anterior gastric wall using harmonic (ultrasonic) scalpel. Bulging posterior wall of stomach was identified (Figure 2). A percutaneous needle was used to localize the position of pseudocyst (Figure 3) prior to incising the posterior gastric wall over the cyst

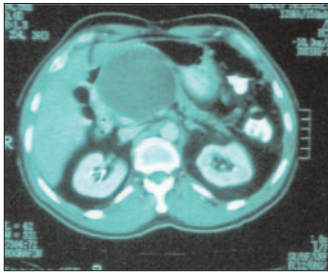
<sup>1</sup> Department of Surgery, Dow University of Health Sciences, Karachi.

<sup>2</sup> Student, Dow University of Health Sciences, Karachi.

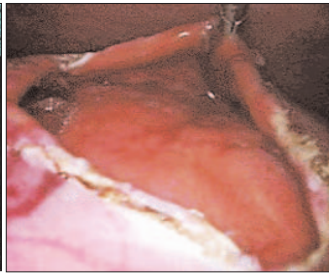
**Correspondence:** Dr. Muhammad Shahid Shamim, B-122, Block-T, North Nazimabad, Karachi-74700.

E-mail: doctsaab@yahoo.co.uk

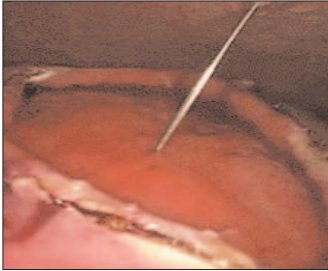
Received July 22, 2008; accepted May 8, 2009.



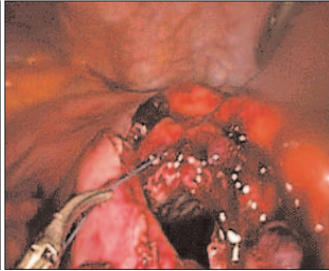
**Figure 1:** CT scan showing pancreatic pseudocyst.



**Figure 2:** Laparoscopic view of posterior wall of stomach after anterior gastrotomy. Cyst is seen bulging from behind the stomach.



**Figure 3:** Percutaneous aspiration of cyst to locate position.



**Figure 4:** Intracorporeal suturing of cyst wall with posterior gastric wall.

using ultrasonic (harmonic) scalpel. The 3 cm incision was then deepened into the cyst wall. Laparoscope was passed into the cyst cavity for inspection of contents and any possible communications. None were found. The cyst was behind the lower half of distal stomach wall. Cyst wall and posterior gastric wall was then sutured together by continuous intracorporeal stitches using vicryl 2/0 (Figure 4). A nasogastric tube drain was passed by the anaesthetist, tip of the tube was placed into the pseudocyst cavity through the cyst-gastrostomy. Anterior gastric wall was closed in two layers using vicryl 2/0 intracorporeal sutures. Peritoneal cavity was washed with 500 ml of 0.9% saline, which was sucked dry before finishing the procedure. Facial layer was closed in supraumbilical port using vicryl "0" on J-needle after CO<sub>2</sub> was allowed to escape from the peritoneal cavity. All skin incisions were sutured with vicryl rapide.

Recovery and postoperative course of patient was uneventful. Patient was fully mobilized in 24 hours. Nasogastric tube was removed after 48 hours and patient started on oral liquids. He was discharged on 6th postoperative day on oral proton pump inhibitors and analgesics as needed. All medications were stopped in two weeks time and the patient resumed his work.

On 6 month follow-up, patient had no complains, gained weight and the port sites were hardly visible on his abdominal wall.

## DISCUSSION

Pancreatic pseudocyst is not an uncommon observation in general surgical practice. Optimum treatment for this

diagnosis has been under much debate. Bradley *et al.* reported that spontaneous resolution occurred in 42% of patients who developed pseudocyst for less than 6 weeks.<sup>6</sup> However, only 8% of patients, whose pseudocyst persisted for 7 to 12 weeks, had spontaneous resolution. If a pseudocyst is persistent over months or causing symptoms then intervention for treatment of the cyst is required.

The fundamental principle of pseudocyst treatment is its drainage. This is accomplished by various approaches including percutaneous drainage under radiological guidance, endoscopic internal drainage and surgical drainage are those more commonly employed by different workers in the field. Each of the techniques has their merits and demerits with potential complications.<sup>6-8</sup>

Surgical treatment has been the traditional approach and is still the preferred treatment in most centers. Advent of minimal access laparoscopic surgery has modified the concepts of incision related surgical morbidities, historically associated with abdominal procedures. Laparoscopic cyst-gastrostomy for pseudo pancreatic cyst follows the principle of its open counterpart with added benefits of minimal access. These benefits include minimum early postoperative pain and difficulty in breathing due to the absence of comparatively larger upper abdominal incision required for open cyst-gastrostomy, less likelihood and magnitude of potential wound related complications and better cosmetic scars. A variety of laparoscopic approaches to pseudocyst management have appeared in literature.<sup>5,6</sup> One of the advancing techniques is to perform a gastrostomy laparoscopically followed by a cyst gastrostomy via the posterior gastric wall. This has been an effective means of drainage and can be performed with a laparoscopic gastrointestinal stapler or intracorporeal suturing techniques. It does require a generous anterior gastrostomy, which must be closed.

This patient, a skilled worker, belonged to low socioeconomic group and highly appreciated the early return to his daily activities and work. Cost of the procedure, an important issue especially in the third world countries, was also looked into at the time of planning treatment. It was observed that cumulative cost did not exceed significantly as the anastomosis was performed with intracorporeal sutures instead of exorbitantly expensive laparoscopic gastrointestinal staplers.

It is not only a safe procedure in expert hands, but also achieves adequate internal drainage with minimum morbidity and early return to work.

## REFERENCES

1. Kloppe G. Pseudocysts and other non-neoplastic cysts of the pancreas. *Semin Diagn Pathol* 2000; 17:7-15.

2. Lowenfels AB, Maisonneuve P, DiMagno EP, Gates LK Jr, Perrault J, Whitcomb DC. International Hereditary Pancreatitis Study Group. Hereditary pancreatitis and risk of pancreatic cancer. *J Natl Cancer Inst* 1997; **89**:442-6.
3. Heider R, Meyer A, Galanko JA, Behrns KE. Percutaneous drainage of pancreatic pseudocysts is associated with a higher failure rate than surgical treatment in unselected patients. *Ann Surg* 1999; **229**:781-9.
4. Morel P, Rohner A. Surgery for chronic pancreatitis. *Surgery* 1987; **101**:130-5.
5. Bhattacharya D, Ammori BJ. Minimally invasive approaches to the management of pancreatic pseudocysts: review of the literature. *Surg Laparosc Endosc Percutan Tech* 2003; **13**:141-8.
6. Aljarabah M, Ammori BJ. Laparoscopic and endoscopic approaches for drainage of pancreatic pseudocysts: a systematic review of published series. *Surg Endosc* 2007; **21**: 1936-44.
7. Bradley EL, Clements JL Jr, Gonzalez AC. The natural history of pancreatic pseudocysts: a unified concept of management. *Am J Surg* 1979; **137**:135-41.
8. Pitchumoni CS, Agarwal N. Pancreatic pseudocysts. When and how should drainage be performed? *Gastroenterol Clin North Am* 1999; **28**:615-39.

.....★.....