

Axillary Lymph Node Metastases as The Sole Clinical Site of Occult Breast Carcinoma

Dimitrios M. Dragoumis, Aris P. Tsiftoglou, Aikaterini D. Sikou and Anthoula S. Assimaki

ABSTRACT

Patients without evidence of breast disease, who present with axillary lymph node metastases, consistent with breast origin, comprise a diagnostic and therapeutic dilemma.

We describe such a case of a 47-year-old female, who complained of swelling and pain of the left axilla, but no breast mass was palpable. Although histology identified a metastatic adenocarcinoma in the lymph nodes, numerous tests failed to detect the primary tumor. Immunohistochemistry showed that the resected lymph nodes were positive for both estrogen and progesterone receptors, CEA and Gross Cystic Disease Fluid Protein 15 (GCDFFP-15), suggesting the breast as the site of the primary tumor. Left modified radical mastectomy was performed. Pathology revealed an invasive ductal carcinoma, 12 mm in size. The patient received adjuvant chemotherapy and radiation therapy. She is currently being treated with tamoxifen and is well without evidence of disease 2 years after surgery.

Key words: Breast cancer. Occult breast cancer. Axillary lymph node metastasis.

INTRODUCTION

Most patients with isolated axillary adenopathy have a benign aetiology. Histology of the excised node will generally allow a specific diagnosis of lymphoma, melanoma or adenocarcinoma to be made with some certainty. Electron microscopy and special stains (such as mucicarmine or lactalbumin) may be particularly helpful in differentiating adenocarcinoma from other malignancies by demonstrating ultrastructural features characteristic of secreting glandular epithelium. A firm diagnosis of adenocarcinoma in this setting supports a presumption of occult carcinoma of the ipsilateral breast in more than 90% of females.¹

Axillary lymphadenopathy from an occult breast cancer is an uncommon presentation, accounting for 0.3-1% of all breast cancers. Despite the use of advanced diagnostic techniques, such as mammography, ultrasonography, and even magnetic resonance imaging, an axillary metastasis without an obvious primary tumor remains a difficult diagnostic and therapeutic challenge. For these cases, the traditional therapeutic strategy has been upper outer quadrantectomy or blind mastectomy with axillary lymph node dissection, with or without radiation. However, in a significant number of patients (33.3%) who had undergone upper outer quadrantectomy or blind

mastectomy, the primary tumor may not be found in the breast specimen.²

This report describes the case history with diagnostic and therapeutic implications of this unusual entity.

CASE REPORT

A 47-year-old woman was admitted complaining of a painful mass in left axilla. She had first noticed this tender nodule one month ago. Antibiotic and anti-inflammatory medication was administered and led to a temporary remission. During this period, she also suffered a second degree cutaneous burn injury of her left hand. Her family and medical history was unremarkable, except for thyroxin intake, due to mild hypothyroidism. Menarche had occurred at the age of 12 years, whereas the menstrual cycle had been normal and regular. She was nulliparous and had two induced abortions. She had also undergone hormone replacement therapy for approximately 3 years.

On physical examination, there was no palpable mass in the left breast, no nipple discharge and no sign of infection in the left arm. There was clinical left axillary lymphadenopathy, approximately 3cm in diameter. Thorough physical investigation, with special attention to other nodal regions, excluded generalized lymphadenopathy, whereas examination of breast, thyroid, abdomen and pelvic region did not lead to a definite diagnosis.

Since the patient denied fine needle aspiration cytology, excisional biopsy of the left axillary mass was performed under local anesthesia. The histological essay revealed metastatic adenocarcinoma in four lymph nodes, composed of solid and cribriform neoplastic cells with

Department of General Surgery, Breast Division, St. Luke's Hospital, Panorama, 55 236, Thessaloniki, Greece.

Correspondence: Dr. Dimitrios M. Dragoumis, I. Michail 7, 54 622, Thessaloniki, Greece.

E-mail: ddragoumis@gmail.com

Received April 16, 2008; accepted June 26, 2008.

high mitotic index (Figure 1). Breast cancer was initially suspected as the primary focus. However, mammography, ultrasonography and breast Magnetic Resonance Imaging (MRI) failed to document any pathologic abnormalities of disease, except for the left axillary lymphadenopathy (Figure 2). Serum levels of Carcinoembryonic Antigen (CEA), carbohydrate antigen 15-3 (CA15-3), carbohydrate antigen 19-9 (CA 19-9), cancer antigen 125 (CA 125), and alpha-fetoprotein (AFP) were within normal ranges. Further examinations consisting of a full blood count, serum kidney and liver functions, computed tomography of the abdomen and isotope bone scan did not retrieve any conclusive result. Chest MRI documented the presence of multiple oval masses (2 cm in size) in the left axilla, but there were no abnormal findings in the lungs. Immunostaining of the four resected lymph nodes produced positive results for the Estrogen Receptors (ER), Progesterone Receptors (PR), Androgen Receptors (AR), CEA, p53, Ki-67, cytokeratin 7 and Gross Cystic Disease Fluid Protein 15 (GCDNF-15). Based on these findings, it was concluded that the axillary lymph node metastases were caused by occult breast cancer.

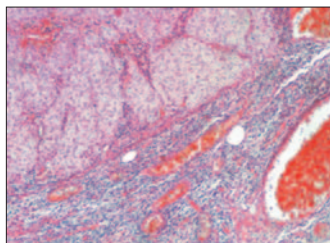


Figure 1: Histologic section of axillary lymph node showing carcinoma cells arranged in a solid and cribriform pattern, with high mitotic index. (Haematoxylin and Eosin stain; original magnification x 200).

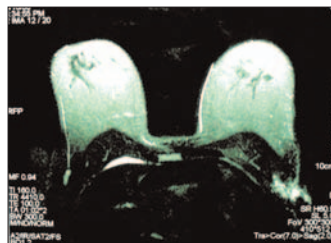


Figure 2: Breast MRI fails to identify the breast origin of the left axillary lymphadenopathy (arrow).

It was, therefore, decided to perform a left modified radical mastectomy, after obtaining informed consent from the patient. Histopathological examination of the left mastectomy specimen revealed a tumoral lesion, measuring 12 mm in the upper outer quadrant, which was recorded as a grade III, infiltrating ductal carcinoma of the stellate type with complex glandular growth pattern. Seven of the twelve resected lymph nodes contained metastatic deposits. On immunohistochemical analysis, the neoplastic cells of the left breast lesion expressed 90% ER positivity, 60% PR positivity and did not express Her2/neu protein. This result was consistent with the receptor status found in the left axillary lymphadenopathy.

In view of these facts, adjuvant treatment was considered necessary in the presence of metastatic spread of disease. After surgery, 4 courses of Cyclophosphamide, Epirubicin (EC regimen) and 4 courses of Paclitaxel were administered and

subsequent radiation therapy to the left chest and left supraclavicular area (25 courses of 5000 cGy) was performed. The patient is currently receiving adjuvant hormone therapy (Tamoxifen). Postoperative follow-up is satisfactory to date and 24 months after surgery, she remains well, without any signs of tumor recurrence.

DISCUSSION

An isolated metastatic axillary lymph nodes without an apparent breast tumor is a challenging problem of diagnosis and treatment for breast surgeons and oncologists. For these patients, the source of the carcinoma most often originates from breast tissue, but it is difficult to determine how extensive an investigation should be performed, in order to exclude other areas as the possible site of the metastatic disease. Malignant neoplasms of other organs known to metastasize to the axillary nodes include melanomas and carcinomas of lung, thyroid, stomach, colon, rectum, pancreas and ovaries. However, these metastases are rarely the first signs of disease. In 1907, Halsted first described three such patients with clinically normal breasts and metastatic axillary lymph nodes.¹⁻³

Since occult primary breast cancer is a rare condition, its management is unlikely ever to be determined by randomized trials. With the use of breast MRI and modern imaging modalities, its incidence is likely to reduce even further with time.²

A fine-needle aspiration biopsy or core biopsy can be performed as the initial diagnostic test. A negative result does not exclude a malignancy and, therefore, an excisional biopsy may be necessary. Magnetic resonance imaging has a high sensitivity for the detection of breast cancer, ranging from 88 to 100%. Reports have documented an identification rate of 70 to 86% of occult primary tumors in the breast with contrast-enhanced MRI. The technique is not without its limitations and still has a percentage of false-positive and scarce false-negative results. The magnitude of breast density does not seem to limit the efficacy of breast MRI. In fact, MRI may reveal occult lesions even in breast tissue that appears mildly dense mammographically. In this case, false-negative breast Magnetic Resonance Imaging (MRI) failed to identify a 12 mm invasive ductal cancer. Although rare, one limitation of breast MRI is that the lack of vascular enhancement of a neoplasm may lead to an inability to differentiate the tumor from surrounding breast parenchyma.^{4,5}

Positron Emission Tomography (PET) has been successfully used in the detection of occult breast carcinoma and holds promise in the diagnosis of the primary tumor in these challenging cases, particularly in women with radiodense breasts. There is also evidence that breast scintimammography may be a useful,

inexpensive and practical diagnostic tool in the evaluation of the patient with occult breast cancer, but experience with this modality is still limited.^{1,3}

Positive results of oestrogen and progesterone are suggestive of breast cancer, and this occurs in approximately 50% of females. However, negative ER/PR staining does not exclude the diagnosis of breast cancer and it is important not to forget that other carcinomas (i.e. cancer of the colon, ovary, endometrium, kidney and melanoma) may show detectable ER/PR expression. Kaufmann *et al.* studied the possibility of differentiating metastatic breast carcinomas from other metastatic adenocarcinomas immunohistochemically. They demonstrated that the sensitivity and specificity of ER expression in breast carcinoma compared with all other carcinomas were 0.63 and 0.95, respectively. They also documented the diagnostic value of GCDFP-15 protein, which is a marker of apocrine differentiation. The sensitivity and specificity of GCDFP-15 expression were 0.98 and 0.62, respectively. In addition, the combination of GCDFP-15 and ER had a sensitivity of 0.83 and a specificity of 0.93 for carcinomas of the breast.⁶ The mammaglobin antibody is another sensitive marker of breast carcinomas. Bhargava *et al.* recently reported that the sensitivity of mammaglobin is better than that of GCDFP-15, but it lacks the specificity of GCDFP-15. Mammaglobin expression is not altered at the metastatic lymph node site and can help, in combination with other markers, to establish the correct diagnosis of metastatic breast carcinoma.⁷ In this patient, immunohistochemical analysis was performed using the Envision method and positive expression of ER, PR, GCDFP-15 and CEA strongly warranted the presence of ipsilateral occult breast carcinoma.

There is no clear consensus regarding optimal treatment of occult breast cancer. Patients with axillary metastases consistent with breast carcinoma should be treated identically to those with the same features and a proven primary breast neoplasm. This clinical entity has been managed differently by observation, upper outer quadrantectomy, radiotherapy to the breast and mastectomy.⁸ Data from larger studies eventually revealed an unacceptable outcome in patients, who only had a "wait and see" therapeutic approach. A blind upper outer quadrantectomy was first described by Feigenberg *et al.* but these efforts failed to lead to a better outcome. Arguments can be made both for and against whole breast radiation and mastectomy. Literature does not clearly support the overwhelming

use of one or the other. However, with whole breast radiation, the breast is preserved and the survival rates would surely support its use as an alternative to mastectomy. Patients can also be spared the trauma of having a mastectomy in the absence of a clearly defined malignancy.⁸

The traditional therapy of choice was radical or modified radical mastectomy. However, several recent studies have shown no statistically significant differences in outcome between mastectomy and more conservative treatments, such as limited resection or radiation.⁹ These data suggest that breast-conserving surgery is an optimal alternative for the treatment of occult breast cancer. In this case, the patient chose a modified radical mastectomy and a 12 mm infiltrating ductal carcinoma was found in serial sections of the total resected specimen. It is essential not to overlook that patients, who face the dilemma of this condition, must be fully informed about this complicated health issue, so that they can actively participate in the decision-making process and choose proper therapeutic approach.^{1,8,9}

REFERENCES

1. Sakorafas GH, Tsiotou AG. Occult breast cancer: a challenge from a surgical perspective. *Surg Oncol* 1999; **8**:27-33.
2. Abe H, Naitoh H, Umeda T, Shiomi H, Tani T, Kodama M, *et al.* Occult breast cancer presenting axillary nodal metastasis: a case report. *Jpn J Clin Oncol* 2000; **30**:185-7.
3. Matsuoka K, Ohsumi S, Takashima S, Saeki T, Aogi K, Mandai K. Occult breast carcinoma presenting with axillary lymph node metastases: follow-up of eleven patients. *Breast Cancer* 2003; **10**: 330-4.
4. Ko EY, Han BK, Shin JH, Kang SS. Breast MRI for evaluating patients with metastatic axillary lymph node and initially negative mammography and sonography. *Korean J Radiol* 2007; **8**: 382-9.
5. Buchanan CL, Morris EA, Dorn PL, Borgen PI, Van Zee KJ. Utility of breast magnetic resonance imaging in patients with occult primary breast cancer. *Ann Surg Oncol* 2005; **12**:1045-53.
6. Kaufmann O, Deidesheimer T, Muehlenberg M, Deckie P, Dietel M. Immunohistochemical differentiation of metastatic breast carcinomas from metastatic adenocarcinomas of other common primary sites. *Histopathology* 1996; **29**: 233-40.
7. Bhargava R, Beriwal S, Dabbs DJ. Mammaglobin vs. GCDFP-15: an immunohistologic validation survey for sensitivity and specificity. *Am J Clin Pathol* 2007; **127**:103-13.
8. Khandelwal AK, Garguilo GA. Therapeutic options for occult breast cancer: a survey of the American Society of Breast Surgeons and review of the literature. *Am J Surg* 2005; **190**: 609-13.
9. Yamaguchi H, Ishikawa M, Hatanaka K, Uekusa T, Ishimaru M, Nagawa H. Occult breast cancer presenting as axillary metastases. *Breast* 2006; **15**: 259-62.

.....★.....