

Successful Treatment of Watermelon Stomach / GAVE Syndrome by Using Argon Plasma Coagulation

Muhammad Afzal Bhatti, Anwaar A. Khan, Altaf Alam, Arshad K. Butt, Farzana Shafqat and Kashif Malik

ABSTRACT

This case report describes a 50-year-old female patient with liver cirrhosis presented with anemia. She was found to be suffering from gastric antral vascular ectasia (watermelon stomach) on upper gastrointestinal endoscopy. She underwent multiple sessions with Argon plasma coagulation, a non-contact thermal method of hemostasis for the management of watermelon stomach. After 3 sessions, the lesions disappeared and the hemoglobin increased by 2.4 gm/dl without any need of transfusion.

Key words: Watermelon stomach. Cirrhosis. Argon plasma coagulation. Gastric Antral Vascular Ectasia (GAVE).

INTRODUCTION

Varices, portal gastropathy and gastric vascular ectasia are causes of bleeding in liver cirrhosis.¹ Gastric Antral Vascular Ectasia (GAVE) is an increasingly recognized cause of recurrent, apparent or occult gastrointestinal bleeding and often with significant iron deficiency anemia. It is associated with conditions like autoimmune disease, cirrhosis, achlorhydria, and hypochlorhydria. Endoscopically, the patients present with a characteristic diagnostic antral appearance: longitudinal rugal folds traversing the antrum and converging on the pylorus, each containing a visible column of vessels, the aggregate resembling the stripes on a watermelon.²

Argon Plasma Coagulation (APC) is a non-contact thermal method of hemostasis, which uses Argon gas. A high voltage spark is delivered at the tip of the probe, which ionizes the Argon gas as it is sprayed from the probe tip in the direction of the target tissue. This ionized gas or plasma then seeks a ground in the nearest tissue, delivering the thermal energy with a depth of penetration of roughly 2-3 mm. By delivering energy to all tissues near the probe tip, which will conduct electricity, APC can be used to treat a lesion around a fold and not clearly in view.

The present case report describes the utility of the technique in treatment of the ectatic gastric antral vessels in a cirrhotic patient.

CASE REPORT

A 50-year-old female, known to have hepatitis C induced liver cirrhosis, presented with symptoms of

weakness, lethargy, fatigue, dyspnea and melena. On clinical examination, she was pale and was having palmar erythema. Abdominal examination did not reveal shifting dullness. Spleen was palpable and the rest of the systemic examination was found to be normal. Routine investigations revealed hemoglobin of 6.1 gm/dl, total leukocyte count of $6500 \times 10^3/\text{UL}$ and platelets were $65000/\text{UL}$. Prothrombin Time (PT) was 16 seconds with control of 12 seconds and Activated Partial Thromboplastin Time (APTT) was normal. Liver function tests showed an ALT of 40 U/L, AST of 35 U/L, ALP of 144 U/L and total bilirubin of 1.5 gm/dl. Serum albumin was 2.5 gm/dl. Abdominal ultrasound showed coarse liver with increased echogenicity and irregular margins without any space occupying lesion. Spleen was enlarged. There was no free fluid seen in the abdomen. Upper gastrointestinal (UGI) endoscopy with Olympus GIF 160 showed normal esophagus without esophageal or gastric fundal varices. Severe portal hypertensive gastropathy with multiple telangiectasia were seen in the antrum, leading to the characteristic appearance of watermelon stomach as shown in Figure 1. First session of Argon plasma coagulation was performed by ICC 200 ERBE, using frequency of 60 Watts and keeping a gas flow rate of 2 liters/minutes. It took 12 minutes to treat approximately 60% of the endoscopically visible lesions. She was given Omeprazole 20 mg daily and syrup Sucralfate for next 14 days. After 14 days, the second session was repeated. The improvement in the endoscopic appearance of the lesion was recorded and rest of the visible lesions was treated by APC. She was continued on Omeprazole and Sucralfate for the next 14 days. On third session, significant improvement was noted on endoscopy after 2 weeks, with resolution of approximately 75% of the lesions. Subsequently, third session was performed and same treatment continued. Serial hemoglobin levels were performed at every session. Improvement in hemoglobin was noted at the end of all sessions. Every EGD session was video recorded for serial comparison subsequently. Her

Department of Gastroenterology, Sheikh Zayed Hospital, FPGMI, Lahore.

Correspondence: Dr. Muhammad Afzal Bhatti, 9-A, Ayesha Street, Green Avenue, Muslim Town, Lahore.
E-mail: afzalbhatti@hotmail.com

Received February 4, 2008; accepted August 22, 2008.

hemoglobin was 7.2 gm/dl at the last session, while a total of 1.1 gm/dl increase was noted without any blood transfusion. Patient was followed up after 3 months. The repeat hemoglobin level was 8.3 gm/dl and endoscopy showed near-complete resolution of gastric vascular antral ectasia with few scattered telangiectasia visible in antrum and severe portal hypertensive gastropathy in the stomach as shown in Figure 2. Six month follow-up of the patient revealed hemoglobin level of 8.5 g/dl.

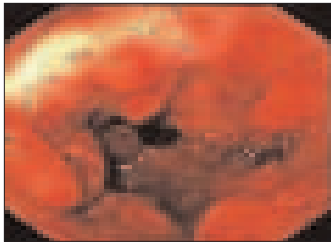


Figure 1: Endoscopic view of the gastric antrum showing watermelon stomach.




Figure 2: Close-up endoscopic view of the gastric antrum following APC therapy.

DISCUSSION

Watermelon stomach or Gastric Antral Vascular Ectasia (GAVE) is a rare but well-recognized cause of gastrointestinal blood loss, which typically affects elderly women. Historically, patients were treated with antrectomy but this has been largely replaced by endoscopic therapy such as Nd: YAG laser. Argon Plasma Coagulation (APC) is a new non-contact electrocoagulation technique, which has several theoretical advantages over laser.³

Grund *et al.* published the first series of clinical application of APC in GI endoscopy in 1994. They described the technique as successful in achieving objectives of treating lesions without complication.⁴ Johanns *et al.* reported similar success in 59 out of 60 patients in whom APC was used to coagulate bleeding lesions.⁵ As with laser and direct contact bipolar electrocautery, serial treatments with APC have shown to reduce transfusion requirements and raise hemoglobin in patients with GAVE syndrome. No head to head comparison of techniques has been reported.

The presently reported patient was a known case of cirrhosis of 4 years duration and had been admitted in the hospital for multiple times for the management of the complications of cirrhosis. She also had multiple transfusions previously to keep the hemoglobin near normal range. Total number of three sessions of APC were performed in that patient, which is quite comparable with the studies done in the past, in which the mean sessions for the APC were 3.2 and 2.8.^{6,7} However, there are studies in which the mean number of sessions are less i.e. 1.8.⁸ The number of sessions depends upon the severity of the lesion. A greater number of sessions in that patient were probably due to

the introduction of new technique in our set-up with less experience at the time of study. The efficacy of the APC has been evaluated in the past on the basis of patient's symptoms, transfusion requirements and hemoglobin levels. Cohen reported an increase of hemoglobin from 9.1-11.6 g/dl after APC sessions and a study done by Ter showed an increase in hemoglobin from 7.9-10.9 g/dl.^{6,8} In that patient, the increase in the hemoglobin was of 2.4 gm/dl i.e. from 6.1-8.5 gm/dl after 3 APC sessions. The patient was blood transfusion-dependent and there was history of two blood transfusions before APC as compared to none during 6 months follow-up after the last session of APC. There was significant decrease in the severity and intensity of the endoscopically visible lesions, which is in concurrence with the past reports.⁹ There were no marked side effect due to the APC sessions during the sessions and on 6 months follow-up.

APC in flexible endoscopy is an effective and easy-to-perform technique with no problems and complications due to its limited depth of tissue penetration, which allows its application even in critical areas.¹⁰ It is superior to all other treatment options like hormone therapies using corticosteroid and estrogen-progesterone and interferon therapy and endoscopic treatments, employing neodymium:yttrium-aluminum-garnet (Nd:YAG) laser, heater probe and bipolar electrocoagulation.¹⁰ Further long-term follow-up will be continued to note the long-term sequelae of the technique.

REFERENCES

1. Umar M, Kanwal S, Chohan AR, Chohan S, Baqai HZ, Khaar HB, *et al.* Pattern of esophageal varices and portal gastropathy in HCV related liver cirrhosis. *Pak J Gastroenterol* 2003; **17**:20-3.
2. Khan AG. Gastric vascular ectasia. *J Ayub Med Coll* 2004; **16**:69-71.
3. Yusoff I, Brennan F, Ormonde D, Laurence B. Argon plasma coagulation for treatment of watermelon stomach. *Endoscopy* 2002; **34**:407-10.
4. Grund KE, Storek D, Farin G. Endoscopic Argon Plasma Coagulation (APC) first clinical experiences in flexible endoscopy. *Endoscopic Surg Allied Tech* 1994; **2**:42-6.
5. Johanns W, Luis W, Janssen J, Kahl S, Greiner L. Argon Plasma Coagulation (APC) in gastroenterology: experimental and clinical experiences. *Eur J Gastroenterol Hepatol* 1997; **9**:581-7.
6. Ter H, Haber GB, Kandel G, Kortan P, Heller S, Jonnalagada S, *et al.* The long-term outcome of patients with watermelon stomach treated with argon plasma coagulation. *Gastrointest Endosc* 1998; **47**:41.
7. Roman S, Saurin J C, Dumortier J, Perreira A, Bernard G, Ponchon T. Tolerance and efficacy of Argon plasma coagulation for controlling bleeding in patients with typical and atypical manifestations of watermelon stomach. *Endoscopy* 2003; **35**: 1024-8.

8. Cohen J, Abedi M, Haber G, Dorais J, DuVall A, Scheider D, *et al.* Argon plasma coagulation: a new effective technique of non-contact thermal coagulation. Experience in 44 cases of GI angiomata . *Gastrointest Endosc* 1996; **43**:293.
9. Saurin JC, Cohelo J, Lepretre J, Chavaillon A, Systchenko R, Ponchon T, *et al.* Argon Plasma Coagulation (APC) efficiently controls bleeding in patients with watermelon stomach or radiation proctitis. *Gastrointest Endosc* 1999; **49**:169.
10. Erik S, Akira K, Yoshiya N, Tomoki M, Masato K, Kenya I. Effect of endoscopic treatment of gastric antral vascular ectasia associated with chronic liver disease. *Digestive Endoscopy* 2000; **12**:25-8.

.....★.....