

Finger Replantation: A Review of Replantation of Four Fingers in Three Patients

S. Mohammad Motamedolshariati,¹ Ezzatallah Rezaei,¹ Mostafa Dahmardehei*²

1. Department of Surgery, Mashhad University of Medical Sciences, Mashhad, Iran

2. Department of Surgery, Zahedan University of Medical Sciences, Zahedan, Iran

Article information

Article history:

Received: 25 Nov 2013

Accepted: 28 Jan 2014

Available online: 10 June 2014

ZJRMS 2015 Jan; 17(1): 47-50

Keywords:

Finger

Replantation

Microsurgery

Abstract

Background: Finger amputation is a physical and mental trauma. It can disrupt individuals' daily life. Numerous advances are made regarding the replantation of amputated fingers. These all owe to the advances of microscopic surgical methods and respective specialists' understanding of hand traumas. Establishing arterial blood circulation and venous flow are taken to be the most important factors in successful finger replantation.

Materials and Methods: Replantation of four fingers were carried out in three patients. Surgery was done without any additional surgical incision whether in distal fragment or in proximal fragment.

Results: Patients were between 18 to 54 years old. One case had smoking background of 15 years given up for 3 months from surgery. Hospital admission was 48 h. Mean surgery time was 5.5 h for each finger. In all cases, replantation was successful.

Conclusion: Although our method is technically time-consuming, it can be promising with respect successful results.

Copyright © 2015 Zahedan University of Medical Sciences. All rights reserved.

Introduction

Finger amputation is amongst contemporary problems of upper limb trauma. This results in irreversible limb malfunction. Patients include young and middle age individuals. Limb replantation requires high surgical skill and specialized instruments such as microscope and microsurgery means. These patients follow-up is similarly difficult and challenging yet important. In selecting suitable replantation patient, the condition of amputated limb, proximal fragment, as well as the patient's general status and tolerance of long term surgery must also be considered. Finally, replanted limb must have acceptable function [1].

Finger replantation indications include: 1- Thumb amputation: Because the thumb is responsible for over 40% of total hand performance, it is the first priority for replantation; 2- Amputation of more fingers; 3- Fingers amputation in children; and 4- Amputation of one finger in zone 1: in this case, the success of amputation and finger and hand performance will be acceptable. Contraindications of finger replantation include: 1- Finger amputation in people with fatal lesions and damages which are the first priorities (in this case, either replantation must be withdrawn (and) or be postponed); 2- Multiple damages in several areas of amputated finger; 3- Spiral amputation lesions (in this case, replantation can be done); 4- Stamped and (or) amputated finger lesions; 5- Amputation of a finger in zone 2; 6- Intentional amputation of finger done by the patient like mental patients; 7- Long term ischemia (over 12 h in hot ischemia and over 24-30 h in cold ischemia) [2-5]. Normally, after the general status of patient and his amputated limb was diagnosed as appropriate for

replantation, surgery will be begun by the incision of suitable area in amputated fragment using microscope in operation room. It gets started in the proximal fragment of amputation area to find proper artery and vein. In the present study, we report four replants carried out in three patients. And, then, we present revision regarding how searching for replanted artery and vein in proximal and distal fragments is done. In this revision, artery and vein are separated from surrounding tissues without any extra incision and in shorter time.

Materials and Methods

Four replants were carried out in three patients during 6 months. All patients were building worker. The oldest of them was 54 years.

The first patient was building worker. He was 35 years old. His finger stuck in elevator and just a narrow skin strip was connected in dorsal area. The strip was sectioned by surgeon before the beginning of finger replantation. Debridement skin was shortened. Patient had smoking background.

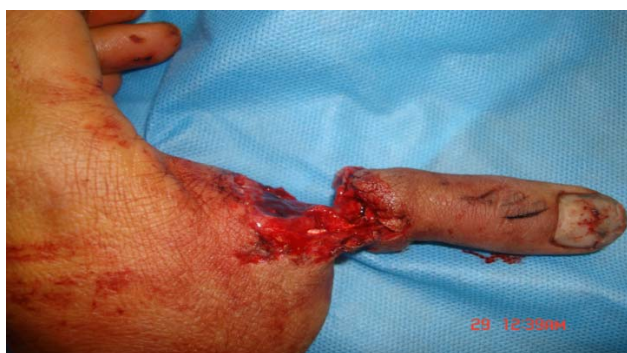It took 9 h from the time when trauma induced till the beginning of replantation operation and the finger was roughly dressed. Replantation was carried out in metacarpophalangeal joint. There were two skin incisions in the dorsal area of finger. The same area slightly bled after replantation till 24 h.

The second patient was a wood worker. He had 2-4 serious injuries as the result of sectioned ting wood. The third finger could not be replanted due to serious injury

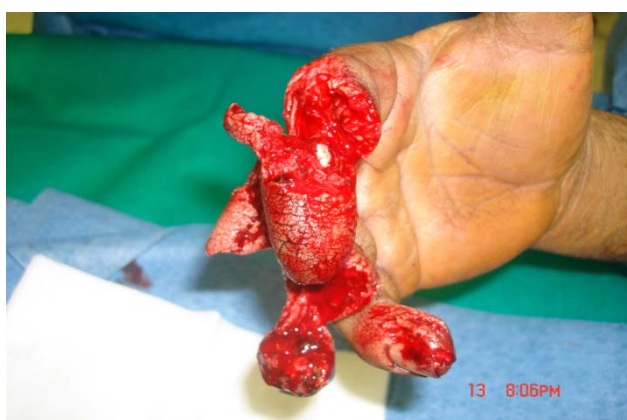(Fig. 1). After suitable debridement, the stump was sutured. The second and fourth fingers were replanted.

The third patient was carpenter worker. He was 27 years old. His thumb was obliquely sectioned from proximal to interphalangeal joint in right hand. There was deep injury in thumb cartilage. It bled till two days after replantation. The patient had smoked 10 cigarettes a day for 10 years, before admission (Fig. 2, 3).

Since in all surgeries, patients were hospitalized in other center than the primary place, it took 7 h between the induction of trauma and the beginning of replant. Amputation was carried out in thumb (in two patients) and the second, third and fourth fingers (in one patient). Concerning the patient's condition, the second and fourth fingers were replanted.



A



B

Figure 1. A: Dorsal aspect of crushed thumb in the third patient, **B:** Crushed 4 fingers of patient the second patient

In the present report, we incorporated two maneuvers to avoid extra incisions in the dorsal skin of distal fragment and to find dorsal veins: in early step, we employed moderate pressure in soft tissues on the surface and velar of thumb. Then, we made attempt to find dorsal vein by bleeding toward the end of vein amputated fragment (magnification=12×). In all three cases, this action was successful. In the fourth case, the abovementioned maneuver failed. After arterial anastomosis and the establishment of blood flow in distal fragment, we found dorsal veins by controlling the finger's dorsal level in bleeding area. Then, we softly separated dorsal vein from surrounding tissues and delivered to surgical wound. Replantation operation was carried out under anesthesia.

Before entering the patient into operation room, work was done on amputated fragment. In this step, no extra incision was employed. Bilateral digital artery was separated from digital neuron and surrounding tissues till reaching intact intima (delivery).

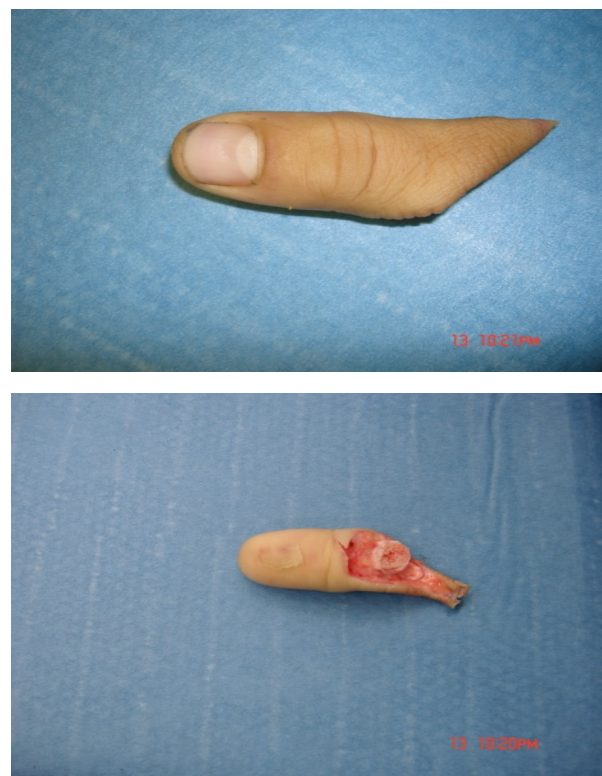


Figure 2. Volar and dorsal view of the amputated finger

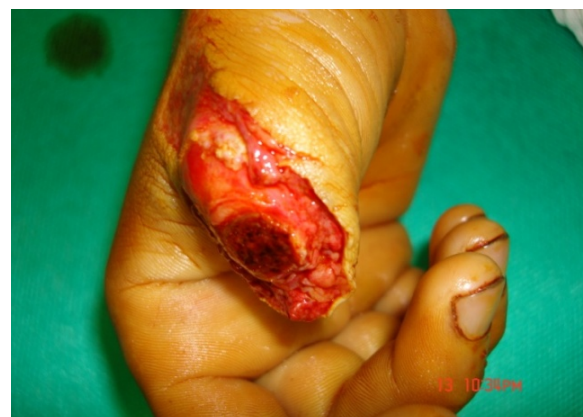

Figure 3. Amputated stamp

Bilateral artery and bilateral neuron were respectively marked by 10-0 and 9-0 nylon string. In the next step, we employed mild pressure on the soft and velar tissue and found the slight blood drainage of vein 2 of dorsal vein. Then, we marked it by 10-0 nylon string. Since we intended to not to induce any extra incisions in dorsal area, we postponed vein desection from surrounding tissues to the step after osteosynthesis.

In this step, patient was transferred to operation room. Proximal stamp was probed under anesthesia and

tourniquet control (100 mmHg over patient's systolic pressure and maximum up to 300 mmHg). Then, deep flexor tendon, bilateral digital artery, two dorsal veins, and bilateral digital neuron were found and marked separately. Osteosynthesis was done using KW (Kirshner Wire) No. 0.35 inch. Digital artery was discontinuously anastomosed by 10-0 nylon string under double microvascular clamp with 12× magnification.

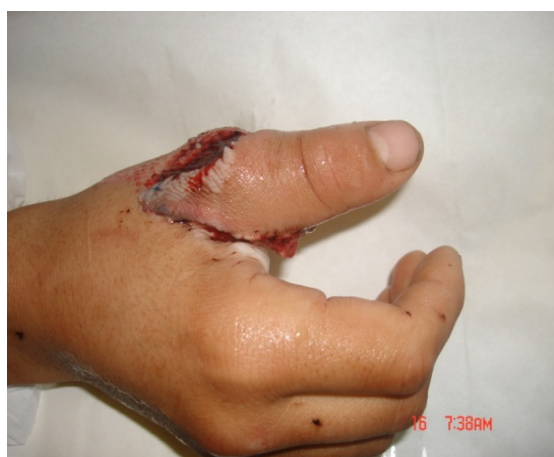
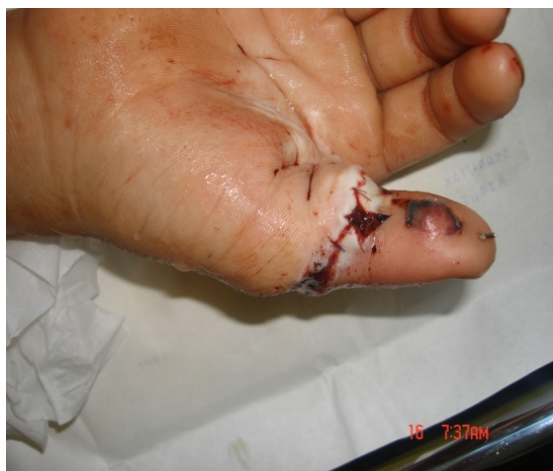
Figure 4. Volar and dorsal view of the implanted finger

In the end, the arterial anastomosis of vascular clamp was opened. In case of distal bleeding, the openness of anastomosis was approved. In none of the cases, arterial anastomosis revision was required. In anastomosis, surgery area and two ends of artery were rinsed drop by drop using heparin (1000 unit in 100 mL) by means of syringe and iota No. 28. In one case, due to the artery spasm, we put cotton saturated by papaverine on the area of artery anastomosis. Then, we tended to restore deep flexor tendon and extensor system. Dorsal veins' anastomosis was done exactly the same as arterial one. During the anastomosis of the first vein, vascular blood flow kept on via the second vein. In the end, distal blood flow was controlled for 15 min while the area of surgery was coated by cotton saturated by warm papaverine. Skin was restored by 4-0 nylon string. Dorsal splint was placed above elbow and in zero degree wrist flexion. A trained

nurse controlled the openness of anastomosis in ward using oximetry pulse. After 48 h from surgery, the wound was undressed and rinsed by warm saline. The patients were dismissed by splint. He had on-patient visits till 15 days later (Fig. 4). The patient was recommended to absolutely avoid smoking. Next visits were in the third and sixth weeks after surgery. From the sixth week on, physiotherapy was begun by removing KW.

Results

In all three cases replantation was successfully done. The dressing change was done by attending surgeon and on a regular basis every other day. Twelve hours after replantation in case one there was a mild bleeding which was controlled by gently applying adrenalin moisture fine mesh gauze. Suture removal was planned in day 14 and splint removed 4 weeks after the operation. Active physiotherapy was scheduled in 4 courses each was 10 consecutive days. The full course of therapy was 4 months.

Discussion

Although the replantation of amputated limb is a normal and accepted surgery, it has still its own specific technical precision and sensitivity. The only absolute ban of this surgery is the patient's adverse condition. That is, he cannot stand long complicated surgery [1]. Mean surgery time in our patients was 5.5 h for each finger. The amputated finger must be placed in a container of ice (no direct touch) after being cleansed by cotton saturated with saline and being placed in a plastic sterile bag. This can be replanted up to 56 h later [6, 7]. The tolerance time of warm ischemia is shorter in most proximal fragments of the limb. Although digital artery anastomosis is the key step of replant success, the main problem is related to ability to make vascular drainage [8-10]. Vein narrow wall enhances its susceptibility, in one hand, and it is permanently in collapse mode during anastomosis. It brings about further technical challenges. There are reports where semi-distal replantation of distal phalanx is successfully done by the anastomosis of one artery yet no vein anastomosis (in this case, suitable vein is not found for anastomosis) using leech replantation [11].

Another problem with vascular system is that no exact anatomic status is defined for dorsal veins. In dorsal area, we deal with a vascular network. Hence, dissection, detection, and separation of vein is considerably more difficult than artery. As a result, during the delivery of tissues to find suitable vein, harms or iatrogenic of vascular network is probable. The same damages can be highly risky. This is because, after the establishment of blood flow, they can lead to blood drainage and hematoma and pressure on the susceptible anastomosis of vascular system. Blood drainage of finger dorsal veins can be stopped by the least pressure. It is inevitable due to the vascular congestion of replantation failure. Based on

several reports, the most prevalent cause of replantation failure is vascular congestion after surgery [12].

The main difference between our patients and the normal method of finger replantation is that no extra incisions were done to search for thumb artery and vein. Regarding the matter that the location of the artery and vein is completely defined, the searching step was not required for all patients. Omitting more incisions means imposing lower risk to veins which must be anastomosed by microsurgery technique and it is considered to be an advantage. Yet, since it limits surgeon's access to veins' stump, naturally the surgery will become longer and need the surgeon's further patience. However, vascular anastomosis was done with further accuracy and longer time yet no extra incisions and flapping for dorsal veins exposure. Little blood drainage around the area of anastomosis means the presence of platelets. These platelets can result in the failure of replantation due to the vasoactive amines they release. These vasoactive amines are capable of contracting veins and can reverse the

replantation. That is why the accurate homeostasis of wound in the end of replantation surgery is emphasized [1]. The number of patients reported is small. Nevertheless, this surgical method will be continued regarding repletion in finger due to the group's positive response to this technique regarding the survival of replantation.

Authors' Contributions

All authors had equal role in design, work, statistical analysis and manuscript writing.

Conflict of Interest

The authors declare no conflict of interest.

Funding/Support

Zahedan University of Medical Sciences.

*Corresponding author at: Department of Surgery, Zahedan University of Medical Sciences, Zahedan, Iran.

E-mail: dahmardehei@zaums.ac.ir

References

- Li J, Guo Z, Zhu Q, et al. Fingertip replantation: Determinants of survival. *Plast Reconstr Surg.* 2008; 122(3): 833-9.
- Green DP, Pederson WC, Hotchkiss RN. *Green's operative hand surgery.* 4th ed. New York: Churchill Livingstone; 1998: 1139-1155.
- Merle M, Dautel G. Advances in digital replantation. *Clin Plastic Surg.* 1997; 24(1): 87-105.
- Soucaos PN. Indications and selection for digital amputation and replantation. *J Hand Surg.* 2001; 26(6): 572-581.
- Bunke HJ. Microvascular hand surgery – transplants and replants- over 25 years. *J hand Surg.* 2000; 25(3): 415-428.
- Baker GL, Kleinert JM. Digit replantation in infants and young children: Determinants of survival. *Plast Reconstr Surg.* 1994; 94(1): 139-45.
- Hattori Y, Doi K, Ikeda K, et al. Significance of venous anastomosis in fingertip replantation. *Plast Reconstr Surg.* 2003; 111(3): 1151-8.
- Akyürek M, Safak T, Keçik A. Fingertip replantation at or distal to the nail base: Use of the technique of artery-only anastomosis. *Ann Plast Surg.* 2001; 46(6): 605-12.
- Lee BI, Chung HY, Kim WK, et al. The effects of the number and ratio of repaired arteries and veins on the survival rate in digital replantation. *Ann Plast Surg.* 2000; 44(3): 288-94.
- Kim WK, Lim JH, Han SK. Fingertip replantations: Clinical evaluation of 135 digits. *Plast Reconstr Surg.* 1996; 98(3): 470-6.
- Matsuda M, Chikamatsu E, Shimizu Y. Correlation between number of anastomosed vessels and survival rate in finger replantation. *J Reconstr Microsurg.* 1993; 9(1): 1-4.
- Hahn HO, Jung SG. Results of replantation of amputated fingertips in 450 patients. *J Reconstr Microsurg.* 2006; 22(6): 407-13.

Please cite this article as: Motamedolshariati SM, Rezaei E, Dahmardehei M. Finger replantation: A review of replantation of four fingers in three patients. *Zahedan J Res Med Sci.* 2015; 17(1): 47-50.