

Case Report

Angiosarcoma of penis: Case report of an aggressive penile cancer

Vinod Priyadarshi, Hemant Kumar Goel, Debashish Chakrabarty¹, Dilip Kumar Pal

Departments of Urology, and ¹Pathology, IPGMER and SSKM Hospital, Kolkata, West Bengal, India

Abstract Angiosarcoma is a very rare mesenchymal tumor of penis. Though extremely unusual, it should be considered in the differential diagnosis in patients presenting with a penile growth or a localized subcutaneous penile lesions as they are very aggressive and there is a high chance of recurrence. One such case is reported here, which was aggressively treated with total penectomy and the patient did not show any recurrence in 2 years of follow-up.

Key Words: Angiosarcoma, mesenchymal tumor, penis

Address for correspondence:

Dr. Vinod Priyadarshi, Department of Urology, IPGMER and SSKM Hospital, Kolkata - 700 020, India. E-mail: vinod_priyadarshi@yahoo.com

Received: 27.05.2013, Accepted: 25.09.2013

INTRODUCTION

Primary mesenchymal tumors of penis are extremely rare. Angiosarcoma is an exceptional aggressive variety of such tumor that is reported here.

CASE REPORT

A 50-year-old man presented with complains of painless penile growth over distal shaft of penis over last 3 months, which was rapidly increasing in size over last 1 month and bleeding occasionally on contact. On physical examination, there was a 3 cm × 3.5 cm fungating growth involving whole glans and distal shaft of penis with multiple sebaceous cysts over scrotum [Figure 1]. Solitary left inguinal lymph node was palpable. Hemogram and other biochemical parameters were within the normal limits. Incisional biopsy of mass was suggestive of angiosarcoma while metastatic work-up was

negative. Patient underwent emasculation with total penectomy with bilateral scrotoectomy with perineal urethroostomy. As sarcomas metastasize mainly through hematogenous route, inguinal lymph node dissection was not performed. However, fine-needle aspiration cytology of the left inguinal lymph node was performed in the same sitting, which suggested reactive hyperplasia. There were no post-operative complications and patient was discharged from the hospital on the 6th post-operative day.

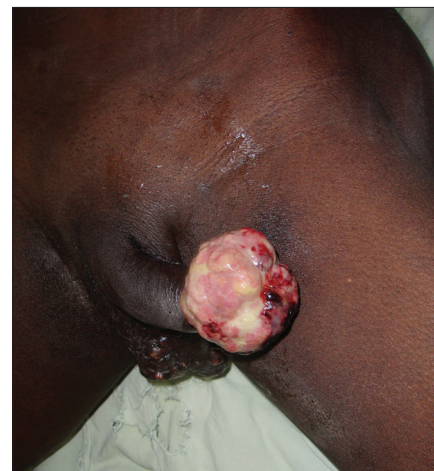

Figure 1: Fungating growth of penis with scrotal sebaceous cyst and left inguinal lymphadenopathy

Access this article online	
Quick Response Code:	Website: www.urologyannals.com
	DOI: 10.4103/0974-7796.150497

Fungating tumor was 5 cm × 4 cm × 3.5 cm in the dimension that was involving whole of the glans and was extending into both the cavernosa [Figure 2]. On histopathology, tumor was consisted of sheets and nests of large epithelioid and spindle cells with extensive proliferation of irregular and immature vascular channels lined by flattened endothelial cells with cellular atypia and nuclear pleomorphism, with numerous mitotic figures in between and red blood cells within [Figures 3 and 4]. Immunohistochemistry was positive for CD31, CD34 and vimentin and negative for cytokeratin and smooth-muscle actin (SMA), suggestive of angiosarcoma. Surgical margin as well as and left inguinal lymph node was negative for any extension or metastasis.

Left inguinal lymphadenopathy resolved by 4 months following surgery. Patient is doing well over 2 years of follow-up with no evidence of local recurrence or distant metastasis.

DISCUSSION

Primary mesenchymal neoplasms of penis are quite rare and most of these are of vascular, neural, myogenic or fibrous origin.^[1] Angiosarcoma is a rare variety of such vascular or lymphatic endothelial cell-derived malignant tumor and accounts for only about 1-2% of soft-tissue sarcomas all over the body and their presence in penis is exceptional.^[2] There are only a few reports in the literature where these tumors present as fungating mass,^[3,4] though they may also mimic as a Peyronie's plaque or a penile ulcer.^[5,6] Aetiopathogenesis of penile angiosarcoma is not well-described though chronic lymphedema, radiation and exposure to environmental carcinogens, in particular, thorotrast, arsenic and vinyl chloride have been suggested and their presence in patient with Human immunodeficiency virus infection and Neurofibromatosis have been noted in separate reports.^[4,6]

Histological appearance varies from a well-differentiated tumor resembling a hemangioma to an anaplastic lesion that is almost indistinguishable from a melanoma or a carcinoma.^[5] Immature neoplastic vessel formation along with areas composed of spindle cells and sparse lymphocytic reaction is characteristic of angiofibroma.^[4] Immunohistochemistry of these tumors used to be positive for CD31, CD34, vimentin, desmin, epithelial membrane antigen (EMA) factor 8 related antigen (F VIII RAg) and Ulex europaeus agglutinin(-I) while they are negative for cytokeratin and SMA.^[4,7]

Kaposi sarcoma, epithelioid hemangioendothelioma and alveolar rhabdomyosarcoma constitute important differential diagnosis.^[6] Like angiofibroma, Kaposi sarcoma too, show neoplastic neovascular proliferation, but at a lesser extent

and mostly at the periphery of tumor nodule.^[4] A Peyronie's disease should also be further excluded in patients with acutely changing subcutaneous plaques.^[5]

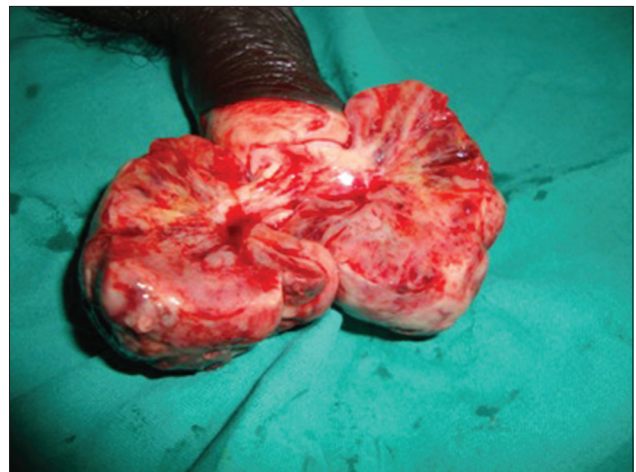

Figure 2: Bivalved specimen showing corporal invasion

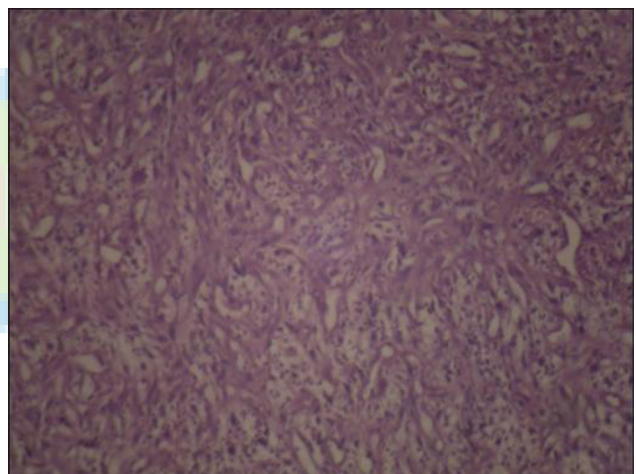


Figure 3: Histopathology of angiosarcoma of penis showing plenty of vascular spaces, lined by plump endothelial cells

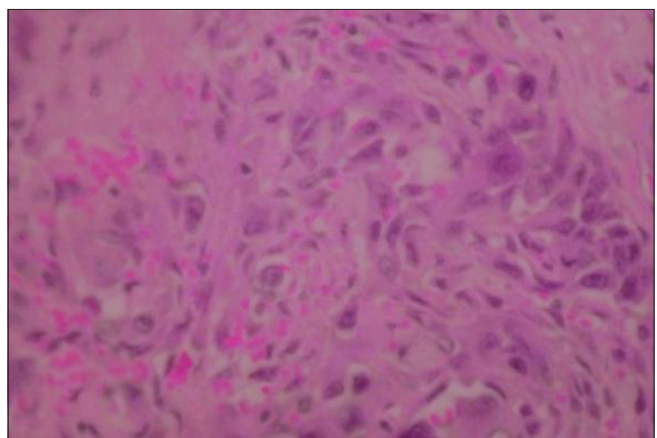


Figure 4: High power histopathology image

Clinically, angiosarcomas are malignant, with features of local invasion and metastatic spread, lungs being the most common site.^[4,5] Previous studies in grading angiosarcoma according to growth patterns, mitotic activity or cytological features have failed to show good correlation with survival. However, small tumor size (less than 5 cm) and a marked lymphocytic response are reported as features associated with prolonged survival.^[8]

Due to the rarity of such tumors, there is no agreement concerning the best method for staging and managing these patients. However, being aggressive in nature with high chance of local recurrence; local control of such tumors should be equally aggressive in the form of radical surgery or radiotherapy. Total penectomy with or without radiotherapy is suggested even for superficial disease. On the other hand, as the regional lymphatic spread is rare, inguinal lymph node dissections are not recommended, unless the adenopathy is palpable.^[1,3,6] Metastatic disease is rare with aggressive local control and is treated with either palliative chemotherapy or radiotherapy.^[1,3,7]

REFERENCES

1. Pettaway CA, Lance RS, Davis JW. Tumors of the penis. In: Wein AJ, Kavoussi LR, Novick AC, Partin AW, Peters CA, editors. Campbell-Walsh Urology. 10th ed. Philadelphia: Saunders; 2012. p. 901-33.
2. Fedok FG, Levin RJ, Maloney ME, Tipirneni K. Angiosarcoma: Current review. Am J Otolaryngol 1999;20:223-31.
3. Webber RJ, Alsaffar N, Bissett D, Langlois NE. Angiosarcoma of the penis. Urology 1998;51:130-1.
4. Prescott RJ, Mainwaring AR. Irradiation-induced penile angiosarcoma. Postgrad Med J 1990;66:576-9.4.
5. Ung JO, Padera RF, O'Leary MP. Angiosarcoma of the penis masquerading as a Peyronie's plaque. J Urol 2002;167:1785-6.
6. Moses KA, Tillett JW, Master VA. Primary penile angiosarcoma in a patient with AIDS: A case report. AIDS 2007;21:2355-6.
7. Wu X, Chen Z, Ji H, Duan G, Zhou Z. Angiosarcoma of the penis: A case report and literature review. Int Urol Nephrol 2012;44:1341-3.
8. Maddox JC, Evans HL. Angiosarcoma of skin and soft tissue: A study of forty-four cases. Cancer 1981;48:1907-21.

How to cite this article: Priyadarshi V, Goel HK, Chakrabarty D, Pal DK. Angiosarcoma of penis: Case report of an aggressive penile cancer. Urol Ann 2015;7:251-3.

Source of Support: Nil, **Conflict of Interest:** None.

