

## Case Report

# Resolution of hypercalcemia of malignancy following radical cystectomy in a patient with paraneoplastic syndrome associated with urothelial carcinoma of the bladder

Alfredo Harb-De La Rosa, Ahmed Ali, Sanjaya Swain, Murugesan Manoharan

Department of Urology, University of Miami Miller School of Medicine, Miami, FL, USA

### Abstract

Hypercalcemia of malignancy is a common finding associated with different types of cancers; however, its association with urothelial carcinoma of the bladder is rare. We report a case of a 69-year-old male with nonmetastatic urothelial carcinoma of the bladder who developed hypercalcemia that failed to respond to medical management, but resolved completely after undergoing resection of the tumor through radical cystectomy.

**Key Words:** Bladder cancer, hypercalcemia of malignancy, paraneoplastic syndrome

### Address for correspondence:

Dr. Murugesan Manoharan, Department of Urology, University of Miami Miller School of Medicine, P.O. Box 016960 (M814), Miami, FL, 33101 USA.

E-mail: [mmanoharan@med.miami.edu](mailto:mmanoharan@med.miami.edu)

Received: 28.03.2014, Accepted: 01.04.2014

### INTRODUCTION

Many types of cancers are associated with paraneoplastic syndromes where hypercalcemia is relatively common; however, this finding is seldom related to urothelial carcinoma of the bladder. We report a case of a 69-year-old male with nonmetastatic urothelial carcinoma of the bladder who developed hypercalcemia that failed to respond to medical management, but resolved completely after undergoing resection of the tumor through radical cystectomy.

### CASE REPORT

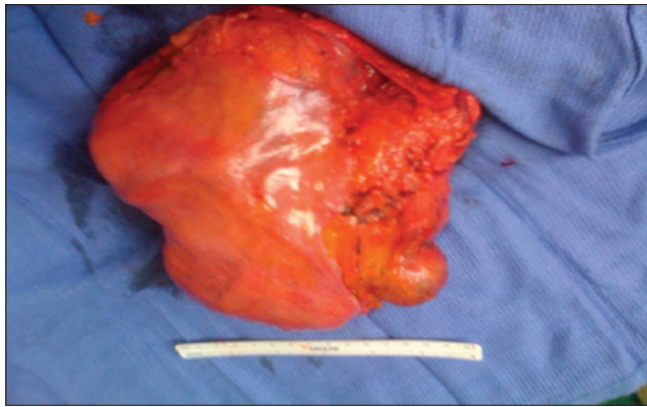
A 69-year-old man diagnosed with muscle invasive urothelial carcinoma of the bladder. He was admitted with symptoms of nausea, mild abdominal pain, constipation, polyuria, polydipsia,

and vague muscle aches. On physical examination, the patient had mild proximal muscle weakness and a palpable bladder mass that was mobile. His serum calcium was 14 mg/dl, and parathyroid hormone was <2.5 pg/ml. Metastatic workup, including computerized tomography of chest, abdomen, pelvis, and a bone scan was negative. Medical management to treat hypercalcemia including hydration and bisphosphonates was unsuccessful. An elective but urgent radical cystectomy was performed, which was uneventful. A bladder specimen measuring more than 20 cm was obtained [Figure 1]. During immediate postoperative period, calcium normalized with complete resolution of the patient's symptoms. Patient's postoperative serum calcium was 9.1 mg/dl.

### DISCUSSION

Hypercalcemia of malignancy is a common paraneoplastic syndrome and a frequent complication of advanced breast and lung cancer, and multiple myeloma. However, it is rarely found in association with bladder cancer. Hypercalcemia that occurs in patients with malignancy may be due to circulating bone-resorbing factors secreted by tumor cells. While this can occur in up to 20% of patients with renal cell carcinoma, it is a rare phenomenon in transitional cell carcinoma.<sup>[1]</sup> Efforts

Access this article online	
Quick Response Code:	Website: <a href="http://www.urologyannals.com">www.urologyannals.com</a>
	DOI: 10.4103/0974-7796.148627



**Figure 1:** Radical cystectomy

to identify the responsible mediators have been hampered by a lack of available human tumor cell systems suitable for study of the pathogenesis of the humoral hypercalcemia of malignancy (HHM).<sup>[2]</sup> Similar to renal cell carcinoma, transitional cell carcinoma associated with paraneoplastic hypercalcemia tends to be high grade and aggressive in nature with a poor prognosis.<sup>[3]</sup> Thorough evaluation to establish the cause of hypercalcemia is essential to rule out primary hyperparathyroidism. Key therapies are saline hydration to promote calciuresis and bisphosphonates to reduce pathologic osteoclastic bone resorption. Calcitonin and glucocorticoids, especially in 1,25-dihydroxyvitamin D-mediated HHM, can be effective in the treatment of hypercalcemia.<sup>[4,5]</sup> The gold standard treatment for muscle invasive bladder cancer and select cases of high-risk nonmuscle invasive bladder cancer is

radical cystectomy, bilateral pelvic lymph node dissection, and urinary diversion.<sup>[6]</sup>

This case stands as an example to demonstrate the association between urothelial carcinoma of the bladder and hypercalcemia as a paraneoplastic syndrome, in which tumor removal through radical cystectomy resulted in complete resolution of the patient's hypercalcemia.

## REFERENCES

1. Patel AB, Wilson L, Blick C, Meffan P. Paraneoplastic hypercalcaemia associated with TCC of bladder. *Scientific World Journal* 2004;4:1069-70.
2. Bringhurst FR, Bierer BE, Godeau F, Neyhard N, Varner V, Segre GV. Humoral hypercalcemia of malignancy. Release of a prostaglandin-stimulating bone-resorbing factor *in vitro* by human transitional-cell carcinoma cells. *J Clin Invest* 1986;77:456-64.
3. Chaudhary UB, Milling DL, Bissada NK. Transitional cell carcinoma of the bladder producing parathyroid hormone-related protein (PTHrP). *Can J Urol* 2004;11:2136-8.
4. Clines GA. Mechanisms and treatment of hypercalcemia of malignancy. *Curr Opin Endocrinol Diabetes Obes* 2011;18:339-46.
5. Pettifer A, Grant S. The management of hypercalcaemia in advanced cancer. *Int J Palliat Nurs* 2013;19:327-31.
6. Stein JP, Lieskovsky G, Cote R, Groshen S, Feng AC, Boyd S, et al. Radical cystectomy in the treatment of invasive bladder cancer: Long-term results in 1,054 patients. *J Clin Oncol* 2001;19:666-75.

**How to cite this article:** La Rosa AH, Ali A, Swain S, Manoharan M. Resolution of hypercalcemia of malignancy following radical cystectomy in a patient with paraneoplastic syndrome associated with urothelial carcinoma of the bladder. *Urol Ann* 2015;7:86-7.

**Source of Support:** Nil, **Conflict of Interest:** None.