

Case Report

Yolk sac tumor of the seminal vesicles: A rare malignant cause of hematospermia

Jonathan D. Gill, Selina Bhattarai¹, Chirag N. Patel², Alan B. Paul

Departments of Urology, ¹Histopathology and ²Radiology, St. James's University Hospital, Leeds, LS9 7TF, UK

Abstract

Extra-gonadal yolk sac tumors (YSTs) are rare and generally associated with poor outcomes. Involvement of the seminal vesicles is extremely rare with only one previously described case. We report a case of a primary YST of the seminal vesicles and discuss the management strategy.

Key Words: Hematospermia, seminal vesicles, yolk sac tumor

Address for correspondence:

Dr. Jonathan D. Gill, St. James's University Hospital, Beckett Street, Leeds, LS9 7TF, UK. E-mail: jongill@hotmail.com

Received: 03.11.2013, Accepted: 18.01.2014

INTRODUCTION

Yolk sac tumors (YSTs) are most commonly found in children and usually arise from the ovary or testis. Extra-gonadal YSTs are rare and generally associated with poor outcomes. Seminal vesicle involvement with YST is rarer still, with only one previously described case. We report a case of a primary YST of the seminal vesicles in a patient who had previously undergone orchidectomy for classical seminoma.

CASE REPORT

This is a case report of a 25-year-old male patient who presented to the Department of Urology with a painless right testicular mass. Ultrasonography revealed a solid mass suspicious for malignancy and hence he underwent a radical orchidectomy. Histology revealed a small focus (9 mm) of classical seminoma, pT1. Pre-operative tumor markers were normal and staging computed tomography (CT) did not show

any evidence of metastatic disease. He went on to receive a single dose of adjuvant carboplatin chemotherapy.

2 years later, he developed persistent hematospermia associated with increasingly elevated levels of lactate dehydrogenase and α -fetoprotein (1542 and 2033 respectively). Restaging CT, ultrasound of the remaining testicle and brain magnetic resonance imaging were normal. However, subsequent fluorodeoxyglucose (18F-FDG) positron emission tomography/CT (PET/CT) revealed abnormal activity within the seminal vesicles [Figure 1] and so he went on to have a transrectal ultrasound scan which confirmed abnormal appearances of the seminal vesicles. Biopsies were taken which revealed a YST. He underwent 4 cycles of bleomycin, etoposide and cisplatin (BEP) chemotherapy, followed by a radical prostatectomy with pelvic lymphadenectomy. Histology confirmed YST of both seminal vesicles extending into the prostate with clear margins and negative pelvic lymph nodes [Figure 2]. Tumor markers returned to normal post-operatively and he is currently under surveillance.

DISCUSSION

YSTs (endodermal sinus) are most commonly found in children and usually arise from the ovary or testis, although such tumors have been reported in extra-gonadal sites (mediastinum, retroperitoneum, sacrococcygeal region and prostate). Notable in this case is the fact that original pathology was a

Access this article online	
Quick Response Code:	Website: www.urologyannals.com
	DOI: 10.4103/0974-7796.148646

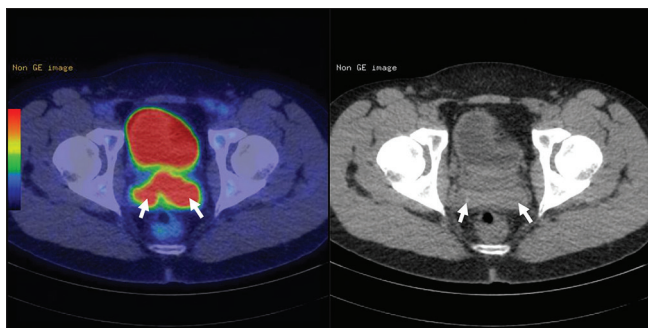


Figure 1: Axial fused fluorodeoxyglucose (FDG) positron emission tomography/computed tomography (CT) (left) and unenhanced CT (right) images demonstrating marked FDG avidity within enlarged seminal vesicles (arrows) extending into the adjacent prostate. No further sites of FDG avid disease were demonstrated

small (9 mm) classical seminoma with no evidence of yolk sac elements on pathology review. Therefore, this represents a primary YST of the seminal vesicles.

Extra-gonadal YSTs are rare and generally associated with poor outcomes. A multimodal approach of chemotherapy, radiotherapy and surgery is usually adopted although there appears to be little consensus on optimal treatment. A number of cases of YST have been reported in the prostate^[1-6] and treatment has generally consisted of surgery and adjuvant chemotherapy with or without pelvic radiotherapy. Survival has generally been <12 months. There has been one previously reported case of YST involving the seminal vesicles.^[7] This was treated with BEP chemotherapy followed by excision of the seminal vesicles. Subsequent biochemical relapse was treated with further BEP chemotherapy and pelvic lymphadenectomy for nodal metastases. Post-operative radiotherapy was ineffective and the patient died 18 months after diagnosis.

Given the aggressive nature of such tumors, in terms of the surgery, we felt that radical prostatectomy was necessary combined with pelvic lymphadenectomy to provide the best chance of cure.

CONCLUSION

YST of the seminal vesicles is extremely rare. Treatment involves chemotherapy and surgery, with or without radiotherapy. This case highlights the importance of fully investigating patients with persistent hemospermia and

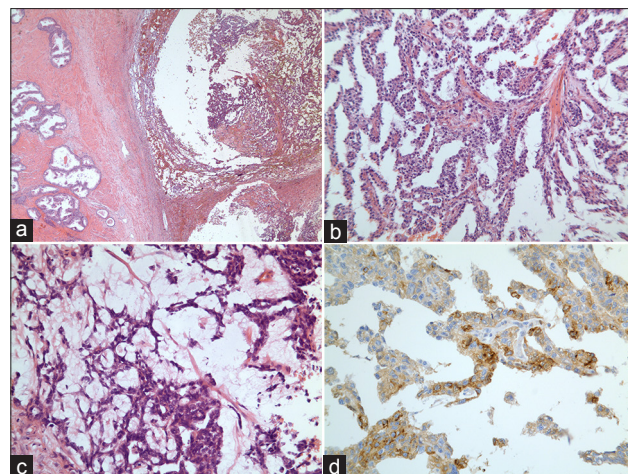


Figure 2: (a) Tumor (right) at the base of the seminal vesicle (left) $\times 50$. (b) Bland cytological atypia in a papillary yolk sac tumor with fibrovascular core $\times 200$. (c) Areas showing yolk sac tumor with microcystic/reticular pattern with vacuolated cytoplasm $\times 400$. (d) Positive staining for alpha fetoprotein. This was focal but strong $\times 400$

demonstrates the value of FDG PET/CT as an imaging modality in patients with elevated tumor markers and no cause identified on conventional imaging.

REFERENCES

1. Benson RC Jr, Segura JW, Carney JA. Primary yolk-sac (endodermal sinus) tumor of the prostate. *Cancer* 1978;41:1395-8.
2. Dalla Palma P, Dante S, Guazzieri S, Sperandio P. Primary endodermal sinus tumor of the prostate: Report of a case. *Prostate* 1988;12:255-61.
3. Schriber J, Flax S, Trudeau M, Cook GT, Weizel H, Katz A, et al. Primary yolk sac (endodermal sinus) tumor of the prostate: Case report and review of the literature. *Prostate* 1990;17:137-43.
4. Tay HP, Bidair M, Shabaik A, Gilbaugh JH 3rd, Schmidt JD. Primary yolk sac tumor of the prostate in a patient with Klinefelter's syndrome. *J Urol* 1995;153:1066-9.
5. Namiki K, Tsuchiya A, Noda K, Oyama H, Ishibashi K, Kusama H, et al. Extragonadal germ cell tumor of the prostate associated with Klinefelter's syndrome. *Int J Urol* 1999;6:158-61.
6. Han G, Miura K, Takayama T, Tsutsui Y. Primary prostatic endodermal sinus tumor (yolk sac tumor) combined with a small focal seminoma. *Am J Surg Pathol* 2003;27:554-9.
7. Yao XD, Hong YP, Ye DW, Wang CF. Primary yolk sac tumor of seminal vesicle: A case report and literature review. *World J Surg Oncol* 2012;10:189.

How to cite this article: Gill JD, Bhattarai S, Patel CN, Paul AB. Yolk sac tumor of the seminal vesicles: A rare malignant cause of hemospermia. *Urol Ann* 2015;7:107-8.

Source of Support: Nil, **Conflict of Interest:** None.