

## Case Report

# Diffuse large B-cell non-Hodgkin lymphoma of the prostate presenting with urinary outlet obstruction: A case report

Ram Nawal Rao, Megha Bansal, Shiwanjali Raghuvanshi, M. S. Ansari<sup>1</sup>, Zafar Neyaz<sup>2</sup>

Departments of Pathology, <sup>1</sup>Urology and <sup>2</sup>Radiodiagnosis, Sanjay Gandhi Postgraduate Institute of Medical Sciences, Lucknow, Uttar Pradesh, India

### Abstract

Large B-cell non-Hodgkin lymphoma involving the prostate accounts for 0.09% and 0.1% of non-Hodgkin lymphoma. We report a case of prostatic large B-cell non-Hodgkin lymphoma in a 77-year-old male with symptoms of urinary retention most probably due to benign prostate hyperplasia. He underwent multiple needle core biopsies through transrectal ultrasound of the prostate. Histopathological examination of the core biopsies revealed diffuse infiltration by atypical lymphoid cells in the prostatic stroma, which was strongly positive for leukocyte common antigen and CD20. CD3, CK, PSA, BCL2, k-light chain, Cyclin D1 and synaptophysin were negative. Histopathology and immunohistochemical profile in the case was consistent with the diagnosis of diffuse large B-cell non-Hodgkin lymphoma of the prostate.

**Key Words:** Immunohistochemistry and urinary retention, lymphoma, prostate

### Address for correspondence:

Dr. Ram Nawal Rao, Department of Pathology, Sanjay Gandhi Postgraduate Institute of Medical Sciences, Lucknow, Uttar Pradesh, India.  
E-mail: [rnawalrao@gmail.com](mailto:rnawalrao@gmail.com)

Received: 28.07.2013, Accepted: 12.01.2014

## INTRODUCTION

Non-Hodgkin lymphoma of the prostate is very rare but well documented.<sup>[1-3]</sup> Adenocarcinoma is the most common primary malignancy in the prostate, while primary or secondary lymphoma is the rarest. Prostatic involvement in non-Hodgkin lymphoma is extremely uncommon, which represents approximately 0.2-0.8% of extranodal lymphoma and 0.1% of all prostate neoplasms.<sup>[4-6]</sup> We report a case of prostatic large B-cell non-Hodgkin lymphoma in a 77-year-old male with presented symptoms of urinary outlet obstruction.

## CASE REPORT

A 77-year-old male presented with complaints of weakness and

loss of appetite since 2 months. The patient had a history of urinary outlet obstruction due to benign prostate hypertrophy (BPH). On peripheral blood smear (PBS), the patient had Hb-11.2 gm% and increased TLC ( $51.2 \times 10^3$ ) with lymphocytosis. Beta-2 microglobulin level was 7.5 mg/L (normal range: 7.0-11.8 mg/L). Digital rectal examination and transrectal ultrasonography showed a firm and enlarged prostate with hypoechoic pattern consistent with BPH. The total volume of the prostate was 60.5 cc. He had no family history of prostate cancer and his prostate-specific antigen (PSA) level was 2.0 ng/mL (normal 0-4 ng/mL). Ultrasonography showed hepatosplenomegaly with abdominal lymphadenopathy. Computed tomography scan of the pelvis showed a homogeneous mass lesion measuring 5.2 cm  $\times$  4.5 cm  $\times$  5.4 cm in the prostate [Figure 1].

## Pathological Findings

### Gross features

Twelve multiple linear core tissue pieces, with the largest measuring 1.5 cm from different areas of the prostate, were performed. All pieces were embedded.

### Histopathological examination

Sections from all the prostatic cores except the right base medial

Access this article online	
Quick Response Code:	Website: <a href="http://www.urologyannals.com">www.urologyannals.com</a>
	DOI: 10.4103/0974-7796.148637

revealed diffuse infiltration of medium to large-sized atypical lymphoid cells [Figure 2]. The tumor cells display a high n:c ratio, round nuclei, coarse chromatin, single conspicuous nucleoli and scant amount of cytoplasm. The tumor cells show perineural invasion. The sections from the right base medial show fibromuscular tissue only.

### Immunohistochemical study

On immunohistochemistry, the tumor cells are strongly positive for leukocyte common antigen [Figure 3] and CD20 [Figure 4]. CD3, CK [Figure 5], PSA, Bcl2, Cyclin D1 [Figure 6] and synaptophysin were negative. Histopathology and immunohistochemistry findings confirmed the diagnosis of diffuse large B-cell non-Hodgkin lymphoma.

### Bone marrow biopsy

Hypercellular marrow biopsy showed infiltration of small-sized atypical lymphoid cells (80-90%) with a high n/c ratio, round nuclei, coarse chromatin, inconspicuous nucleoli and

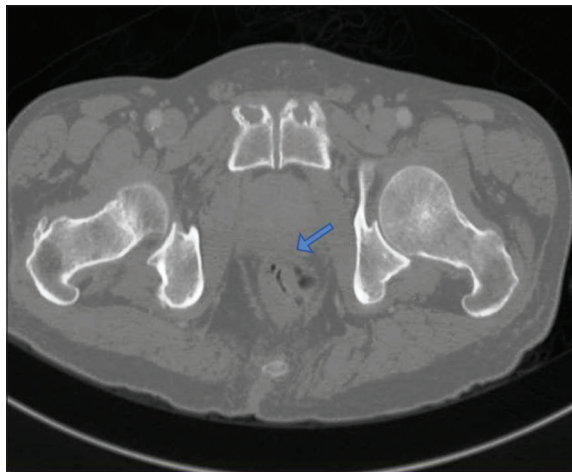
scant granular cytoplasm. Normal hemopoietic elements are markedly reduced.

### Flowcytometry

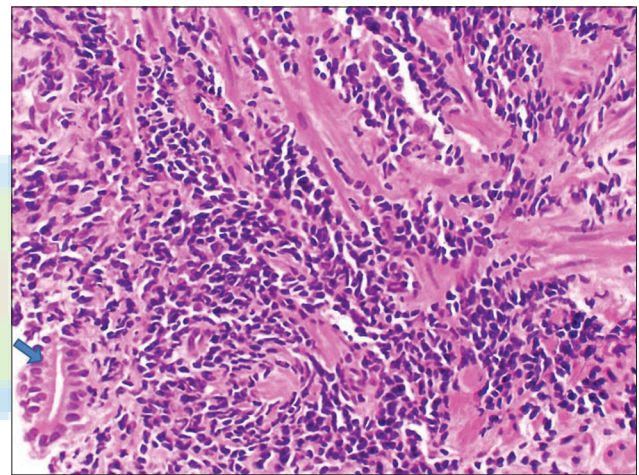
Flowcytometry was performed in cases with chronic lymphoproliferative disorder (CLPD). Panels showed gated cells in the lymphoid region displaying positivity for CD5/19 (49%), CD22 (56%) and CD20 (86%). Clonal for lambda light chains, CD23, FMC-7, CD38 and CD25/103, was negative. Histology, immunohistochemistry and flow cytometry findings confirmed the diagnosis of large B cell non-Hodgkin lymphoma of the prostate.

### DISCUSSION

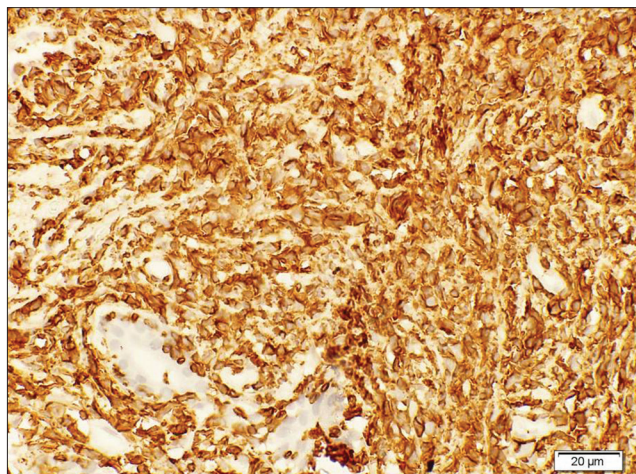
Prostate gland involvement by non-Hodgkin lymphoma is a well-known late manifestation of advanced nodal disease.<sup>[7]</sup>



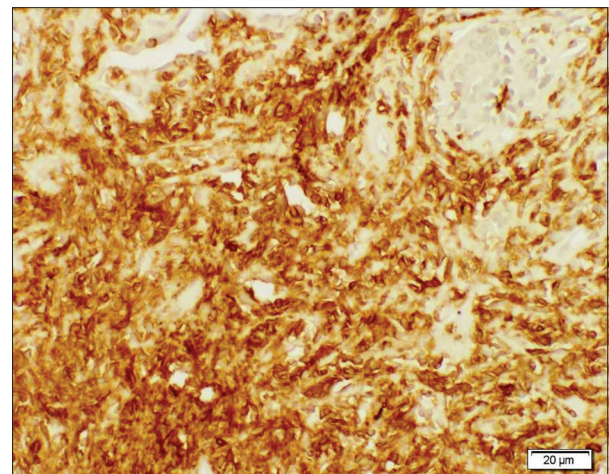
**Figure 1:** Computed tomography scan of the pelvis showed a homogeneous mass in the prostate



**Figure 2:** Histopathology section shows sheets of atypical lymphoid cells with a high n/c ratio, round nuclei, coarse chromatin, inconspicuous nucleoli and scant granular cytoplasm along with a normal prostate gland. H and E,  $\times 40$  magnification

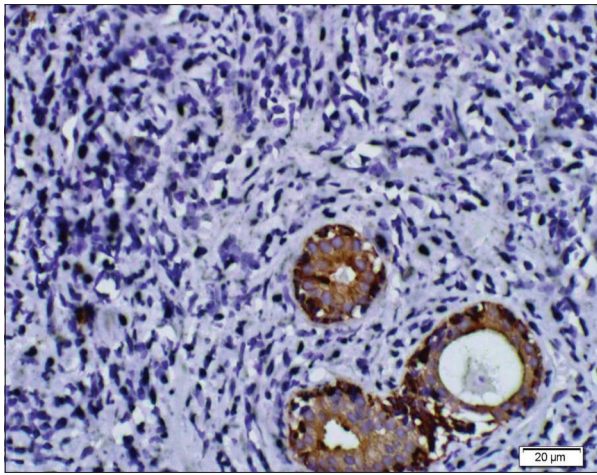


**Figure 3:** Atypical lymphoid cells are strongly positive for leukocyte common antigen,  $\times 40$  magnification

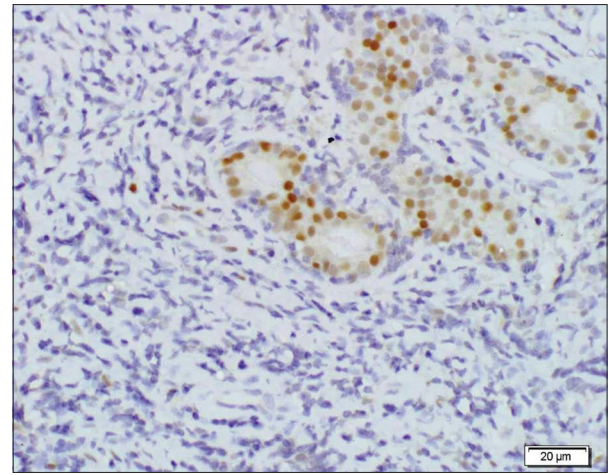


**Figure 4:** Atypical lymphoid cells are strongly positive for CD20,  $\times 40$  magnification





**Figure 5:** Atypical lymphoid cells are negative for Cytokeratin, ×40 magnification



**Figure 6:** Atypical lymphoid cells are negative for cyclin D1, ×40 magnification

Adenocarcinoma represents more than 90% of all prostatic malignancies. Other histological subtypes of prostatic cancers represent only 5-10%. Almost all patients diagnosed with prostatic lymphoma, whether primary or secondary, present symptoms of lower urinary obstruction.<sup>[1,5,6]</sup> The mean age at the time of the diagnosis is 62 years.<sup>[1]</sup> Some patients present pain or hematuria, and others present systemic symptoms. PSA may be normal, but it increased up to 20% of all cases. On digital rectal examination, the prostate appears diffusely enlarged or nodular and firm. Our patient showed urinary obstruction, systemic symptoms and firm and enlarged prostate on digital rectal examination. The computed tomography (CT) and magnetic resonance imaging scan appearance are non-specific, but may help to evaluate the stage. Non-Hodgkin lymphoma (NHL) diagnosis is always obtained by histopathological examination of needle core biopsies of prostatic tissue by transrectal ultrasound, as in our case. Occasionally, lymphoma is diagnosed as an incidental finding in a radical prostatectomy specimen removed for known prostatic adenocarcinoma.<sup>[8]</sup> The Diffuse large B cell lymphoma (DLBCL) is the most common type of primary lymphoma of the prostate, but primary prostatic small lymphocytic lymphoma, follicular lymphomas, Burkitt lymphomas, Mucosa associated lymphoid tissue (MALT) lymphomas and mantle cell lymphomas have also been reported.<sup>[1,5,6,9]</sup> Tumors were considered to be primary for patients having the following: (1) Symptoms of prostatic enlargement at the beginning of the disease; (2) predominant involvement of prostate; and (3) no involvement of lymph nodes, blood, liver or spleen.<sup>[1]</sup> The criteria for the diagnosis of primary prostatic lymphoma were defined by Bostwick *et al.*, and in their retrospective review of 62 cases, they showed that 47% of patients died of lymphoma and that the specific 5-year survival was only 33%. Primary prostatic lymphoma developed extraprostatic disease in 73% of the patients in 1-59 months after diagnosis. There were no significant differences in survival between patients receiving different therapies: Chemotherapy, chemotherapy and

radiotherapy or surgery only. There were no significant differences between patients with primary or secondary prostatic lymphoma or between patients with different types of lymphoma.<sup>[1]</sup> In fact, a number of more recent case studies have reported good outcomes for patients with high-grade primary prostatic lymphoma treated with anthracycline-based chemotherapy with or without radiotherapy.<sup>[5,10]</sup> Other cases with localized diffuse large B-cell lymphoma were managed successfully with radiotherapy only.<sup>[11]</sup> Rituximab in combination with cyclophosphamide, doxorubicin, vincristine, and prednisone (CHOP) regimen, is considered as the standard treatment protocol for patients with advanced stage DLBCL.<sup>[12]</sup> It remains doubtful whether the prognosis of prostatic lymphoma is significantly worse or equivalent to nodal lymphoma. In one review of 23 cases of Japanese primary prostatic lymphoma, the authors suggested that patients with this malignancy responded well to chemotherapy and could possibly be cured when the disease is confined to the prostatic region.<sup>[13]</sup> Some authors suggested that prognosis of B-cell non-Hodgkin lymphomas is dependent on the histological type and stage of the individual tumor, as is the case of other non-Hodgkin's lymphomas.<sup>[11]</sup> Some authors reported that the prognosis and treatment of other extranodal lymphoma are the same as that of nodal lymphomas.<sup>[14]</sup> After 10 months of receiving chemotherapy, it becomes redundant. A CT scan of the pelvis was performed in our case, and showed complete radiological response of the prostatic tumor, and the patient remained free of the disease.

## CONCLUSION

Urinary retention and low PSA level in an elderly patient may rarely be secondary to a prostatic lymphoma that surgeons and pathologists need to diagnose to facilitate the appropriate management of these patients.

## REFERENCES

1. Bostwick DG, Iczkowski KA, Amin MB, Discigil G, Osborne B. Malignant lymphoma involving the prostate: Report of 62 cases. *Cancer* 1998;83:732-8.
2. Alvarez CA, Rodríguez BI, Perez LA. Primary diffuse large B-cell lymphoma of the prostate in a young patient. *Int Braz J Urol* 2006;32:64-5.
3. Antune AA, Dall'Oglio M, Srougi M. Primary lymphoma of the prostate. A rare cause of obstruction. *Int Braz J Urol* 2004;30:410-2.
4. Freeman C, Berg JW, Cutler SJ. Occurrence and prognosis of extranodal lymphomas. *Cancer* 1972;29:252-60.
5. Patel DR, Gomez GA, Henderson ES, Gamarra M. Primary prostatic involvement in non Hodgkin lymphoma. *Urology* 1988;32:96-8.
6. Sarris A, Dimopoulos M, Pugh W, Cabanillas F. Primary lymphoma of the prostate: Good outcome with doxorubicin-based combination chemotherapy. *J Urol* 1995;153:1852-4.
7. Zein TA, Huben R, Lane W, Pontes JE, Englander LS. Secondary tumors of the prostate. *J Urol* 1985;133:615-6.
8. Bacon C. Small cell tumors, lymphomas, and sertoli cell and leydig cell tumors of the bladder, prostate, and testis. In: Waxman J, editor. *Urological cancers*. Vol. 1, 1<sup>st</sup> ed. London: Springer; 2005. p. 309-31.
9. Li C, Hibino M, Komatsu H, Sakuma H, Sakakura T, Ueda R, *et al.* Primary mucosa-associated lymphoid tissue lymphoma of the prostate: Tumor relapse 7 years after local therapy. *Pathol Int* 2008;58:191-5.
10. Chargari C, Gillion N, Ghalibafian M, Ribrag V, Girinsky T, Magné N. A rare case of primitive prostatic large B-cell lymphoma and review of literature. *Cancer Radiother* 2009;13:69-71.
11. Ghose A, Baxter-Smith DC, Eeles H, Udeshi U, Priestman TJ. Lymphoma of the prostate treated with radiotherapy. *Clin Oncol (R Coll Radiol)* 1995;7:134.
12. Essadi I, Ismaili N, Tazi E, Elmajjaoui S, Saidi A, Ichou M, *et al.* Primary lymphoma of the head and neck: Two case reports and review of the literature. *Cases J* 2008;1:426.
13. Fukutani K, Koyama Y, Fujimori M, Ishida T. Primary malignant lymphoma of the prostate: Report of a case achieving complete response to combination chemotherapy and review of 22 Japanese cases. *Nippon Hinyokika Gakkai Zasshi* 2003;94:621-5.
14. Elharroudi T, Ismaili N, Errihani H, Jalil A. Primary lymphoma of the ovary. *J Cancer Res Ther* 2008;4:195-6.

**How to cite this article:** Rao RN, Bansal M, Raghuvanshi S, Ansari MS, Neyaz Z. Diffuse large B-cell non-Hodgkin lymphoma of the prostate presenting with urinary outlet obstruction: A case report. *Urol Ann* 2015;7:100-3.

**Source of Support:** Nil, **Conflict of Interest:** None.

