

Tanaffos (2004) 3(9), 61-67

©2004 NRITLD, National Research Institute of Tuberculosis and Lung Disease, Iran

Whole Lung Lavage under General Anesthesia in A Child with Pulmonary Alveolar Proteinosis (A Case Report)

Badiolzaman Radpay¹, Tahereh Parsa¹, Soheila Khalilzadeh², Shideh Dabir¹, Shahram Karimi Zandi¹, Mahshid Ghasemi¹

¹Department of Anesthesiology, ²Department of Pediatrics, NRITLD, Shaheed Beheshti University of Medical Sciences and Health Services, THERAN-IRAN.

ABSTRACT

Pulmonary alveolar proteinosis (PAP) is a rare disease in which surfactant accumulates abnormally in the pulmonary alveolar walls and causes respiratory symptoms. The only known effective treatment for PAP is pulmonary lavage. We have reported an 11- year-old girl with pulmonary alveolar proteinosis who underwent pulmonary lavage with normal saline under general anesthesia by a new method (using an univent tube for pulmonary blockage, ventilating one lung, and concurrently passing a catheter from out of the tube for lavage). The general condition and vital signs of the patient were normal during lavage and in follow up. Three weeks later, her opposite lung was lavaged too. The results were favorable. (Tanaffos 2004; 3(9): 61-67)

Key words: Pulmonary Alveolar Proteinosis (PAP), Whole Lung Lavage (WLL), One Lung Ventilation (OLV), General anesthesia

INTRODUCTION

Pulmonary alveolar proteinosis (PAP) is a rare disease characterized by excessive accumulation of surfactant in the alveolar space causing dyspnea, dry cough and recurrent pneumonia (1,2). It may lead to pulmonary fibrosis in one- third of untreated patients. Although various maintenance therapies have been suggested, the only known treatment which can influence the course of the disease and prevent the development of clinical signs and symptoms, is whole lung lavage (WLL) (3,4,5,6). With respect to the technical complexity, WLL has not been yet employed in Iran. During WLL, both lungs should be separated anatomically and physiologically from

each other in a way that while one lung is washed completely and the other one could carry out the ventilation process.

To meet this demand, precise and special anesthetic methods, double lumen endotracheal tube and one lung ventilation are required (7,8). WLL is rather troubled in children by smaller-sized airways and lack of appropriate double-lumen endotracheal tubes (9). Thus, the application of lavage is more limited in this age group. Recent advances in anesthesiology and discovering new approaches for lung separation have provided the feasibility of performing such procedures in thoracic surgery department; however, due to technical problems, WLL under general anesthesia has not been performed in Iran. The first

Correspondence to: Radpay B

Tel: +98-21-2280500, Fax: +98-21-2285777

Email address: radpi@sbm.ac.ir

successful report of WLL in a patient with PAP was presented by our team last year (10). This report is the second in Iran and the first in children with the new method of lavaging.

CASE SUMMARIES

An 11-year-old girl from Tehran was referred to National Research Institute of Tuberculosis and Lung Disease (NRITLD) with progressive dyspnea and cyanosis.

During hospitalization, she developed dyspnea (at rest and exertion) along with cyanosis and intermittent fever. Cyanosis improved with supplemental oxygen given via mask; however, she was still oxygen dependent (Figure 1).

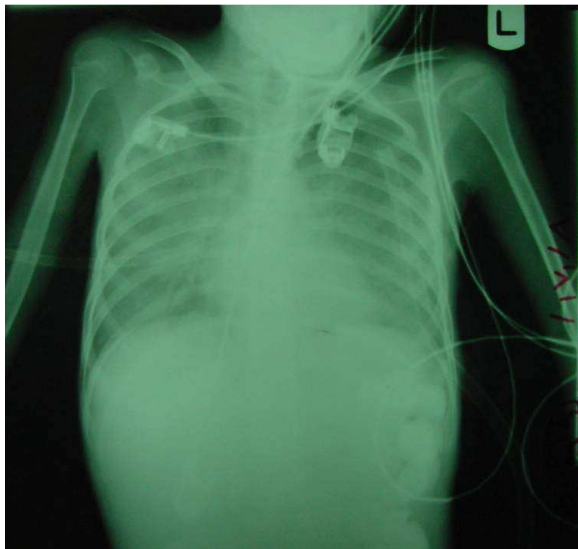


Figure 1. CXR of patient.

She was delivered by normal vaginal delivery with a normal apgar score. Her birth weight was 2750 gm. She underwent two surgeries for gastro-esophageal reflux (due to achalasia) at the ages of 1 and 3 years. Meanwhile, she underwent open lung biopsy for the diagnosis of pulmonary alveolar proteinosis (PAP) in our center.

Her intelligence quotient (IQ) was normal. In the

family history, her parents were relatives (cousins). Physical exam revealed mild cyanosis in lips and fingers along with clubbing. She weighted 17 Kg. Her vital signs were as follows; blood pressure (BP) 90/65 mmHg, pulse rate (PR) 90/min., respiratory rate (RR) 23/ min, and T=37.3 °C. Lung sounds were diminished at both sides along with bilateral generalized wheezing. Other organs were normal. Laboratory findings showed mild anemia and high sedimentation rate (ESR=27). Arterial blood gas (ABG) analysis was as follows: PH= 7.41, PaCO₂= 31.2, PaO₂= 37, HCO₃= 19.2 (SpO₂ was 79 at the same time). Chest X-ray showed bilateral diffuse infiltrations with granular appearance. Computed tomography CT-scan of the lungs showed crazy-paring appearance (Figure 2).

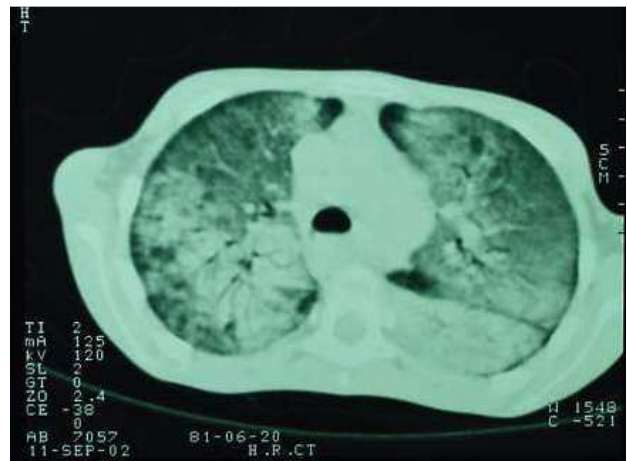


Figure 2. CT-scan of the lungs showed crazy-paring appearance.

Open lung biopsy was performed for the confirmation of diagnosis. Lung pathology was consistent with pulmonary alveolar proteinosis (PAP).

Anesthetic Induction and Bronchoalveolar Lavage (BAL)

Anesthetic induction was initiated by pre-oxygenation for 5 minutes (pure oxygen administration via FIT mask of anesthesia machine)

and administration of midazolam 0.5 mg, fentanyl 30 mg and lidocaine 25 mg as premedications. Subsequently, anesthetic induction was performed by administration of propofol 30 mg and atracurium 8 mg. Propofol infusion (150 $\mu\text{g}/\text{kg}/\text{min}$) along with intermittent administration of atracurium (2 mg) each 30 min and fentanyl (0.5-1 $\mu\text{g}/\text{kg}/\text{min}$) were used for maintenance. Three minutes later, when sufficient muscle relaxation and paralysis was achieved, a univent tracheal tube (size = 4.5) was introduced in the following way (figure 3): the cuff of bronchial blocker was pulled back into main lumen of the tube and tracheal intubation was performed. Then cuff of bronchial blocker was directed to the left main bronchus by giving appropriate position to the tube and using the neonatal fiberoptic bronchoscope (size = 1.3 mm).

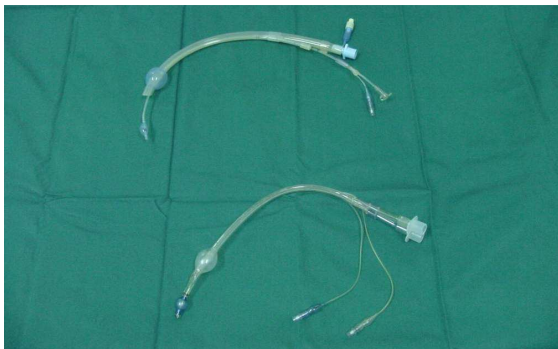


Figure 3. Univent tracheal tube.

We became assured of the appropriate position of the cuff and blocker by inflating and deflating the cuff and auscultating the lungs (if bronchial blocker tube is inserted appropriately while the cuff is inflated, the related lung will be blocked so that no respiratory sound can be heard on ventilation). Then the cuff of the univent tube was inflated and the tube was fixed properly. At this time, tracheal cuff of the univent tube and the bronchial blocker cuff were emptied and a nasogastric tube (8 French) was inserted adjacent to the univent tube and directed to the left main bronchus under the guidance of a fiberoptic

bronchoscope. This tube was positioned in such a way that its pores were placed just below the bronchial blocker cuff (nasogastric tube had only two pores, one in the tip and the other in the lateral side with a distance of 0.5 cm from the tip).

The positions of univent tube and bronchial blocker tube cuffs were rechecked. Additionally, while the bronchial blocker tube cuff was inflated, successful ventilation of the right lung was assessed by auscultation. The patient's SpO_2 was measured during the ventilation of one lung for its sufficiency. Meanwhile, the performance of nasogastric tube was also checked by inflating the bronchial blocker tube and injecting a little amount of normal saline into the nasogastric tube to confirm the absence of fluid return to the trachea or the opposite bronchus.

Finally, the cuff of bronchial blocker tube was inflated in the left main bronchus, and right lung was ventilated separately (vital signs were normal and SpO_2 was 94%). By using a Y-shaped connector, the patient's nasogastric tube was connected to a warm normal saline (N/S) solution (37°C) on one side and to an empty serum dish for collecting fluid on the other side. Subsequently, infusion of N/S solution for lavage was initiated into the left lung from 30 cm above the heart level. In the first stage, about 200 cc fluid was entered while the returning fluid was 125 cc.

Left lung lavage was repeated 10 times with 250 cc infusion fluid. Totally, 2450cc fluid was infused while 2255 cc was removed (table 1).

Each stage lasted almost 30 minutes. During this period, chest physiotherapy was performed by a physiotherapist. The BAL fluid that was turbid and creamy colored, was collected immediately in an empty reservoir, and precipitated at the bottom. As the procedure continued, the fluid became more clear and was almost clear in the final stage. It is notable that, during the infusion phase, SpO_2 was increased and blood pressure was decreased slightly; while in

the draining phase the opposite occurred. At the end of lavage, the lungs were inflated and repeated suction cleared the lungs from any retained fluid. Muscle paralysis was reversed by administration of prostigmine along with atropine.

Table 1. Data of left lung lavage with respect to the input and output volume and SpO₂.

Lavage stage	Volume cc		SpO ₂ (%)	
	Input	Output	Input	Output
1	200	125	93	91
2	250	200	94	93
3	250	250	96	94
4	250	230	98	97
5	250	250	98	97
6	250	250	100	98
7	250	225	98	97
8	250	250	98	96
9	250	225	98	98
10	250	250	99	98
Total	2450	2252	-	-

The patient's tracheal tube was replaced by a regular tracheal tube (size = 5.5), and propofol infusion was decreased to 15mg/hr. She was transferred to the intensive care unit (ICU) with an acceptable level of respiration (SpO₂=98%) where she received assisted mechanical ventilation with pressure support ventilation (PSV) of 10 cm H₂O. Regular monitoring of vital signs was performed, and chest x-ray was obtained 4 hours later as well as the next day (Figure 4).

Weaning from mechanical ventilator was achieved gradually and she was extubated the next morning. During the next two days of hospitalization, vital signs and respiratory state of the patient were within the normal range. Finally, she was transferred to the children ward and discharged 3 days later. She was followed up for three weeks and after that the

opposite lung was lavaged similarly, afterwards, she enjoys a normal life.

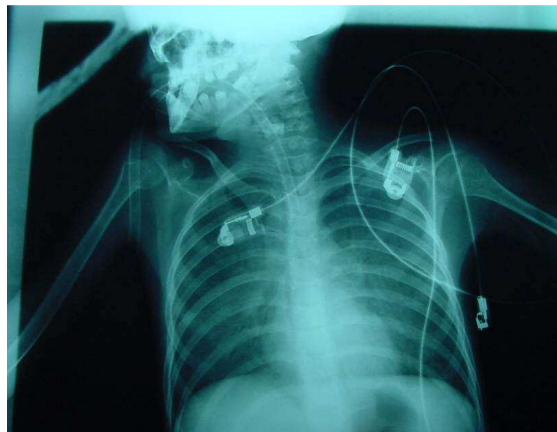

Figure 4. CXR after whole lung lavage.

DISCUSSION

Pulmonary alveolar proteinosis (PAP) is a disease characterized by excessive accumulation of surfactant in the alveolar space. In normal state, surfactant is necessary for normal functioning of the alveoli, keeping them open by decreasing the surface tension. Unfortunately, surfactant is abnormally accumulated in the alveolar space in PAP patients and interferes with diffusion of oxygen into the capillaries adjacent to the alveoli resulting in symptoms and signs of PAP. The age range of patients is 20-50 years and there is a slight male predominance. The disease is either primary or secondary. The primary type is usually idiopathic and more reported as a hereditary disease; however, several secondary factors have been proposed for the other category such as HIV infection lymphoproliferative disorders, exposure to materials such as silica, aluminium and titanium dust, insecticides, and tuberculosis (7,11).

Pathophysiologically, there is no evidence for overproduction of alveolar phospholipids (surfactant), but there are some clues indicating imbalance between surfactant production and its

clearance. In these patients, cellular function of macrophages is impaired in the alveolar spaces. Studies performed on mice showed a genetic role in the causation of PAP. Numerous factors have been suggested in this regard (genetic characteristics, expression of genes,...), but none of them have been proved in human being (12). The symptoms of disease are variable in human and usually are mistaken with chronic pneumonia. Usually there is mild to moderate dyspnea. Other symptoms include persistent dry cough (sometimes with a little amount of sputum), weight loss, low fever, and/ or night sweat.

Radiologically, chest x-ray shows bilateral diffuse infiltrations. There are also crazy-paring appearances characterizing PAP in CT-scan of the lung (13, 14). Bronchoalveolar lavage (BAL) by fiberoptic bronchoscopy can suggest PAP; however, open lung biopsy confirms the diagnosis (15, 16).

Almost one-third of patients experience spontaneous remission without any special treatment, however, one-third require whole lung lavage for improvement and the remaining sufferers show progressive form of disease despite repeated lavages. This group may develop pulmonary fibrosis. All of the patients with PAP are susceptible to unusual forms of pneumonia.

Prior investigators have proposed the following indications for whole lung lavage in PAP patients (2,5,6):

- 1- Severe symptoms of disease like persistent cough and dyspnea.
- 2- Severe hypoxemia ($\text{PaO}_2 < 60$ mm Hg or O_2 saturation $< 90\%$)
- 3- Preventing pulmonary infections
- 4- Preventing pulmonary fibrosis

CONCLUSION

Pulmonary alveolar proteinosis (PAP) is a rare disease with unknown cause. The best known therapeutic approach is whole lung lavage under

general anesthesia. Considering the related regulations this method is practical and could be quite successful in Iran.

ACKNOWLEDGEMENTS

The authors wish to thank colleagues of pediatrics, Bronchoscopy, Anesthesiology, Intensive Care, Pathology and Physiotherapy wards for their friendly cooperation in various stages of treatment and, of course, Mrs. Naghmeh Niroomand for typing and editorial assistance.

REFERENCES

1. Rosen SH, Castleman B, Liebow AA. Pulmonary alveolar proteinosis. *N Engl J Med* 1958; 258 (23): 1123-42.
2. Benumof JL. Anesthesia for Thoracic Surgery, second edition, 1995, W.B. Saunders.
3. Milleron BJ, Costabel U, Teschler H, Ziesche R, Cadranet JL, Matthys H, Akoun GM. Bronchoalveolar lavage cell data in alveolar proteinosis. *Am Rev Respir Dis* 1991; 144 (6): 1330-2.
4. Sosolik RC, Gammon RR, Julius CJ, Ayers LW. Pulmonary alveolar proteinosis. A report of two cases with diagnostic features in bronchoalveolar lavage specimens. *Acta Cytol* 1998; 42 (2): 377-83.
5. Fukuhara N, Miyazawa T, Doi M. Successful treatment of pulmonary alveolar proteinosis by massive bronchoalveolar lavage. *Nihon Kyobu Shikkan Gakkai Zasshi* 1996; 34(7): 796-803.
6. James DG, Rizzato G, Sharma OP. Bronchopulmonary lavage (BAL). A window of the lungs. *Sarcoidosis* 1992; 9 (1): 3-14.
7. Miller RD. Anesthesia Edition Churchill Livingstone, 2000.
8. Hao Q, et al. Anesthesia for lung lavage pulmonary alveolar proteinosis in: the internal journal of Anesthesiology <http://www.ispub.com/journals/IJA/Vol>
9. Sakai Y, Abo W, Yoshimura H, Sano H, Kuroki Y, Satoh M, Kaimori M. Pulmonary alveolar proteinosis in

- infants. *Eur J Pediatr* 1999; 158 (5): 424-6.
10. Radpey B, Parsa T, et al. Whole lung lavage in pulmonary alveolar proteinosis. The first case report in Iran. *Journal of Medical Council of Islamic Republic of IRAN* accepted in the year 2002.
11. Diseases associated with exposure to silica and nonfibrous silicate minerals. Silicosis and Silicate Disease Committee. *Arch Pathol Lab Med* 1988; 112 (7): 673-720.
12. Tchou-Wong KM, Harkin TJ, Chi C, Bodkin M, Rom WN. GM-CSF gene expression is normal but protein release is absent in a patient with pulmonary alveolar proteinosis. *Am J Respir Crit Care Med* 1997; 156 (6): 1999-2002. Erratum in: *Am J Respir Crit Care Med* 1998; 157 (4 Pt 1): 1353.
13. Godwin JD, Muller NL, Takasugi JE. Pulmonary alveolar proteinosis: CT findings. *Radiology* 1988; 169 (3): 609-13.
14. Albafouille V, Sayegh N, De Coudenhove S, Scheinmann P, De Blic J, Mamou-Mani T, et al. CT scan patterns of pulmonary alveolar proteinosis in children. *Pediatr Radiol* 1999; 29 (3): 147-52.
15. Chun CW, Lin FC, Tung SM, Liou RD, Chang SC. Diagnosis of pulmonary alveolar proteinosis: usefulness of papanicolaou-stained smears of bronchoalveolar lavage fluid. *Arch Intern Med* 2001; 161 (4): 562-6.
16. Gilmore LB, Talley FA, Hook GE. Classification and morphometric quantitation of insoluble materials from the lungs of patients with alveolar proteinosis. *Am J Pathol* 1988; 133 (2): 252-64.