

# Snoring-Induced Nerve Lesions in the Upper Airway

\*Rajesh P Poothrikovil and Mohammed A Al Abri

## آفات العصب الناتج عن الشخير في مجرى الهواء العلوي

راجيش بوثيريكوفيل بوشباك، محمد عبدالله العبري

**الملخص:** ينتشر الشخير المعتاد بشكل واسع النطاق بين الناس، وتشير التقارير إلى أنه يصيب ما يقرب من 40% من الرجال و 20% من النساء. قد تسبب الاهتزازات ذات التردد المنخفض أثناء الشخير إصابة في عضلات مجرى التنفس، وبشكل أكثر تحديدا إصابات الأعصاب المحيطة، تماما كما يحصل عند العمال الذين يستخدمون أدوات تهتز بشدة على مدار سنوات عديدة تؤدي بالنتيجة إلى تلف الأعصاب في الأيدي. أظهرت التحليلات النسيجية المرضية في العضلات التنفسية العليا وجود أدلة قوية على وجود خطورة متفاوتة من الآفات العصبية في مجموعات من مرضى يعانون من الشخير. أظهر تقييم الوظائف العصبية دليلا على إزالة التعصيب النشط والمزمن، وإعادة التعصيب في العضلات الحنكية البلعومية عند مرضى انقطاع النفس النومي. الآفات العصبية للعضلات التنفسية العليا الناتجة عن صدمة الاهتزازات تؤدي إلى ضعف قدرات التمدد الانعكاسي لتلك العضلات مما يؤدي إلى زيادة احتمال انهيار مجرى التنفس العلوي. العوامل العصبية التي تعتبر مسؤولة جزئيا عن تقدم انقطاع النفس الانسدادي النومي تبرر ضرورة تقييم مبكر للأشخاص اللذين يعانون من الشخير العادي.

**مفتاح الكلمات:** عصبى المنشأ، متلازمة انقطاع النفس الانسدادي النومي، العضلة الحنكية البلعومية، الشخير، مجرى الهواء العلوي، صدمة.

**ABSTRACT:** The prevalence of habitual snoring is extremely high in the general population, and is reported to be roughly 40% in men and 20% in women. The low-frequency vibrations of snoring may cause physical trauma and, more specifically, peripheral nerve injuries, just as jobs which require workers to use vibrating tools over the course of many years result in local nerve lesions in the hands. Histopathological analysis of upper airway (UA) muscles have shown strong evidence of a varying severity of neurological lesions in groups of snoring patients. Neurophysiological assessment shows evidence of active and chronic denervation and re-innervation in the palatopharyngeal muscles of obstructive sleep apnoea (OSA) patients. Neurogenic lesions of UA muscles induced by vibration trauma impair the reflex dilation abilities of the UA, leading to an increase in the possibility of UA collapse. The neurological factors which are partly responsible for the progressive nature of OSAS warrant the necessity of early assessment in habitual snorers.

**Keywords:** Neurogenic; Obstructive sleep apnoea syndrome (OSAS); Palatopharyngeal Muscle; Snoring; Upper airway; Trauma.

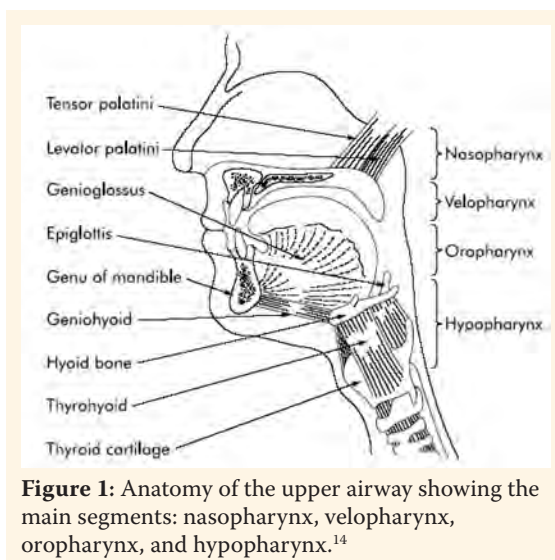
The American Academy of Sleep Medicine (AASM) defines snoring as a sound originating from the upper airway (UA) that does not occur with apnoea or hypoventilation, and that is caused by vibrations of different tissues in the pharynx.<sup>1</sup> A person who snores for more than 10–20% of a monitored night, or more than 3 or 4 nights a week is classified as a habitual snorer.<sup>2</sup> An association between snoring and obstructive sleep apnoea syndrome (OSAS) was first observed in 1975.<sup>3</sup> OSAS is considered a progressive disorder

that starts, often early in life, with habitual snoring.<sup>4</sup> Based on different epidemiological studies performed between 1980 and 2007, the mean prevalence of snoring in the general population is approximately 32% in men and 21% in women;<sup>5</sup> however, the prevalence of obstructive sleep apnoea (OSA) is 4% in men and 2% in women.<sup>6,7</sup> OSAS involves the intermittent cessation of breathing due to UA obstruction. In a person with OSAS, the UA muscles relax excessively during sleep. This allows tissues (e.g. tonsils and adenoids) supported by the

UA muscles to be drawn into the airway with each inspiration, and thereby obstruct the airflow. The sufferer makes increasingly stronger respiratory efforts to overcome the blockage, but ultimately arouses briefly to take several fast, deep breaths. During the arousal, the sufferer may gasp or snore loudly. This whole cycle recurs on resumption of sleep. If left untreated, OSAS leads to excessive daytime sleepiness, cognitive dysfunction, and impaired work performance, and is detrimental to the sufferer's health and quality of life. Clinical research shows that OSAS is strongly linked to a range of serious and even life-threatening chronic diseases such as stroke, heart failure, hypertension, diabetes, obesity and coronary heart diseases.<sup>8</sup> The aetiology of OSAS is only partly known.

## Anatomy and Physiology of the Upper Airway during Sleep

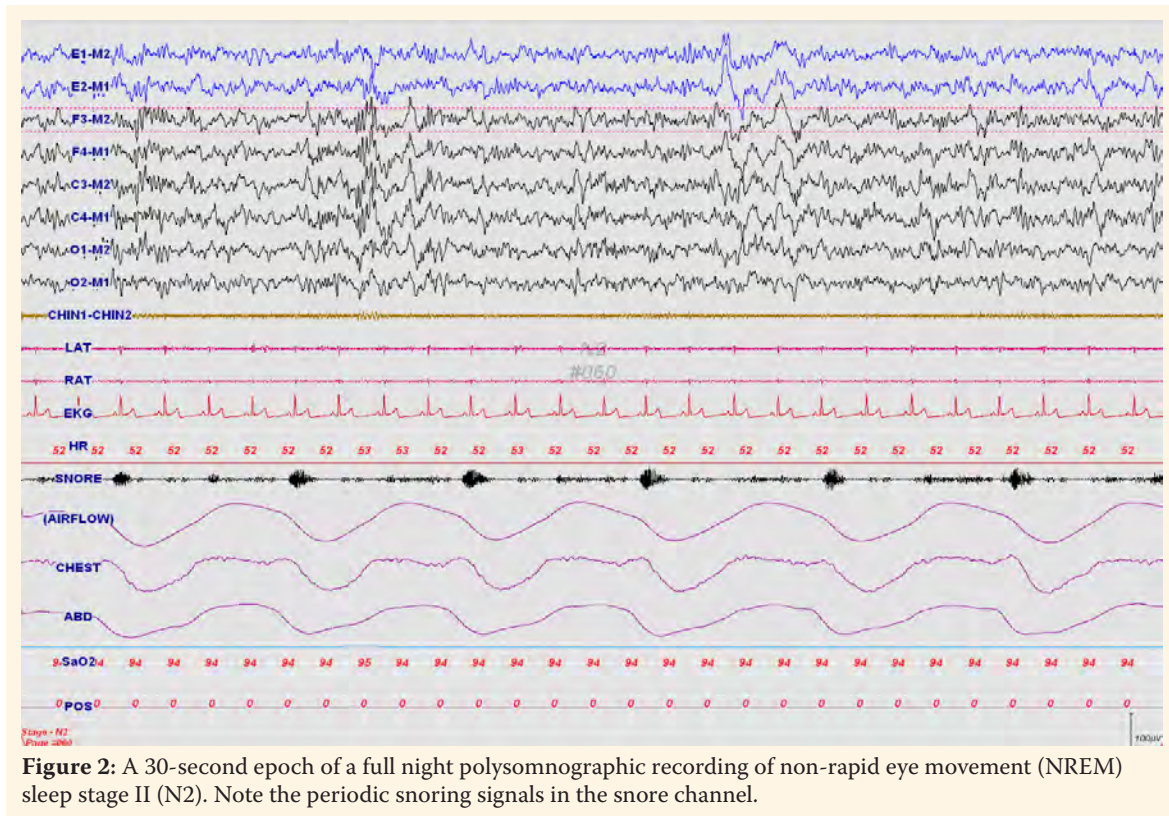
The UA is a complicated structure, usually divided into four anatomical subsegments: the nasopharynx, between the nares and hard palate; the velopharynx, between the hard palate and soft palate; the oropharynx, from the soft palate to the epiglottis, and the hypopharynx, from the base of the tongue to the larynx [Figure 1]. This total structure forms a passageway for movement of air from the nose to the lungs, and also participates in many competing physiological functions such as phonation and deglutition.<sup>9</sup> The UA is surrounded by 20 or more muscles, known collectively as UA muscles, which actively constrict and dilate the UA lumen.<sup>10</sup> These muscles can be broadly classified into four groups: muscles regulating the position of the soft palate, tongue, hyoid apparatus, and the posterolateral pharyngeal walls. These muscle groups interact in a complex fashion to determine the patency of the airway. The mandible and hyoid bones are the main craniofacial bony structures that determine the airway's size.<sup>11</sup> As there is no rigid structural support, the shape and size of the UA is dependent upon the position of soft tissue structures, like the soft palate, tongue, and the walls of the oropharynx. Radiographic images show that the narrowest region in both patients with OSAS and non-obese controls, while awake, is the region posterior to the soft palate.<sup>12,13</sup> The cross sectional area of this retropalatal region is smaller in OSAS



**Figure 1:** Anatomy of the upper airway showing the main segments: nasopharynx, velopharynx, oropharynx, and hypopharynx.<sup>14</sup>

patients than in non-obese controls.

Sleep disordered breathing (SDB) results from an imbalance between negative pharyngeal pressure and the opposing force of the UA muscles. Abnormal function of the UA, such as sleep-related suppression of UA muscle activity and a decrease in UA dilator muscle force are thought to be the main source of obstructions and symptoms in the OSAS.<sup>15,16</sup> Phasic activation of the muscles of the nose, pharynx and larynx has been shown to occur before diaphragm and intercostal muscle activity, suggesting a pre-activation of the UA muscles in preparation for the development of negative pressure.<sup>17,18</sup> The UA is rich in neural receptors which is a key factor of tonic genioglossus electromyogram (EMG) activity. During inspiration, the UA dilatory muscles, the genioglossus and geniohyoid contract, or shorten, their muscle fibres through an increase in EMG activity. These inspiration-related muscle activations result in the enlargement of the UA.<sup>19</sup> Loss of genioglossus EMG tone may lead to an increase in pharyngeal resistance.<sup>20</sup> In order to compensate for abnormal anatomy and/or a more collapsible pharyngeal airway, OSAS patients display augmented genioglossus muscle activity during wakefulness as compared with healthy subjects.<sup>21</sup> This reflex compensatory neuromuscular mechanism is lost at sleep onset (loss of awake compensation) in both the control and in OSAS patients, but is associated with pharyngeal collapse under conditions of chronic airway loading.<sup>22</sup> When the tongue moves posteriorly due to a decrease in genioglossus muscle activity, the base of the



**Figure 2:** A 30-second epoch of a full night polysomnographic recording of non-rapid eye movement (NREM) sleep stage II (N2). Note the periodic snoring signals in the snore channel.

tongue may push against the anterior wall of the soft palate causing narrowing of the velopharynx. Reduction in the traction between the tongue and the soft palate may increase the collapsibility of the velopharynx.<sup>23</sup> Apnoeas were shown to resolve with a burst of genioglossus EMG activation. It has been demonstrated that the velopharynx is the primary site of narrowing in 80% of patients, whereas two or more sites of narrowing are commonly observed in 82% of these.<sup>24</sup> An evaluation of the static properties of the pharyngeal wall and its surrounding muscles revealed a fundamental difference between the airway of the control subjects and those with OSAS in that the airway was closed at atmospheric pressure in subjects with OSAS, while active negative pressure was required to close the controls' airways, even in the absence of UA muscle activity.<sup>25</sup>

One of the commonest consequences of the changes in the properties of the UA that occur during sleep is the occurrence of snoring. The snoring sound is the result of vibrations of the soft tissues of the pharynx, soft palate and uvula having specific acoustic characteristics with frequencies ranging from 5 to 136 Hz.<sup>26</sup> SDB, such as snoring and other obstructive events, could be easily detected with a polysomnography (PSG) recording [Figure 2]. Polysomnography

takes multiple physiological measurements and is an excellent tool for evaluating sleep disorders.<sup>27</sup> Snoring can be detected and evaluated by means of small sensors in the form of piezo crystals or dynamic microphones taped laterally to the thyroid cartilage, or by utilising a nasal pressure transducer which continuously samples nasal air turbulence through a cannula. PSG provides an opportunity to assess the consequences of SDB, such as nocturnal desaturation, frequent arousals, and excessive day time sleepiness, and also plays an important role in the titration of continuous positive airway pressure (CPAP) treatment.

The palatopharyngeal muscle is of anatomical importance in the pharynx as it forms the internal longitudinal muscular layer around the wall of the pharynx. The muscle is located at the major site of obstruction in patients with OSAS and is therefore exposed to the vibration and stretch induced by heavy snoring and obstructive breathing.<sup>28,29</sup> It has been reported that long term employment which involves the use of vibrating tools such as jack hammers can cause local nerve lesions in the hands.<sup>30,31</sup> Researchers observed pathological changes in the vibration-exposed fingers, including a marked loss of nerve fibres suggestive of demyelinating neuropathy in the peripheral

nerves. Similarly, snoring produces a low-frequency vibration which may also cause peripheral nerve injury and physical trauma.

## Snoring-induced Upper Airway Nerve Damage

### THERMAL SENSITIVITY

Larsson *et al.* reported an impairment of thermal sensitivity in the oropharynx of patients with OSAS as compared with non-snoring age-matched control subjects.<sup>32</sup> Some patients with OSAS were completely unable to differentiate between heat and cold while tested on the tonsillar pillars, whereas no differences were noted at the tip of the tongue in patient and control groups, which indicates a local sensory dysfunction. They postulated that snoring-related vibrations and the deformation of UA structures in the case of apnoeas could lead to a very local pharyngeal sensory neuropathy, which could contribute to UA dysfunction during sleep. As there were only OSAS and non-snoring control groups in this study, a comparison between apnoeic snorers and non-apnoeic snorers was not possible.

### VASODILATION

In another study, laser Doppler perfusion monitoring combined with electrical stimulation (a method used to test vascular reactivity) was performed in the mucosa of the soft palate in patients with various degrees of UA obstruction and control subjects. Habitual snorers and patients with mild OSA showed exaggerated vasodilation as compared to controls. This could be the result of minor lesions with consequent re-innervation which increased the sensitivity to mechanical stimuli.<sup>33</sup> In contrast, patients with severe OSAS showed significantly reduced vasodilation as compared to controls, which could be due to the almost complete loss of afferent C-fibres, representing a permanent injury. These disturbances in the micro-circulation indicate the presence of a local afferent nerve lesion with a progressive nature in heavy snorers, both those with and without OSAS.

### SENSORY FUNCTIONS

Kimoff *et al.* assessed sensory functions of the UA (oropharynx) using two-point discrimination and vibration sensory threshold methods in snorers

and OSAS patients, and compared with age-matched controls.<sup>34</sup> They also assessed two control points (lower lip and hand) for each subject. This study showed that the sensory detection threshold using both methods was significantly increased in snorers and OSAS patients as compared to controls. Importantly, there was no significant difference between snorers and patients with OSAS. In contrast, the sensory threshold at control sites was similar in patients and controls. Vibrometry is usually employed to assess the functional integrity of the largest afferent sensory fibres to diagnose polyneuropathy. These findings reinforce the presence of a selective impairment of UA mucosal sensory function in patients with OSAS and in those who are heavy snorers. They suggest that this impairment may be an early change in the progression of UA obstruction during sleep, possibly developing as a consequence of vibration-related oedema or neural damage during snoring. Interestingly, after 6 months of continuous CPAP usage, OSAS patients showed a significant improvement in vibration sensory thresholds<sup>34</sup> thus providing strong evidence of the effectiveness of CPAP treatment. These results increase the importance of CPAP usage in the field of sleep medicine as an effective and non-comparable treatment. However, CPAP treatment fails to improve two-point discrimination, indicating a degree of permanent injury. Beginning CPAP treatment before symptoms worsen could be useful in limiting the severity of this permanent neural injury to the pharyngeal muscles.

### HISTOPATHOLOGIC FEATURES

Woodson *et al.* analysed the histopathologic features of pharyngeal tissue.<sup>35</sup> Transverse sections of the distal soft palate and uvula were qualitatively compared between apnoeics, severe snorers, and non-snorers using light and electron microscopy. Light microscopy of both apnoeics and non-apnoeic snorers revealed similar abnormalities such as mucous gland hypertrophy, focal atrophy of muscle fibres, and extensive oedema of the lamina propria with vascular dilation. No distinctive histopathologic findings were associated with the development of apnoea. Electron microscopy was used to reveal frequent focal degeneration of myelinated nerve fibres and axons in severe apnoeics. Similar histopathologic changes were

noted in apnoeics and non-apnoeic snorers. This is an indication of a common aetiology related to snoring-induced vibration trauma to pharyngeal tissue rather than directly related to apnoea or desaturation.

#### DENERVATION

Friberg *et al.* described a proliferation (increased density of sensory nerve terminals with abnormal localisation and appearance) of nerve endings in a pattern suggestive of nerve injury in biopsy specimens from the oropharyngeal mucosa of some snorers. However, the study focused mostly on OSAS subjects.<sup>36</sup> No such abnormalities were detected in non-snoring control subjects. Other muscle biopsy studies illustrated similar denervation type changes in palatopharyngeal muscles.<sup>37</sup> The relationship between vibration and stretch-induced trauma was reinforced in a study which showed a significant increase of morphological abnormalities characteristic of neurogenic lesions (type grouping, fascicular atrophy, and grouped atrophy) in the palatopharyngeal muscle of the entire group of snoring patients as compared to non-snoring controls.<sup>38</sup> They observed that the degree of muscle pathology increased in parallel with the proportion of obstructive breathing during sleep. This indicates that the proportion of the total sleep time spent in periodic obstructive breathing may be a surrogate quantitative measure of the magnitude of the snoring trauma to the pharyngeal tissues. Another finding in this study is that the vibration trauma of habitual snoring itself could initiate a local neurogenic lesion in vulnerable patients, before the additional trauma of stretch caused by periodic obstructive breathing. Palatopharyngeal muscle hypertrophy noted in some snorers could be neurogenic and could be due to the chronic stretching of innervated and denervated muscle fibres and/or overuse of partially denervated muscles.<sup>39</sup>

#### NEUROPHYSIOLOGICAL ASSESSMENTS

Finally, in a recent study, Svanborg conducted neurophysiological assessments of UA muscles by recording concentric needle EMG activity of palatopharyngeal muscles in 12 OSAS patients.<sup>40</sup> Ten out of 12 cases showed reduced EMG activity (recruitment pattern) at maximal voluntary effort with long and polyphasic (increased duration) motor unit potentials. These features typify

motor neuropathy (chronic denervation and reinnervation). Two patients showed spontaneous denervation activity (fibrillations and positive waves) suggestive of an active neuropathic process. Such findings were present in only 3 out of 15 habitual snorers. This study was of great importance in that it gives strong electrophysiological evidence of motor neuropathy in the UA muscles of OSAS patients. These findings reinforce the causative role of peripheral neurogenic lesions, in the progression from habitual snoring to clinical OSAS.

### Upper Airway Neuropathy in Progressive Snorers' Disease

It is obvious that the local UA afferent (sensory) and efferent (motor) nerve lesions are present due to snoring-induced vibration trauma in some patients with snoring and in most patients with OSAS. It has been reported that the higher sound intensity in apnoeic snorers versus non-apnoeic snorers is a result of greater negative pressures on the resumption of breathing, resulting in high flow rates, turbulent flow, and greater forces on the vibrating structures.<sup>41</sup> Several studies indicate that airway patency depends on a reflexogenic mechanism of afferent and efferent nerve pathways in the mucosa and upper airway muscles.<sup>42,43</sup> This reflex mechanism, as a reaction to the negative intrapharyngeal pressure, is responsible for the activation of dilatory muscles. Numerous studies have described protective UA dilator reflex responses to pulses of negative airway pressure, which act to maintain airway patency during sleep.<sup>44,45</sup> This reflex is assumed to be mediated by intra- or submucosal mechanosensory receptors. The neural drive to the UA dilator muscles is integrated at the level of brainstem motor nuclei where multiple neural inputs combine to produce a unitary output to the muscles.<sup>46</sup> Neurogenic lesions affecting upper airway muscles impair the ability of its reflexogenic dilation, leading to increased possibility of UA collapse. A reduced pharyngeal lumen and other risk factors (i.e. obesity and anatomic abnormalities) lead to an increased degree of periodic obstructed breathing. This causes more morphological abnormalities and neurogenic lesions, which supports the hypothesis of the progressive nature of snorers' disease.

## Causes and Treatment Options for Snoring

Other causes of habitual snoring, such as nasal septal deviation, nasal valve obstruction, chronic nocturnal nasal congestion, and craniomandibular abnormalities should be well identified.<sup>47-49</sup> Patients with chronic nasal obstruction often struggle to tolerate nasal CPAP. Humidification of inhaled air, correction of potential leakage of the nasal mask, and a trial of an oro-nasal mask are initial steps that can be considered to acclimatise patients to the CPAP treatment. Patients who still cannot tolerate CPAP, or have obvious nasal polyps or a distinctive abnormality of the nasal anatomy, should consider surgical treatment.<sup>48</sup> Correction of nasal obstructions has been reported to be an effective treatment of OSAS in patients who have nasal obstructions, but in those with craniomandibular abnormalities, correction has proved ineffective.<sup>50</sup> Improving nasal patency by external nasal dilators has some beneficial effects on subjective snoring, but not in patients with apnoeas.<sup>51</sup> Current evidence suggests that the nose may not play a significant role in the pathogenesis of OSA, but it seems to be of some relevance in the origin of snoring.<sup>51</sup>

Obesity is an independent risk factor for the development of snoring.<sup>52</sup> Simple snoring can be treated with general measures, including weight control and loss, avoidance of detrimental habits and toxic substances that interfere with sleep, modification of sleeping position and physical exercise.<sup>5</sup> Advancement of the mandible using a dental appliance has been shown to reduce the severity of OSA.<sup>53</sup> It is an effective alternate to CPAP in the treatment of snoring and milder form of OSAS.<sup>54</sup> Variable mandibular advancement devices have also been successful in the treatment of patients with severe OSAS.<sup>55</sup> Because the tongue attaches to the mandible directly, the tongue is expected to move anteriorly with the forward displacement of the mandible, thus improving oropharyngeal airway patency. However, no studies have been published to prove the efficacy of mandibular advancement devices in the improvement of upper airway neural injury in snoring patients.

## Conclusion

In summary, the progressive nature of OSAS can

be partly explained neurologically. OSAS begins with snoring-induced vibration trauma of nerves associated with the UA muscles. Histopathological, neurological, and neurophysiological signs of nerve lesions are detected in simple snorers without obstructive episodes. Periodic obstructive breathing phases expressed as a fraction of total sleep time could be a quantitative measure of the magnitude of snoring trauma to the pharyngeal tissues. Subjects with habitual snoring at risk of development of OSAS should be identified early. Beginning CPAP therapy before symptoms worsen should be considered as a preventive measure against permanent UA neuronal injury. Other options such as weight loss in obese individuals, surgical intervention for nasal obstructions, and mandibular advancement devices for craniofacial anomalies and narrow airway can also be considered in suitable patients, especially those who cannot tolerate CPAP. Studies of novel techniques may help in developing protocols to assess and manage habitual snorers.

## ACKNOWLEDGEMENTS

The authors would like to thank Dr. Abdullah Al-Asmi MD, FRCP(C), Neurology Unit, Department of Medicine, SQUH, and Mrs. Susan Al-Nabhani, Department of Clinical Physiology, SQUH, for their advice on this article. Also they would like to thank Mrs. Maryam Al Hooti, Department of Clinical Physiology, SQUH, for her help with the Arabic translation of the abstract.

## References

1. Thorpy MJ. The international classification of sleep disorders: diagnostic and coding manual. Lawrence KS, Ed. Kansas USA: Allen Press, Inc., 1990. Pp. 195-7.
2. Bearpark H, Elliott L, Grunstein R, Cullen S, Schneider H, Althans W et al. Snoring and sleep apnea. A population study in Australian men. *Am J Respir Crit Care Med* 1995; 151:1459-65.
3. Lugaresi E, Cirignotta F, Montagna P. Clinical approach to heavy snorers' disease and other sleep-related respiratory disorders. In: Peter JH, Podszus T, Wichert P, Eds. *Sleep Related Disorders and Internal Diseases*. Berlin: Springer-Verlag, 1975. Pp. 201-10.
4. Lugaresi E, Cirignotta F, Gerardi R, Montagna P. Snoring and sleep apnea: natural history of heavy snorers disease. In: Guilleminault C, Partinen M, Eds. *Obstructive Sleep Apnea Syndrome: Clinical Research and Treatment*. New York: Raven Press.

1990. Pp. 25–36.
5. Fiz JA, Prat JM, Jané R. Treatment of patients with simple snoring. *Arch Bronconeumol* 2009; 45:508–15.
  6. Young T, Palta M, Dempsey J, Skatrud J, Weber S, Badr S. The occurrence of sleep-disordered breathing among middle-aged adults. *N Engl J Med* 1993; 328:1230–5.
  7. Stardling JR. Obstructive sleep apnoea: Definitions, epidemiology, and natural history. *Thorax* 1995; 50:683–9.
  8. Shahar E, Whitney CW, Reline S, Lee ET, Newman AB, Javier NE, et al. Sleep disordered breathing and cardiovascular disease: Cross-sectional results of the Sleep Heart Health Study. *Am J Respir Crit Care Med* 2001; 163:19–25.
  9. Smith J, Wolkove N, Colacone A, Kreisman H. Coordination of eating, drinking and breathing in adults. *Chest* 1989; 96:578–82.
  10. Fouke JM, Teeter JP, Strohl KP. Pressure-volume behavior of the upper airway. *J Appl Physiol* 1986; 61:912–8.
  11. Lyberg T, Krogstad O, Djupesland G. Cephalometric analysis in patients with obstructive sleep apnoea syndrome I. Skeletal morphology. *J Laryngol Otol* 1989; 103:287–92.
  12. Ryan CE, Lowe AA, Li D, Fleetham JA. Three-dimensional upper airway computed tomography in obstructive sleep apnea. A prospective study in patients treated by uvulopalatopharyngoplasty. *Am Rev Respir Dis* 1991; 144:428–32.
  13. Horner RL, Shea SA, McIvor J, Guz A. Pharyngeal size and shape during wakefulness and sleep in patients with obstructive sleep apnoea. *Q J Med* 1989; 168:719–35.
  14. Fogel RB, Malhotra A, White DP. Sleep.2: Pathophysiology of obstructive sleep apnoea/hypopnoea syndrome. *Thorax* 2004; 59:159–63.
  15. Remmers JE, Degroot WJ, Sauerland EK, Anch AM. Pathogenesis of upper airway occlusion during sleep. *J Appl Physiol* 1978; 44:931–8.
  16. Brouillette RT, Thach BT. A neuromuscular mechanism maintaining extrathoracic airway patency. *J Appl Physiol* 1979; 46:772–9.
  17. Strohl KP, Hensley MJ, Hallett M, Saunders NA, Ingram RHJ. Activation of upper airway muscles before onset of inspiration in normal humans. *J Appl Physiol* 1980; 49:638–42.
  18. Van Lunteren E, Van de Graaff WB, Parker DM, Mitra J, Haxhiu MA, Strohl KP, et al. Nasal and laryngeal reflex responses to negative upper airway pressure. *J Appl Physiol* 1984; 56:746–52.
  19. Kobayashi I, Perry A, Rhymer J, Wuyam B, Hughes P, Murphy K, et al. Inspiratory coactivation of the genioglossus enlarges retroglossal space in laryngectomized humans. *J Appl Physiol* 1996; 80:1595–604.
  20. White DP, Lombard RM, Cadieux RJ, Zwillich CW. Pharyngeal resistance in normal humans: Influence of gender, age, and obesity. *J Appl Physiol* 1985; 58:365–71.
  21. Mezzanotte WS, Tangel DJ, White DP. Waking genioglossal electromyogram in sleep apnea patients versus normal controls (a neuromuscular compensatory mechanism). *J Clin Invest* 1992; 89:1571–9.
  22. Mezzanotte WS, Tangel DJ, White DP. Influence of sleep onset on upper-airway muscle activity in apnea patients versus normal controls. *Am J Respir Crit Care Med* 1996; 153:1880–7.
  23. Isono S, Tanaka A, Sho Y, Konno A, Nishino T. Advancement of the mandible improves velopharyngeal patency. *J Appl Physiol* 1995; 79:2132–8.
  24. Morrison DL, Launois SH, Isono S, Feroah TR, Whitelaw WA, Remmers JE. Pharyngeal narrowing and closing pressures in patients with obstructive sleep apnea. *Am Rev Respir Dis* 1993; 148:606–11.
  25. Isono S, Morrison DL, Launois SH, Feroah TR, Whitelaw WA, Remmers JE. Static mechanics of the velopharynx of patients with obstructive sleep apnea. *J Appl Physiol* 1993; 75:148–54.
  26. Beck R, Odeh M, Oliven A, Gavriely N. The acoustic properties of snores. *Eur Respir J* 1995; 8:2120–8.
  27. Douglas NJ, Thomas S, Jan MA. Clinical value of polysomnography. *Lancet* 1992; 339:347–50.
  28. Suratt PM, Dee P, Atkinson RL, Armstrong P, Wilhoit SC. Fluoroscopic and computed tomographic features of the pharyngeal airway in obstructive sleep apnea. *Am Rev Respir Dis* 1983; 127:487–92.
  29. Shepard JW Jr, Thawley SE. Localization of upper airway collapse during sleep in patients with obstructive sleep apnea. *Am Rev Respir Dis* 1985; 132:211–15.
  30. Takeushi T, Futatsuka M, Imanishi H, Yamada S. Pathological changes observed in the finger biopsy of patients with vibration-induced white finger. *Scand J Work Environ Health* 1986; 12:280–3.
  31. Lundborg G, Dahlin L, Hansson HA, Kanje M, Necking LE. Vibration exposure and peripheral nerve fiber damage. *J Hand Surg Am* 1990; 15:346–51.
  32. Larsson H, Carlsson-Nordlander B, Lindblad LE, Norbäck O, Svanborg E. Temperature thresholds in the oropharynx in patients with obstructive sleep apnea syndrome. *Am Rev Respir Dis* 1992; 146:1246–9.
  33. Friberg D, Gazelius B, Lindblad LE, Nordlander B. Habitual snorers and sleep apnoics have abnormal vascular reactions of the soft palate mucosa on afferent nerve stimulation. *Laryngoscope* 1998; 108:431–6.

34. Kimoff RJ, Sforza E, Champagne V, Ofiara L, Gendron D. Upper airway sensation in snoring and obstructive sleep apnea. *Am J Respir Crit Care Med* 2001; 164:250–5.
35. Woodson BT, Garancis JC, Toohill RJ. Histopathologic changes in snoring and obstructive sleep apnea syndrome. *Laryngoscope* 1991; 101:1318–22.
36. Friberg D, Gazelius B, Tomas Hökfelt, Nordlander B. Abnormal afferent nerve endings in the soft palatal mucosa of sleep apnoics and habitual snorers. *Regul Pept* 1997; 71:29–36.
37. Edstrom L, Larsson H, Larsson L. Neurogenic effects on the palatopharyngeal muscle in patients with obstructive sleep apnoea: a muscle biopsy study. *J Neurol Neurosurg Psychiatry* 1992; 55:916–20.
38. Friberg D, Ansved T, Borg K, Carlsson-Nordlander B, Larsson H, Svanborg E. Histological indications of a progressive snorer's disease in an upper airway muscle. *Am J Respir Crit Care Med* 1998; 157:586–93.
39. Gutmann, L. Neurogenic muscle hypertrophy. *Muscle Nerve* 1996; 19:811–18.
40. Svanborg E. Impact of obstructive apnea syndrome on upper airway respiratory muscles. *Respir Physiol Neurobiol* 2005; 147:263–72.
41. Wilson K, Stoohs RA, Mulrooney TF, Johnson LJ, Guilleminault C, Huang Z. The snoring spectrum: acoustic assessment of snoring sound intensity in 1,139 individuals undergoing polysomnography. *Chest* 1999; 115:762–70.
42. Horner RL, Innes JA, Murphy K, Guz A. Evidence for reflex upper airway dilator muscle activation by sudden negative airway pressure in man. *J Physiol* 1991; 436:15–29.
43. Wheatley JR, Tangel DJ, Mezzanotte WS, White DP. Influence of sleep on response to negative airway pressure of tensor palatini muscle and retropalatal airway. *J Appl Physiol* 1993; 75:2117–24.
44. Horner RL, Innes JA, Morrell MJ, Shea SA, Guz A. The effect of sleep on reflex genioglossus muscle activation by stimuli of negative airway pressure in humans. *J Physiol* 1993; 476:141–51.
45. Mortimore IL, Douglas NJ. Palatal muscle EMG response to negative pressure in awake sleep apneic and control subjects. *Am J Respir Crit Care Med* 1997; 156:867–73.
46. Bianchi A, Denavit-Saubie M, Champagnat J. Central control of breathing in mammals: Neuronal circuitry, membrane properties, and neurotransmitters. *Physiol Rev* 1995; 75:1–31.
47. Young T, Finn L, Palta M. Chronic nasal congestion at night is a risk factor for snoring in a population-based cohort study. *Arch Intern Med* 2001; 161:1514–19.
48. Lofaso F, Coste A, d'Ortho MP, Zerah-Lancner F, Delclaux C, Goldenberg F, et al. Nasal obstruction as a risk factor for sleep apnoea syndrome. *Eur Respir J* 2000; 16:639–43.
49. Battagel JM, L'Estrange PR. The cephalometric morphology of patients with obstructive sleep apnoea (OSA). *Eur J Orthod* 1996; 18:557–69.
50. Dayal VS, Phillipson EA. Nasal surgery in the management of sleep apnea. *Ann Otol Rhinol Laryngol* 1985; 94:550–4.
51. Kohler M, Bloch KE, Stradling JR. The role of the nose in the pathogenesis of obstructive sleep apnoea and snoring. *Eur Respir J* 2007; 30:1208–15.
52. Kauffman F, Annesi J, Neukirch F, Oryszczym MP, Alpezoitch A. The relation between snoring and smoking, body mass index, age, alcohol consumption and respiratory symptoms. *Eur Respir J* 1989; 2:599–603.
53. Eveloff SE, Rosenberg CL, Carlisle CC, Millman RP. Efficacy of a Herbst mandibular advancement device in obstructive sleep apnea. *Am J Respir Crit Care Med* 1994; 149:905–9.
54. O'Sullivan RA, Hillman DR, Mateljan R, Pantin C, Finucane KE. Mandibular advancement splint: an appliance to treat snoring and obstructive sleep apnea. *Am J Respir Crit Care Med* 1995; 151:194–8.
55. Lowe AA, Sjöholm TT, Fleetham JA, Fregusson KA, Remmers JE. Treatment, airway and compliance effects of a titrable oral appliance. *Sleep* 2000; 23:S172–8.