

Transabdominal sonographic findings in the diagnosis of urinary bladder abnormalities

Moawia Gamerddin^{1,2},
Nazar Alhassan¹,
Abdelmoneim Saeed³,
Mohamed Yousef^{2,4}

¹Alzaeim Alazhari University, Faculty of Radiological Sciences and Medical Imaging, Khartoum Bahri, Sudan,
²Taibah University, College of Medical Applied Sciences, Department of Diagnostic Radiologic Technology, Almadinah Almunawwarah, KSA,
³National College, Khartoum,
⁴College of Medical Radiologic Science, Sudan University of Science and Technology, Khartoum, Sudan

Abstract

Objectives: This study was to assess the diagnostic capabilities of Transabdominal Sonographic Findings in the Diagnosis of Urinary Bladder abnormalities. **Methods and Material:** In a cross-sectional study design, was conducted in different hospitals and clinical centers at Khartoum State. A total of 110 patients with symptoms of urinary bladder diseases were included in this study who had been selected and scanned with ultrasound using the appropriate technique **Results:** The study confirmed that cystitis was the commonest vesical pathology and common in female than male, Hematuria 29.75%, dysuria 25%, and showed that schistosomiasis mainly involve the male. **Conclusions:** This study concluded that ultrasonography is the first line of investigation as well as laboratory test (urine general) since it is safe, accurate and not time consuming.

Key words: Bladder, schistosomiasis, sonography, vesical

INTRODUCTION

Transabdominal sonography is a first-line imaging technique for evaluation of the upper and lower abdomen because it is almost universally available, is non-invasive, lacks ionizing radiation and is well accepted by patients. With regard to sonography of the urinary bladder, much more emphasis has been placed on its capability of being a quick method for establishing post-voiding bladder volumes^[1] and aid in avoiding unnecessary catheterization and a method for diagnosing outlet obstruction by measuring bladder wall thickness and bladder mass.^[2] Now-a-days, new modes for acquiring sonographic images such as tissue harmonic imaging and spatial compound imaging are widely available and have improved diagnostic performance for sonographic examinations in a variety of

abdominopelvic pathologic conditions.^[3-6] Ultrasonography plays a great role in demonstrating the pathology of the renal system especially the urinary bladder. The ultrasound imaging uses high frequency non-audible waves to produce images at different planes.^[7] As it is a non-invasive medical test that helps physicians diagnose and treat medical diseases. A pelvic ultrasound provides pictures of the urinary, which act as acoustic window for several structures in male and female.^[8] Ultrasound is a suitable imaging modality to examine the pelvic organs and it is an important modality to scan the urinary bladder. Hence, it is sensitive for demonstrating different vesical pathologies such as cystitis, calculi, diverticulum, polyps and masses of the urinary bladder.^[9,10] Now-a-days the symptoms and manifestation of the urinary bladder disease became serious and observed in different patients. Most of them presents with symptoms such as dysuria and hematuria. Patients with painless hematuria are usually suspected as malignant masses. Laboratory test is not enough to characterize the vesical pathology.^[11]

Hence, ultrasound scanning is very important to evaluate and characterize these vesical abnormalities to avoid the aggressive prognosis. Anatomically, the bladder has a strong

Access this article online

Quick Response Code:



Website:

www.sudanmedicalmonitor.org

DOI:

10.4103/1858-5000.133011

Address for correspondence:

Dr. Moawia Bushra, Taibah University, College of Medical Applied Sciences, Department of Diagnostic Radiologic Technology,
E-mail: m.bushra@yahoo.com, Mob; 00966540875523

muscular wall, its shape and relations vary according to the amount of urine that it contains when it is empty. It has a pyramidal shape and a maximum capacity of 500 ml.^[12] The normal sonographic appearance of the urinary bladder (which must be filled with urine) is anechoic, ovoid shape with smooth wall. There are different pathological changes which interrupt this normal appearance such as acute and chronic cystitis which increase the thickness of the wall. Sonographically, the chronic inflammatory changes may be seen as cysts or solid papillary masses.^[13] These are difficult to differentiate from malignancy.^[14] Schistosomiasis is a common condition by which human are infected with schistosoma cerceria that invade the skin and enter the venous system. The condition may lead to bladder cancer of any histological sort, particularly squamous cell carcinoma.^[15] Sonographically, it may be normal in early or mild cases but often shows wall thickening and single or multiple polypoid lesions.^[16] Vesical stones is one of the disorder that cause symptoms and most of these stones are composed of calcium and magnesium phosphate mixture. Sonographically, stones are seen easily if the bladder is full and seen as echogenic foci casting distal shadow and mobile.^[17] The malignant masses had been demonstrated in this study. Approximately, 15-25% has evidence of the muscle erosion and most common site of tumors is the trigone, lateral and posterior walls and bladder neck. Sonographically, these tumors appear as irregular hyperechoic masses that disrupt the smooth bladder wall.^[17]

The aim of this study was to assess the diagnostic capabilities of transabdominal sonographic findings in the diagnosis of urinary bladder abnormalities.

MATERIALS AND METHODS

This is a descriptive and practical study, conducted at different hospitals and clinical centers in Khartoum State during the period May to October 2011. 110 patients (different ages)—with symptoms of urinary bladder disease—had been selected for the study. The patients were scanned with ultrasound using the universal technique by using different ultrasound machines including: (1) Aloka SSD 500, Probe: Convex 3.5 MHz, (2) Shimadzu 2200, Probe: Convex 3.5 MHz, (3) GE logic 5 Probe: Convex 3.5, (4) Sonyace 5000, Probe: Convex 3.5. The patients had already been sent for ultrasound request from their referring doctors. The patients were scanned in supine position with full bladder with the probe placed supra-pubic and multiple planes performed to image the U. bladder and assess the findings. The clinical data sheet was designed to include these sonographic findings and the other parts of data (history, gender, age, etc...) had

been collected by direct questions to the patients. The data was analyzed using the Statistical Package for the Social Sciences (SPSS company, version 16) software program and presented in tables and figures. The names of the patients were not mentioned and there was permission taken to use these data for research only.

RESULTS

The results that include 110 patients male (59.1% are analyzed and presented in tables and diagrams. This study demonstrated variable vesical pathologies using ultrasound as the basic tool. It had been found that acute and chronic cystitis were the most common diseases of the urinary bladder. Vesical blood was the second finding, which represent variable pathological changes that need other imaging modality for differential diagnosis. Scistosomiasis was noted to affect mainly the males no cases were detected for female. It was noted that chronic cystitis showed high prevalence 16.2% [Figure 1] and hematuria is the common symptom 11% in Figure 2. Acute cystitis was commonly affected female whose age less than 20 years old 2.7% [Figure 3]. Chronic cystitis was commonly affected younger female and both gender above 60 years old 2.7% and 2.7% [Figure 4]. Vesical masses were common in male at age of 60 to 69 years old [Figure 5].

DISCUSSION

Ultrasound is effective in evaluating pathologic entities in and around the urinary bladder. In this study, 110 patients with symptoms had been scanned with ultrasound. Their ages ranged between 1 up to 79-year-old, 65 males (59%) and 45 females (41%). It had been observed that, hematuria was the most clinical symptoms (28%), followed by dysuria as the second symptom (25%). Most of the vesical diseases showed red blood cells in the urine. The study revealed that acute and chronic cystitis were the most common vesical diseases and represent approximately 28% of the cases. It was observed that schistosomiasis affect the male only because their work related to the water (farmers) which is the source of the parasite. The study showed that, the diverticulum involved the males more than female; this could be due to benign prostatic hypertrophy which was common in older male. In this study, the incidence of polyps is rare and there was only three cases (2.7%) as shown on Figure 6. The ultrasound finding of vesical blood clot was the second common finding after acute and chronic cholecystitis representing 9.9% [Table 1]. This is due to that many pathological changes and diseases cause vesical blood clots such as: Inflammation of the prostate, tuberculosis and early malignant changes. Hence, in these cases other

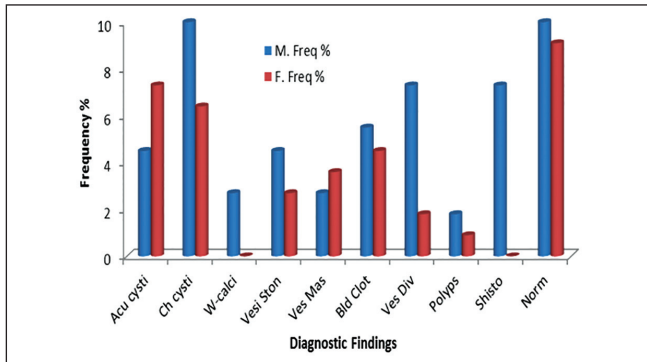


Figure 1: Ultrasound findings versus gender

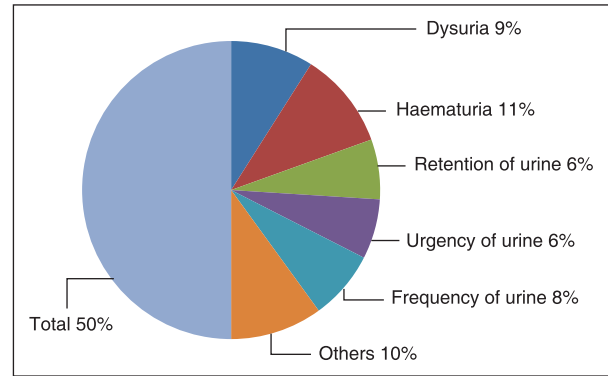


Figure 2: Frequency distribution and percentage of symptoms

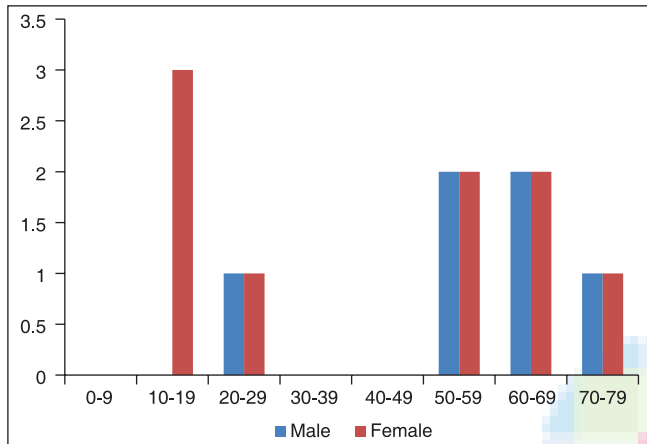


Figure 3: Frequency distribution and percentage of acute cystitis

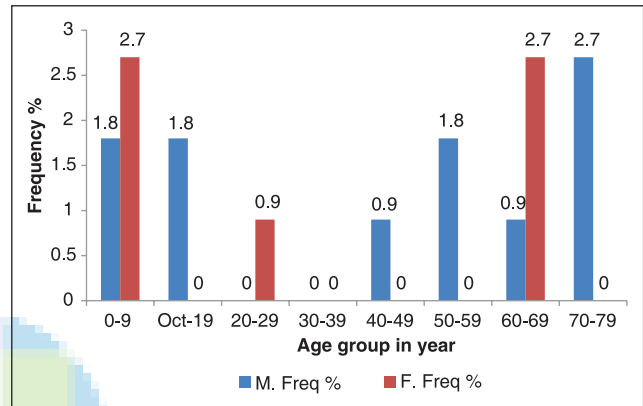


Figure 4: Frequency distribution and percentage of chronic

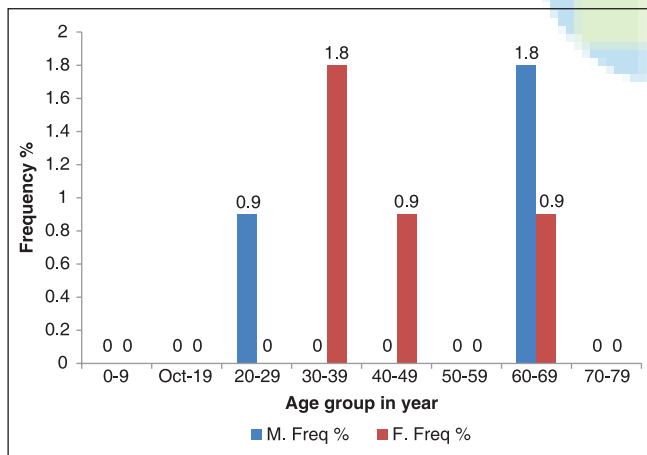


Figure 5: Frequency distribution and percentage of vesical masses

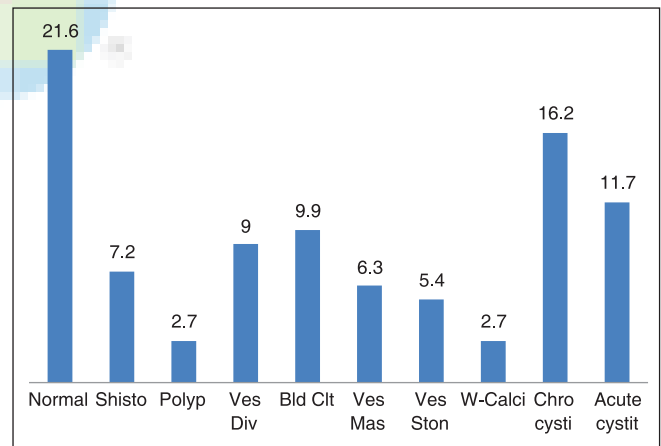


Figure 6: Percentage of ultrasonographic findings

Table 1: Frequency distribution and percentage of symptoms among gender

Symptom	M	Frequency %	F	Frequency %
Dys U	7	6.3	14	12.6
Haem U	15	13.5	10	9
Ret U	15	13.5	0	0
Urgen U	9	8.1	7	6.3
Freq U	12	10.8	6	5.4
Others	13	11.7	11	9.9

imaging modality (computed tomography with biopsy) is very important for differential diagnosis.^[9]

CONCLUSION


The study concluded that ultrasound should be the first line for detection of pelvic symptoms as it is in expensive, safe very sensitive and accurate.

REFERENCES

1. Simforoosh N, Dadkhah F, Hosseini SY, Asgari MA, Nasserri A, Safarinejad MR. Accuracy of residual urine measurement in men: Comparison between real-time ultrasonography and catheterization. *J Urol* 1997;158:59-61.
2. Kelly CE. Evaluation of voiding dysfunction and measurement of bladder volume. *Rev Urol* 2004;6 Suppl 1:S32-7.
3. Shapiro RS, Wagreich J, Parsons RB, Stancato-Pasik A, Yeh HC, Lao R. Tissue harmonic imaging sonography: Evaluation of image quality compared with conventional sonography. *AJR Am J Roentgenol* 1998;171:1203-6.
4. Desser TS, Jeffrey RB Jr, Lane MJ, Ralls PW. Tissue harmonic imaging: Utility in abdominal and pelvic sonography. *J Clin Ultrasound* 1999;27:135-42.
5. Yücel C, Ozdemir H, Aşık E, Oner Y, Işık S. Benefits of tissue harmonic imaging in the evaluation of abdominal and pelvic lesions. *Abdom Imaging* 2003;28:103-9.
6. Oktar SO, Yücel C, Ozdemir H, Ulutürk A, Işık S. Comparison of conventional sonography, real-time compound sonography, tissue harmonic sonography, and tissue harmonic compound sonography of abdominal and pelvic lesions. *AJR Am J Roentgenol* 2003;181:1341-7.
7. Taylor J, Kenneth W. *Atlas of Gray Scale Ultrasonography*. 3rd ed. London: Churchill Livingstone; 1988.
8. Mccan M. *The Burwin Instiute of Diagnostic Medical – Ultrasonography of the Abdomen and Superficial Scanning*. 2nd ed. Part 2. USA: Manitoba, Canada 1992.
9. Jones FM, Curry RA, Tempkin BB. *Ultrasonography; An Introduction to Normal Structure and Functional Anatomy*. New York, USA: Saunders Company; 1995.
10. Available from: <http://www.e-medicine.com> [Last accessed on 2013 June 1].
11. Carol M Rumack; Stephanie R Wilson; J William Charboneau, 1998 2nd ed, St. Louis: Mosby.
12. Ardawi MS, Sukkar MY, El-Munshid MS. *Concise Human Physiology*. 2nd ed. London, England: Blackwell Science; 2000.
13. Bisset R, Ichan A. *Differential Diagnosis in Abdominal Ultrasound*. London, England: Linda Berilliere Tridal; 1990.
14. Gartener C, Hiatt J. *Color Textbook of Histology*. 2nd ed. New York: Saunders Company; 2001.
15. McDicken WN. *Diagnostic Ultrasound, Principles and Use of Instruments*. 2nd ed. Chichester: John Wiley and Sons; 1990.
16. Meire HB, Farrant P. *Basic Clinical Ultrasound*. Kent: British Institute of Radiology; 1982.
17. Putz R, Pabst R. Sobotta. Vol. 2. London: Williams and Wilkins Publishers; 1993.

How to cite this article: Gamerddin M, Alhassan N, Saeed A, Yousef M. Transabdominal sonographic findings in the diagnosis of urinary bladder abnormalities. *Sudan Med Monit* 2013;8:179-82.

Source of Support: Nil. **Conflict of Interest:** None declared.



New features on the journal's website

Optimized content for mobile and hand-held devices

HTML pages have been optimized of mobile and other hand-held devices (such as iPad, Kindle, iPod) for faster browsing speed.

Click on **[Mobile Full text]** from Table of Contents page.

This is simple HTML version for faster download on mobiles (if viewed on desktop, it will be automatically redirected to full HTML version)

E-Pub for hand-held devices

EPUB is an open e-book standard recommended by The International Digital Publishing Forum which is designed for reflowable content i.e. the text display can be optimized for a particular display device.


Click on **[EPub]** from Table of Contents page.

There are various e-Pub readers such as for Windows: Digital Editions, OS X: Calibre/Bookworm, iPhone/iPod Touch/iPad: Stanza, and Linux: Calibre/Bookworm.

E-Book for desktop

One can also see the entire issue as printed here in a 'flip book' version on desktops.

Links are available from Current Issue as well as Archives pages.

Click on  View as eBook