

Influence of bimaxillary protrusion on the perception of smile esthetics

Terki K. Almutairi, BDS, MSc, Sahar F. Albarakati, BDS, MSc, Abdullah M. Aldrees, BDS, DMSc.

ABSTRACT

الأهداف: تقييم أثر بروز الأسنان في الفكين على جمال الابتسامة من وجهة نظر المتخصصين في طب الأسنان والعامّة.

الطريقة: شارك 150 مُقيماً موزعون بالتساوي بين المجموعات (أطباء تقويم الأسنان، وأطباء الأسنان، والأفراد العاديين) في هذه الدراسة المستعرضة (في الفترة من أبريل إلى ديسمبر عام 2012م، في الرياض، المملكة العربية السعودية). وتكونت عينة المرضى من 14 مريضة تم توزيعهن بالتساوي إلى مجموعتين: مريضات لديهن بروز بالأسنان في الفكين، ومريضات أجريت لهنّ معالجة تقويمية بخلع أربعة ضواحك. التُقِّطت صورتان موحَّدتان للابتسامة (أمامية و جانبية مُقَرَّبَة) وصورة أشعة سيفالومترية لكل مريضة. طلب من المشاركين تقييم جاذبية كل صورة وفقاً لمقياس 100 ملم للتماثلية البصرية. أُجري قياس ارتباط التقييم الجمالي بالقياسات السيفالومترية للمريضات.

النتائج: تمّ تقييم مجموعة بروز الأسنان في الفكين على أنها أقل جاذبية من المجموعة المعالجة لدى كل مجموعات المُقيِّمين. وأظهرت المقارنة بين المجموعات أن الأشخاص العاديين كانوا أقل تقبلاً لبروز الأسنان من المتخصصين في طب الأسنان. وعند مقارنة منظري الابتسامة، بدا أنّ تقييم جمال الصورة الأمامية والصورة الجانبية للابتسامة ذاتها غير متوافق. كشف التحليل التلازمي أن القياس السني ذو الارتباط الأعلى السلبي بجمال الابتسامة كانت زاوية U1-PP.

الخاتمة: اعتُبر المرضى الذين يعانون من بروز الأسنان في الفكين أقل جاذبية من المرضى الذين عولجوا من هذه الحالة، وكان هذا واضحاً بشكل خاص عند الأشخاص العاديين. تُحدِّث زيادة ميل القواطع العلوية وكذلك الانخفاض في الزاوية بين السنية زيادة في تأثير بروز الأسنان في الفكين.

Objectives: To evaluate the impact of bimaxillary protrusion on smile esthetics as perceived by dental professionals and laypersons.

Methods: One hundred and fifty evaluators, equally distributed into their respective panels (orthodontists, general dentists, and laypersons), participated in this

cross-sectional study conducted in April to December 2012 in Riyadh, Saudi Arabia. The patient sample consisted of 14 female patients divided equally into 2 groups: bimaxillary protrusion patients, and patients who have had 4-premolar extraction treatment. Two standardized photographs (frontal and three-quarter close-up smile views), and a lateral cephalogram were taken for each patient. The evaluators were asked to rate the attractiveness of each photo according to a 100-mm visual analog scale. These esthetic ratings were correlated with the patients' cephalometric measurements.

Results: The bimaxillary protrusion group was rated significantly as less attractive than the treatment group by each evaluator panel. Panel comparison showed that laypeople were less receptive of bimaxillary protrusion than dental professionals. Frontal and three-quarter views of the same smiles were not similarly rated for esthetic perceptions. Correlational analysis revealed that the dentoalveolar measurement with the highest significant negative correlation to the smile esthetics was the upper incisors to palatal plane (U1-PP) angle.

Conclusion: Patients with bimaxillary protrusion were found to be less attractive than patients who were treated for the condition. This was especially evident among the laypersons. An increase in the upper incisor inclination, as well as a decrease in the interincisal angle compounds the bimaxillary effect.

*Saudi Med J 2015; Vol. 36 (1): 87-93
doi: 10.15537/smj.2015.1.9480*

From the Dental Department (Almutairi), Prince Sultan Military Medical City, and the Division of Orthodontics (Albarakati, Aldrees), Department of Pediatric Dentistry and Orthodontics, College of Dentistry, King Saud University, Riyadh, Kingdom of Saudi Arabia.

Received 21st May 2014. Accepted 24th November 2014.

Address correspondence and reprint request to: Prof. Sahar F. Albarakati, Director, Graduate Program in Orthodontics, Division of Orthodontics, Department of Pediatric Dentistry and Orthodontics, College of Dentistry, King Saud University, PO Box 60169-38, Riyadh 11545, Kingdom of Saudi Arabia. E-mail: salbarakati96@gmail.com

Bimaxillary protrusion is a condition characterized by protrusive and proclined upper and lower incisors and an increased prominence of the lips.¹ It is seen commonly in African-American and Asian populations, but it can be seen in almost every ethnic group.¹ Many patients with bimaxillary protrusion seek orthodontic care to decrease this procumbency. The goals of orthodontic treatment of this condition include the retraction of maxillary and mandibular incisors with a resultant decrease in soft tissue procumbency and convexity.¹ This is most commonly achieved by the extraction of the 4 first premolars.¹⁻⁴ In a study by Farrow et al,² the African Americans preferred a straighter profile than what has been measured as normal for their race. Dawjee et al⁵ found that most African subjects with bimaxillary protrusion would want an extraction orthodontic treatment to change their facial profile to the ideal. More recently, Marques et al⁴ assessed the esthetic perceptions of the results of orthodontic treatment that alters the profile of black patients with bimaxillary protrusion through the extraction of 4 premolars. Their findings supported the view that the society perceives straight profiles as esthetically more pleasing in comparison with protruding profiles. All previously published studies have reported the perceived esthetics of bimaxillary protrusion based on profile views. The problem with this is that people do seldom see their own profiles. They evaluate their facial smile, or dental esthetics from a frontal view, and therefore, the usefulness of this approach is questionable.⁶ DeLoach⁷ supported this notion when he found that participants could not recognize their own profile type, and they had never given any thought to the nature of their own facial profile. He suggested that the laypersons' esthetic preferences may be based primarily on facial features other than the profile.⁷ Esthetic perception varies from person to person and is influenced by their personal experience and social environment.⁶ For this reason, professional opinions regarding the evaluation of esthetics may not coincide with the perceptions and demands of patients or laypeople. Several studies revealed that dentists, particularly orthodontists, are less tolerant than the general public to some

dentofacial attributes.⁸⁻¹² As a result, some dentists and orthodontists might overestimate the need for orthodontic treatment.¹¹ On the other hand, some studies indicated that lay individuals are less tolerant than the dental clinicians.¹³⁻¹⁶ This kind of disagreement might lead to the misunderstanding of the orthodontic patients' demands. Despite these important issues, there is a paucity of information in the literature in terms of the perceived impact of bimaxillary protrusion on smile esthetics. The main aims of the present study were to evaluate the esthetic impact of bimaxillary protrusion in different close-up smile views as perceived by orthodontists, general dentists, and laypersons, and correlate their perceptions with specific cephalometric measurements.

Methods. Ethical approval was obtained from the respective committee at the College of Dentistry Research Center (CDRC) of King Saud University. Patients were recruited from the orthodontic clinics at the College of Dentistry and other orthodontic clinics in Riyadh, Saudi Arabia between April to December 2012. Before obtaining the records, informed consent was signed by each patient granting the permission to use their photographs. The bimaxillary protrusion group consisted of 7 subjects who were potential orthodontic patients, while the treatment group consisted of 7 patients who were selected during routine post-treatment appointments. The inclusion criteria of the 2 groups were: female, above 16 years of age, with a normal upper lip length (the normal length from subnasale to upper lip inferior is 19-22 mm),¹⁷ a normal anterior smile height (the exposure when smiling would be in the range of $\frac{3}{4}$ of upper central incisors crown length to 2 mm of gingival tissue),^{17,18} and a Class I molar relationship. Patients who presented with dental features that would have deleterious effects on the smile, such as diastema, deep bite, open bite, increased overjet, maxillary occlusal plane canting, crowding, rotations, and malformed teeth were excluded from the study. In addition to the above mentioned criteria, the bimaxillary protrusion group was selected to have complete permanent dentition (except for the third molars), and an interincisal angle less than 118°.¹⁹ The treatment group consisted of patients who have had 4 premolars extracted, and completed their orthodontic treatment with a final interincisal angle greater than 123°.¹⁹ Two standardized photographs (frontal and three-quarter close-up smile views) were taken for each patient by the same investigator. These photographs were then transferred to Adobe Photoshop CS image editor software (Adobe Systems Incorporated, San Jose,

Disclosure. This research project was supported by a grant from the Research Center of the Center for Female Scientific and Medical Colleges, Deanship of Scientific Research, King Saud University, Riyadh, Kingdom of Saudi Arabia.

California, USA). The nose and chin, as well as most of the cheeks were removed from the images to reduce the number of confounders.²⁰ For the same reason, the cropped images were converted to black and white.²⁰ All images were adjusted to a standardized image size for each view type (Figure 1). The lateral cephalometric radiograph of each patient was used for the purpose of categorizing the subjects into the 2 groups, and to correlate specific dentoalveolar measurements with evaluators' ratings. Radiographs were analyzed using the computer software Dolphin® Imaging 11.0 premium (Dolphin Imaging and Management Solutions, Chatsworth, California, USA) by the same investigator. The cephalometric analysis was based on 7 dentoalveolar measurements (Figure 2). The evaluators for this study were organized into 3 panels (orthodontists, general dentists, and laypersons). Each panel consisted of 50 participants (25 males and 25 females). Each evaluator was approached individually, and requested to rate the attractiveness of each photo on a scale from 0 (very unattractive) to 100 (very attractive) using a visual analog scale (VAS) while viewing a Microsoft PowerPoint (Microsoft Corporation, Redmond, WA, USA) presentation of the patients' photos in random orders. Each photo was in a single slide, and was viewed for 15 seconds. The evaluators were unable to reevaluate the previously seen photographs.

Statistical analysis and measurement error. Data analysis was carried out using the Statistical Package for Social Sciences version 19 (IBM Corp., Armonk, NY, USA). A comparison between the patient groups for cephalometric measurements was performed using Mann-Whitney U test. A student's t-test was used to compare between esthetic ratings according to patient

groups, and according to smile view types. Comparisons of esthetic ratings between evaluator panels were performed using one-way analysis of variance (ANOVA), followed by post hoc Bonferroni tests for multiple comparisons. A Pearson correlation test was used to quantify the relationship between cephalometric

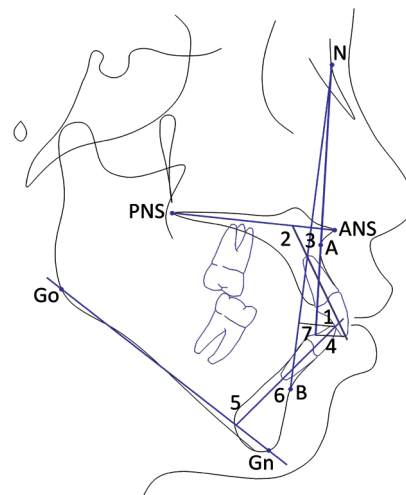


Figure 2 - The dentoalveolar measurements used for the cephalometric analysis: 1) U1-L1 ($^{\circ}$): the angle between the long axis of upper incisors and the long axis of lower incisors; 2) U1-PP ($^{\circ}$): the angle between the long axis of upper incisors and anterior nasal spine-posterior nasal spine (ANS-PNS) line; 3) U1-NA ($^{\circ}$): the angle between the long axis of upper incisors and Nasion-point A line; 4) U1-NA (mm): the perpendicular distance between the tip of the upper incisor and Nasion-point A line; 5) L1-GoGn ($^{\circ}$): the angle between the long axis of lower incisors and Gonion-Gnathion line; 6) L1-NB ($^{\circ}$): the angle between the long axis of lower incisors and Nasion-point B line; and 7) L1-NB (mm): the perpendicular distance between the tip of the lower incisor and Nasion-point B line.

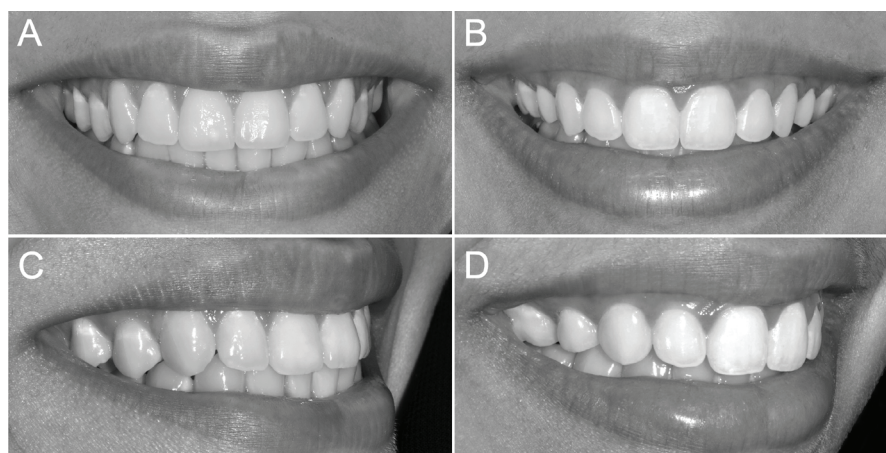


Figure 1 - A photograph showing: sample frontal (A), and three-quarter (C) close-up smile of a bimaxillary protrusive patient; and frontal (B) and three-quarter (D) photographs of a treated patient.

measurements and esthetic ratings, and between smile view types for esthetic ratings. Comparisons between panels' correlations of view types were performed using Fisher's z-statistics. The minimum level of significance for all statistical tests was set at $p < 0.05$.

The reliability of VAS method for the assessment of smile esthetics and the intra-examiner reliability of the cephalometric analysis was tested using intraclass correlation coefficients (ICCs). Twenty evaluators (7 orthodontists, 6 general dentists, and 7 laypersons) were selected to rate the entire photos again after a 2-week interval. The lateral cephalometric radiographs for the 14 patients were traced and measured twice over a period of 2 weeks by the same investigator. Correlations for repeated measurements demonstrated excellent reliabilities ($p < 0.01$).

Results. Comparison between patient groups.

Comparisons of the cephalometric measurements showed significant differences in all of the dentoalveolar variables between the 2 patient groups ($p < 0.01$). Also, the bimaxillary protrusion group (mean combined rating: 49.37 ± 18.56) was always rated significantly less attractive than the treatment group (72.12 ± 13.77) as perceived by each evaluator panel ($p < 0.01$). For each view type, the mean esthetic ratings of the bimaxillary protrusion group was always significantly lower than those of the treatment group ($p < 0.001$).

Evaluator panels' perceptions. Table 1 shows the comparisons of the esthetic ratings between the 3 evaluator panels. The laypersons gave significantly the lowest esthetic ratings for both patient groups. When rating the bimaxillary protrusion group, there were statistically significant differences between laypersons and orthodontists ($p < 0.01$) and between laypersons and general dentists ($p < 0.01$). In the rating of the treatment group, there were statistically significant differences between laypersons and orthodontists ($p < 0.01$), between laypersons and general dentists ($p < 0.01$), and between orthodontists and general dentists ($p < 0.01$).

Association of esthetic perceptions between smile views. When rating the bimaxillary protrusion group, the three-quarter view had a significantly lower mean esthetic rating than the frontal view ($p < 0.05$). However, the three-quarter view had a higher mean esthetic rating than the frontal view when rating the treatment group ($p < 0.01$) (Figure 3). Across each patient group, the esthetic ratings given by a panel to the frontal views were correlated with the esthetic ratings given by that panel to the three-quarter views. These correlations were low-to-moderate and significant (Table 2). To evaluate whether the orthodontist panel would have higher correlations

of frontal to three-quarter ratings than the other panels, Fisher's z-statistics were computed and applied. Across the bimaxillary protrusive patients, no panel had a significantly higher correlation of frontal to three-quarter ratings than any other panel. However, across the treated patients, a significant difference between the orthodontists' and general dentists' correlations of frontal to three-quarter ratings was detected. No other significant differences between other correlations were found (Table 2).

Correlation of specific cephalometric measurements with smile esthetics. Table 3 lists the correlations of 7 dentoalveolar measurements with the combined panels' ratings. While the interincisal angle showed positive correlations, all the remaining dentoalveolar measurements showed negative correlations. The

Table 1 - Comparison among evaluator panels' ratings of each patient group and their corresponding evaluator panel.

Groups	Mean ± standard deviation	P-value
<i>Bimaxillary protrusion</i>		
Orthodontists	51.70 ± 18.76	<0.001*
General dentists	52.55 ± 17.28	
Laypersons	43.85 ± 18.39	
<i>Treatment</i>		
Orthodontists	73.04 ± 13.00	<0.001*
General dentists	75.31 ± 11.66	
Laypersons	68.00 ± 14.48	

*Significant at the 0.001 level

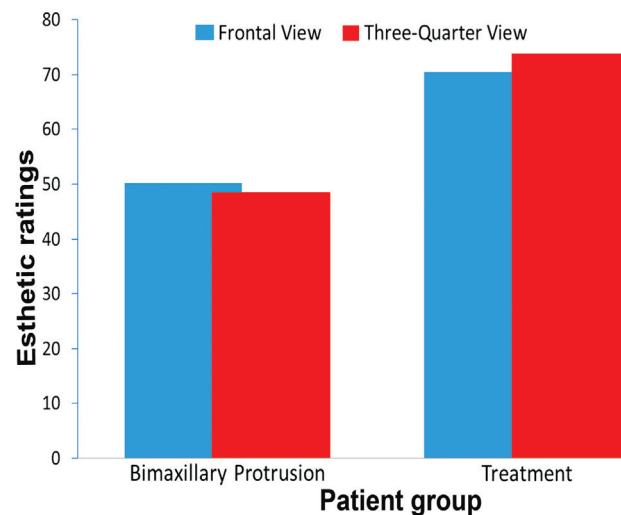


Figure 3 - A comparison between the 2 view types for each patient group.

Table 2 - Correlation between the panel's ratings of frontal views and that panel's ratings of three-quarter views across the bimaxillary protrusion and treatment groups.

Panels	Bimaxillary protrusion group			Treatment Group		
	Pearson correlation coefficient	Fisher's z-statistics*	P-value	Pearson correlation coefficient	Fisher's z-statistics*	P-value
Orthodontists	0.509 [†]			0.523 [†]		
General dentists	0.414 [†]	1.59	0.112	0.305 [†]	3.5	0.001 [‡]
Laypersons	0.394 [†]	1.91	0.056 [§]	0.487 [†]	0.64	0.522 [§]
All evaluators	0.461 [†]			0.476 [†]		

*value applied to assess the significance of the difference between the correlation coefficients of orthodontists and other panels, [†]significant at the 0.01 level, [‡]significant at the 0.001 level, [§]not significant

Table 3 - Pearson correlation coefficients between the combined panels' ratings and patients' cephalometric measurements.

Measurement	Correlation coefficient (for frontal views)	Correlation coefficient (for ¾ views)	Correlation coefficient (for combined views)
U1-L1 (°)	0.693 [†]	0.822 [†]	0.787 [†]
U1-PP (°)	-0.787 [†]	-0.917 [†]	-0.885 [†]
U1-NA (°)	-0.691 [†]	-0.872 [†]	-0.814 [†]
U1-NA (mm)	-0.547 [*]	-0.782 [†]	-0.694 [†]
L1-GoGn (°)	-0.442 ^{NS}	-0.659 [*]	-0.576 [*]
L1-NB (°)	-0.575 [*]	-0.679 [†]	-0.651 [†]
L1-NB (mm)	-0.536 [*]	-0.591 [*]	-0.585 [*]

*significant at 0.05 level, [†]significant at 0.01 level, NS - not significant. U1-L1 (°) - the angle between the long axis of upper incisors and the long axis of lower incisors, U1-PP (°): the angle between the long axis of upper incisors and anterior nasal spine (ANS)-posterior nasal spine (PNS) line, U1-NA (°): the angle between the long axis of upper incisors and Nasion-point A line, U1-NA (mm): the perpendicular distance between the tip of the upper incisor and Nasion-point A line, L1-GoGn (°): the angle between the long axis of lower incisors and Gonion-Gnathion line, L1-NB (°): the angle between the long axis of lower incisors and Nasion-point B line, L1-NB (mm): the perpendicular distance between the tip of the lower incisor and Nasion-point B line

correlations with the upper incisor inclination and the interincisal angle were high, whereas the correlations with the upper incisor position were moderate-to-high. The lower incisor inclination and position showed moderate correlations. All correlations were significant except with lower incisor inclination to Gonion-Gnathion line in the frontal views.

Discussion. The primary objective of this cross-sectional study was to evaluate the influence of bimaxillary protrusion on the perception of smile esthetics. The evaluators gave the bimaxillary protrusion group significantly lower esthetic ratings than the treatment group in each view type, which suggests that the bimaxillary protrusion makes smiles less attractive, and can be detected not only in the three-quarter view but also in the frontal view. Furthermore, the bimaxillary protrusion group was perceived significantly less attractive than the treatment group by each panel. This general agreement between dental professionals and laypeople regarding the disfavor of bimaxillary

protrusion indicates the understanding of the clinicians of what is considered unattractive by the society.

Previous studies found that individuals of African descent prefer a straighter profile, and they would undergo an extraction orthodontic treatment to change their bimaxillary protrusive profile.^{2,4,5} Although these previous investigations were based on profile views, their findings can be considered to be in agreement with the results of this study.

In the present study, the laypersons were less tolerant of bimaxillary protrusion than the orthodontists and general dentists, and this can suggest that the general public is more critical about the esthetics of the smile. The laypersons' perceptions might be derived from the advertised "Hollywood" smile in the media.²¹ Peck and Peck²² reported that the layman's perception of esthetics is purely driven by external observations, and that the mass media is influential in unifying the general public's perceptions of beauty. Orthodontists' perceptions of smiles, on the contrary, might be driven by previous experience, that is, what a reasonable orthodontic result

is.²¹ If the orthodontist's perception of esthetics is not harmonious with the patient's perception, then the result might not be acceptable to the patient, even if the patient's function is improved.²³ These findings point to the need for a thorough discussion with the patient to identify his or her esthetic preference regarding the face, smile, and dental arrangement before determining a treatment plan.

It is not surprising that the three-quarter views were rated significantly as more unattractive than the frontal views in the bimaxillary protrusion group, and that could be due to the fact that the protrusion becomes more apparent when seen in the three-quarter view. However, contrary to the expected; the frontal and three-quarter views of the treatment group did not receive similar ratings of smile esthetics. The three-quarter views were rated significantly higher than the frontal views. This implies that the treatment effect - by improving incisor inclination and position - will be more appreciated when the patient's smile is seen from the oblique side. Kerns et al²⁴ found that the profile views were given higher esthetic ratings than the frontal views of the smiles of the same orthodontically treated patients. Our findings suggest that evaluating routinely the smiling three-quarter view and presenting this view to the patient may help the clinician in deciding the appropriate treatment approach, especially in borderline cases with bimaxillary protrusion.

Across each patient group, the correlations between the frontal and the three-quarter ratings were low-to-moderate. Kerns et al²⁴ revealed that the prediction of similar ratings for the frontal and profile views of the same smile was weak. With regards to panel differences in the similarity of the frontal and three-quarter ratings, the orthodontists did not have a higher degree of association between their esthetic ratings of frontal and three-quarter views of the same smiles than did the laypeople. Kerns et al²⁴ found that the orthodontists had no higher correlations between frontal and profile views of the smiles of the same orthodontically treated patients than did the laypeople.

In the current study, 3 (U1-L1, U1-PP, and U1-NA) of the 7 dentoalveolar measurements were always significantly correlated with the esthetic ratings. The correlation with the U1-PP angle showed a pattern to have the highest absolute value among them. These findings clearly indicate that the patient selection and the inclusion criteria helped to reduce, to a large degree, the confounding factors that may have distracted the evaluators. In addition, the findings suggest that increasing the upper incisor inclination tends to cause smile esthetics to deteriorate. This is in agreement with

Isiksal et al²⁵ who found significant negative correlation between the U1-SN angle and the esthetic score of smile.

Oh et al²⁶ studied the correlations between cephalometric measures and rankings of facial attractiveness, and found that the correlations with the L1-MP angle were not significant. This agrees with our findings that the correlations between L1-GoGn angle and the esthetic ratings in the frontal views of the smiles were not significant. The absolute values of the correlations in the three-quarter views had a tendency to be higher than those in the frontal views. In addition, all the 7 dentoalveolar measurements were always significantly correlated with the esthetic ratings in the three-quarter views. This means that the impact of the inclination of the upper and lower incisors on the smile esthetics is more apparent when the patient's smile is seen from the oblique aspect.

The statistically significant relationships described in the previous paragraphs can be clinically relevant for borderline cases with bimaxillary protrusion, and would encourage leaning towards a decision to treat them with the extractions of premolars. Non-extraction treatment modality may maintain the protrusion, or could result in further flaring of the upper and lower incisors, which can influence the smile esthetics negatively. However, each subject has a unique set of malocclusal problems, and the entire hard and soft tissue structures must be carefully evaluated in all dimensions. Inadequate application of the extraction treatment plan with some patients can lead to deteriorating effects on the soft tissue, which can contribute to the aging of the face. Individualism, instead of direct application of scientific findings, provides more favorable results for both the patient and the doctor.

In conclusion, the findings of this cross-sectional study can be summarized as follows: there was a general concordance between the dental professionals and the laypeople in their disfavor of bimaxillary protrusion compared with 4 premolar extraction treatment, and an increased interincisal angle. However, laypeople were less receptive to bimaxillary protrusion than dental professionals; frontal and three-quarter views of the same smiles did not necessarily receive similar esthetic ratings. Evaluators were more critical of the three-quarter views, and this study found that the dentoalveolar measurements: U1-L1, U1-PP, and U1-NA angles were always significantly correlated with the smile esthetics ratings. Increasing the upper incisor inclination, as well as decreasing the interincisal angle tends to compound the bimaxillary effect and make the smile less attractive.

References

1. Bills DA, Handelman CS, BeGole EA. Bimaxillary dentoalveolar protrusion: traits and orthodontic correction. *Angle Orthod* 2005; 75: 333-339.
2. Farrow AL, Zarrinnia K, Azizi K. Bimaxillary protrusion in black Americans--an esthetic evaluation and the treatment considerations. *Am J Orthod Dentofacial Orthop* 1993; 104: 240-250.
3. Langberg BJ, Todd A. Treatment of a Class I malocclusion with severe bimaxillary protrusion. *Am J Orthod Dentofacial Orthop* 2004; 126: 739-746.
4. Marques LS, Chaves KC, Ramos-Jorge ML, Pereira LJ. Extraction of four premolars in Black patients with bi-protrusion: aesthetic perceptions of professionals and lay people. *J Orthod* 2011; 38: 107-112.
5. Dawjee SM, Becker PJ, Hlongwa P. Is orthodontics an option in the management of bimaxillary protrusion? *SADJ* 2010; 65: 404-408.
6. Flores-Mir C, Silva E, Barriga MI, Lagravere MO, Major PW. Lay person's perception of smile aesthetics in dental and facial views. *J Orthod* 2004; 31: 204-209.
7. DeLoach N. Soft tissue facial profile of North American blacks: A self-assessment. *American Journal of Orthodontics* 1978; 74: 685.
8. Kokich VO Jr, Kiyak HA, Shapiro PA. Comparing the perception of dentists and lay people to altered dental esthetics. *J Esthet Dent* 1999; 11: 311-324.
9. Thomas JL, Hayes C, Zawaideh S. The effect of axial midline angulation on dental esthetics. *Angle Orthod* 2003; 73: 359-364.
10. Roden-Johnson D, Gallerano R, English J. The effects of buccal corridor spaces and arch form on smile esthetics. *Am J Orthod Dentofacial Orthop* 2005; 127: 343-350.
11. Shaw WC, Lewis HG, Robertson NR. Perception of malocclusion. *Br Dent J* 1975; 138: 211-216.
12. Prahl-Andersen B, Boersma H, van der Linden FP, Moore AW. Perceptions of dentofacial morphology by laypersons, general dentists, and orthodontists. *J Am Dent Assoc* 1979; 98: 209-212.
13. Abu Alhajja ES, Al-Shamsi NO, Al-Khateeb S. Perceptions of Jordanian laypersons and dental professionals to altered smile aesthetics. *Eur J Orthod* 2011; 33: 450-456.
14. Zange SE, Ramos AL, Cuoghi OA, de Mendonça MR, Suguino R. Perceptions of laypersons and orthodontists regarding the buccal corridor in long- and short-face individuals. *Angle Orthod* 2011; 81: 86-90.
15. Tedesco LA, Albino JE, Cunat JJ, Green LJ, Lewis EA, Slakter MJ. A dental-facial attractiveness scale. Part I. Reliability and validity. *Am J Orthod* 1983; 83: 38-43.
16. Phillips C, Tulloch C, Dann C. Rating of facial attractiveness. *Community Dent Oral Epidemiol* 1992; 20: 214-220.
17. Arnett GW, McLaughlin RP. Facial and dental planning for orthodontists and oral surgeons. St. Louis (MO): Mosby; 2004.
18. Maulik C, Nanda R. Dynamic smile analysis in young adults. *Am J Orthod Dentofacial Orthop* 2007; 132: 307-315.
19. Aldrees AM, Shamlan MA. Morphological features of bimaxillary protrusion in Saudis. *Saudi Med J* 2010; 31: 512-519.
20. Janson G, Branco NC, Fernandes TM, Sathler R, Garib D, Lauris JR. Influence of orthodontic treatment, midline position, buccal corridor and smile arc on smile attractiveness. *Angle Orthod* 2011; 81: 153-161.
21. Schabel BJ, McNamara JA Jr, Franchi L, Baccetti T. Q-sort assessment vs visual analog scale in the evaluation of smile esthetics. *Am J Orthod Dentofacial Orthop* 2009; 135 (4 Suppl): S61-S71.
22. Peck H, Peck S. A concept of facial esthetics. *Angle Orthod* 1970; 40: 284-318.
23. Brisman AS. Esthetics: a comparison of dentists' and patients' concepts. *J Am Dent Assoc* 1980; 100: 345-352.
24. Kerns LL, Silveira AM, Kerns DG, Regennitter FJ. Esthetic preference of the frontal and profile views of the same smile. *J Esthet Dent* 1997; 9: 76-85.
25. İşiksal E, Hazar S, Akyalçin S. Smile esthetics: perception and comparison of treated and untreated smiles. *Am J Orthod Dentofacial Orthop* 2006; 129: 8-16.
26. Oh HS, Korn EL, Zhang X, Liu Y, Xu T, Boyd R, et al. Correlations between cephalometric and photographic measurements of facial attractiveness in Chinese and US patients after orthodontic treatment. *Am J Orthod Dentofacial Orthop* 2009; 136: 762. 1-14.

Related Articles

Hassan AH, Turkistani AA, Hassan MH. Skeletal and dental characteristics of subjects with incompetent lips. *Saudi Med J* 2014; 35: 849-854.

Aldrees AM. Pattern of skeletal and dental malocclusions in Saudi orthodontic patients. *Saudi Med J* 2012; 33: 315-320.

Aldrees AM, Shamlan MA. Morphological features of bimaxillary protrusion in Saudis. *Saudi Med J* 2010; 31: 512-519.