

# A very rare type of primary hyperparathyroidism with severe hypercalcemia in an infant

Mohammad H. Al-Qahtani, MD.

### ABSTRACT

داء الفرط الأولي الشديد لهرمون الغدة جار الدرقية لدى حديثي الولادة يعتبر من الأسباب النادرة جداً لفرط الغدة جار الدرقية عموماً لدى الأطفال والذي قد يُكتشف مبكراً أو في مراحل متقدمة من عمر الطفل. تكون أعراض هذا المرض غير محددة وغير مختصة بالغدة. نستعرض في هذا التقرير حالة طفلة عانت من ارتفاع شديد جداً في مستوى الكالسيوم بالدم، وبالرغم من ذلك فإن الطفلة قد استجابت للأدوية المتوفرة لعلاج الارتفاع الشديد لكالسيوم الدم. وقد كان الهدف من هذا التقرير هو لفت انتباه أطباء الأطفال إلى مثل هذا المرض الذي يمكن لتشخيصه وعلاجه المبكر أن يقللان من الآثار الجانبية.

Severe neonatal primary hyperparathyroidism is a very rare type of primary hyperparathyroidism in pediatrics that might present during infancy with non-specific symptoms. We report an infant who presented with a very high level of calcium, yet responding to simple medications to draw the attention to pediatricians to this disease as early diagnosis and treatment will ameliorate its devastating outcome.

*Saudi Med J 2012; Vol. 33 (12): 1340-1342*

*From the Department of Pediatrics, King Fahd Hospital of the University, University of Dammam, Al-Khobar, Kingdom of Saudi Arabia.*

*Received 26th June 2012. Accepted 28th August 2012.*

*Address correspondence and reprint request to: Dr. Mohammad H. Al-Qahtani, Consultant Pediatric Endocrinologist, Department of Pediatrics, King Fahd Hospital of the University, University of Dammam, PO Box 2208, Al-Khobar 31952, Kingdom of Saudi Arabia. Tel. +966 (8) 966666 Ext 1213. Fax. +966 (8) 966709. E-mail: drmhqahatani@yahoo.com*

Primary hyperparathyroidism (PHPT) is a rare cause of hypercalcemia in pediatric age group (incidence of 2-5 in 100,000) compared to adults, where it is considered the most common cause of hypercalcemia (incidence of 1 in 1000).<sup>1,2</sup> The severe neonatal primary hyperparathyroidism (SNHPT) is a very rare type

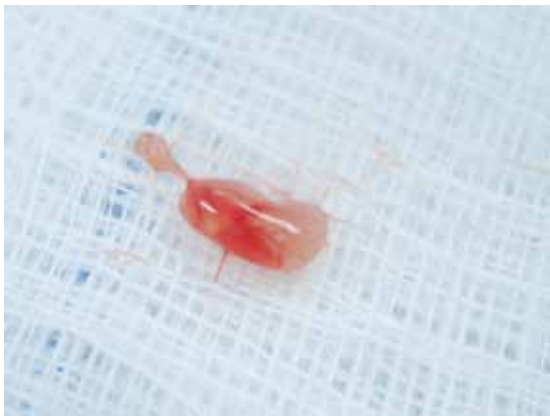
of PHPT (one per 200-300,000 live births),<sup>3</sup> that may present at neonatal period, or at infancy. Early establishment of the diagnosis of PHPT is difficult in children, and often delayed because of being rare, and has nonspecific presenting symptoms, the most frequent one in neonates and infants is hypotonia.<sup>3</sup> While children present with fatigue, weakness, and weight loss.<sup>1,4</sup> Untreated hyperparathyroidism may cause damage to the eyes, kidneys, and skeletal system.<sup>4</sup> We report a female infant who presented with severe hypotonia, and found to have severe hypercalcemia due to PHPT, rapidly responding to simple medical treatment, and resolution of symptoms after parathyroidectomy, to draw the attention to pediatricians to this disease, as early diagnosis and treatment will ameliorate its devastating outcome.

**Case Report.** A 9-month-old female infant presented to the Emergency Department at King Fahd Hospital of the University, Al-Khobar, Kingdom of Saudi Arabia with 2 days history of high grade fever, mild upper respiratory tract infection symptoms, and 2 brief attacks of up-rolling eye movement with no loss of consciousness, and nor post ictal state. She had uneventful perinatal history, noticed at age of 4 months to have isolated progressive head lag, and delayed milestones with 2 months history of polyuria and polydipsia. She is the only child of healthy second-degree cousins.

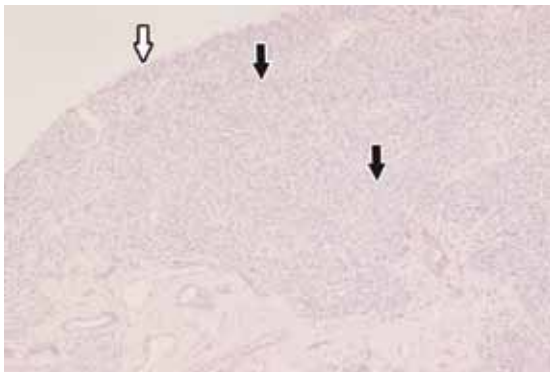
Physical examination showed alert febrile infant, moderately dehydrated with normal blood pressure, microcephaly with no dysmorphic features, no skeletal deformity, and no neurocutaneous stigmata, neurological assessment revealed axial hypotonia, severe head lag, and mild limb hypotonia with briskly symmetrical

**Disclosure.** The author has no conflict of interests, and the work was not supported or funded by any drug company.

deep tendon reflexes. Ophthalmological assessment showed no band keratopathy. Echocardiography showed normal anatomy and function. Investigations revealed a very high total calcium (Ca) level of 36 mg/dl (normal value: 8.7-10.5 mg/dL) after dilution by distilled water using Dimension® RxL Max® New York, USA. Low phosphorus 2.2 mg/dl and high parathyroid hormone (PTH) 46.1 pmol/L (normal value: 1.3-6.8 pmol/L) was also noted. However, she had normal levels of magnesium (4.3 mg/dl), and alkaline phosphatase (184 U/L). Liver functions, lipase and 25-hydroxy vitamin D were normal. The Ca/Cr ratio in urine was normal excluding hypercalcuric hypercalcemia. Toxicology and metabolic screening was unremarkable, and ultrasonography (US) showed no nephrolithiasis or nephrocalcinosis. Skeletal survey was within normal. The parents were tested for bone profile



**Figure 1** - A resected gross enlarged parathyroid gland with an actual size of 0.5x0.5x0.3 cm.



**Figure 2** - Microscopic section of one of the resected parathyroid samples showing no capsular compression (white arrow), diffused homogenous hyperplasia or hyper cellularity (black arrows) suggestive of severe neonatal hyperparathyroidism (H&E x40).

and showed no evidence of biochemical asymptomatic hyperparathyroidism. Immediate intravenous medical treatment was initiated with normal saline (NS) boluses and furosemide followed by 1.5x maintenance of NS. Over the following 6 days hydrocortisone (1 mg/kg) and equivalent doses of dexamethasone were used until normalization of serum calcium was achieved. Localization of the parathyroid glands carried out by neck US, neck CT, Technetium (99 mTc) sestamibi scanning showed no evidence of adenoma, hence patient processed to surgical intervention, and found all the 4 glands enlarged, the largest was 0.5x0.5x0.3 cm (Figure 1). Frozen sections obtained and histopathological study of the samples showed diffuse hyperplasia of all the glands (Figure 2) confirming the diagnosis of severe neonatal hyperparathyroidism (SNHPT), and parathyroidectomy of all the glands was performed and the intraoperative PTH level was 0.75 pmol/L and Ca was 10.1 mg/dl. The fragment of one of the glands was implanted in the left strap muscle of the neck, without surgical complication. She was discharged on calcium and 1  $\alpha$  calcidiol for 2 weeks only. Her 2-years regular follow up without treatment showed dramatic resolution of the head lag, and improved developmental mile stones and normal head circumference. Her latest laboratory results were; Ca - 9.0 mg/dL; and PTH = 0.6 pmol/L.

**Discussion.** Primary hyperparathyroidism (PHPT) in pediatrics might lead to serious complications if not detected early. Most of the reported cases were diagnosed late for months, or even years with end-organ involvement,<sup>2,4</sup> and most patients were adolescents. It has been estimated that 80% of PHPT cases are asymptomatic. Familial forms represent approximately 5% of the cases,<sup>5</sup> and in our case, the possibility of familial type was ruled out by having normal parents' bone profile.

Severe neonatal hyperparathyroidism (OMIM #239200) is a rare, potentially lethal disease<sup>6,7</sup> caused by homozygous loss of function mutation in the calcium sensing receptor (CaSR) gene leading to unsuppressed high production of PTH, causing generalized diffuse hyperplasia involving all the glands and very severe hyperparathyroid bone disease and marked hypercalcemia, manifesting before the age of 6 months. Our patient surprisingly did not have any skeletal defects in spite of high persisting PTH level. Our patient presented at age of 9 months with seizure like picture and symptoms of central hypotonia, as well as polydipsia, and polyuria. Presenting with seizure was not reported as a manifestation of SNHPT.

Few cases in the literature had significant hypercalcemia, the highest was 32.4 mg/dl.<sup>6</sup> Our patient had Ca level of 36 mg/dl, which is unusually high. Contrary to other studies with high percentage of significant secondary bone disease in 27-64%<sup>8</sup> and nephrolithiasis in 36-64%,<sup>4</sup> our patient did not have any bone deformities, and no renal stones detected. The combination of preoperative scanning and intraoperative PTH assays to exclude the presence of adenomas had shown to be effective diagnostic tools,<sup>3,4</sup> and helped us in our patient assessment. Effective management of PHPT in children is limited to the routine use of bisphosphonates such as Pamidronate as management modality of hypercalcemia in children.<sup>6</sup> It is currently being used preoperatively in severe or symptomatic hypercalcemia, or when diuretic therapy has failed.<sup>6,9</sup> Since Pamidronate was not available in our hospital, we followed the simple measures like the normal saline hydration and diuretics, in addition to minimal use of the steroids in the form of hydrocortisone and dexamethasone, which showed rapid response to decrease the calcium to a safe level over few days for preoperative preparation.

The surgical resection has been the treatment of choice for almost all the cases of primary hyperparathyroidism regardless of the etiologies with a success rate of 95%,<sup>4</sup> in our case the procedure was uncomplicated with the successful implantation of the gland fragment in the strips of the neck muscle, manifested by off-medications eucalcemia over 2 years, and resolution of the hypotonia and regain of developmental milestones.

The aim of reporting this case is to draw the attention of pediatricians to think of PHPT as an important cause of severe hypercalcemia that might present with nonspecific symptoms in infants. Early diagnosis of such condition and prompt simple medical treatment and further surgical intervention will lead to better response in most cases, as seen in our patient, as well as preventing irreversible complications.

**Acknowledgment.** The author gratefully acknowledges Dr. Tarek Sharkawi, Associate Professor, Department of Histopathology for providing the histology picture and its legend.

## References

1. Kollars J, Zarroug A, Heerden J, Lteif A, Stavlo P, Suarez L, et al. Primary Hyperparathyroidism in Pediatric Patients. *Paediatrics* 2005; 115: 974-980.
2. Chesney RW. Primary hyperparathyroidism in pediatric patients: clear cut differences from adult patients. *Pediatrics* 2005; 115: 1073.
3. Mallet E, Working Group on Calcium Metabolism. Primary hyperparathyroidism in neonates and childhood. The French experience (1984-2004). *Horm Res* 2008; 69: 180-188.
4. Libánský P, Astl J, Adámek S, Nanka O, Pařko P, Spacková J, et al. Surgical treatment of primary hyperparathyroidism in children: Report of 10 cases. *Int J Pediatr Otorhinolaryngol* 2008; 72: 1177-1182.
5. Toke J, Patócs A, Balogh K, Gergics P, Stenczer B, Rácz K, et al. Parathyroid hormone-dependent hypercalcemia. *Wien Klin Wochenschr* 2009; 121: 236-245.
6. Waller S, Kurzwinski T, Spitz L, Thakker R, Cranston T, Pearce S, et al. Neonatal hyperparathyroidism: genotype/phenotype correlation and the use of pamidronate as rescue therapy. *Euro J Pediatr* 2004; 163: 589-594.
7. Töke J, Czirájk G, Patócs A, Enyedi B, Gergics P, Csákváry V, et al. Neonatal severe hyperparathyroidism associated with a novel de novo heterozygous R551K inactivating mutation and a heterozygous A986S polymorphism of the calcium-sensing receptor gene. *Clin Endocrinol (Oxf)* 2007; 67: 385-392.
8. Gabbett M, Jones K, Cowell C, Sillence D, Wilson M. Neonatal severe hyperparathyroidism: An important clue to the aetiology. *J Paediatr Child Health* 2006; 42: 813-816.
9. Obermannova B, Banghova K, Sumník Z, Dvorakova H, Betka J, Fencel E, et al. Unusually severe phenotype of neonatal primary hyperparathyroidism due to heterozygous inactivating mutation in the CASR gene. *Euro J Pediatr* 2009; 168: 569-573.

## Related Articles

Bakathir AA, Margasahayam MV, Al-Ismaily MI. Maxillary hyperplasia and hyperostosis cranialis: a rare manifestation of renal osteodystrophy in a patient with hyperparathyroidism secondary to chronic renal failure. *Saudi Med J* 2008; 29: 1815-1818.

Aygenel G, Keles A, Demircan A. Death due to primary hyperparathyroidism. *Saudi Med J* 2007; 28: 971.

Haddad FH, Malkawi OM, Sharbaji AA, Jbara IF, Rihani HR. Primary hyperparathyroidism. A rare cause of spinal cord compression. *Saudi Med J* 2007; 28: 783-786.