

# Recovery from severe novel coronavirus infection

Ali M. AlBarrak, MD, Gwen M. Stephens, MD, MSc, Roger Hewson, PhD, Ziad A. Memish, MD.

## ABSTRACT

نستعرض في هذا المقال الحالة الثالثة من نوعها المكتشفة لفيروس الكورونا النادر الحدوث لمواطن من الجزيرة العربية. عانى المريض كما في الحالتين السابقتين من أعراض الالتهاب الرئوي الحاد، وحضر إلى المستشفى حيث استلزمت حالته دخوله إلى العناية المركزة لتزويده بالتنفس الاصطناعي، ودعم الوظائف الكلوية. وخلافاً للحالتين السابقتين، وبالرغم من إصابته بمرض مزمن، ولديه كلية واحدة عاملة، فقد شفي المريض وخرج من المستشفى بصحة جيدة. تواصلت وزارة الصحة بالمملكة العربية السعودية مراقبتها المكثفة لمزيد من الحالات وفحص العينات، وخلال إعداد هذا المقال ونشره تم التعرف وإثبات إصابة حالتين جديدتين. يجري البحث حالياً للتقصي الوبائي حول انتقال الفيروس بين المخالطين. في المستقبل لن يتركز العمل على التعرف على مصدر الفيروس وطريقة انتقاله فحسب بل سيبحث أيضاً في عوامل المضيف التي من شأنها التأثير على أسباب الإصابة بالمرض والتنبؤ بتطوره.

We describe the third confirmed case of novel coronavirus infection in a resident of the Arabian Peninsula. Our patient presented, as did 2 prior cases, with severe pneumonia and renal dysfunction requiring intensive care support including assisted ventilation. However, unlike the earlier cases, and despite underlying chronic disease and a single kidney, he survived his infection and has been discharged home. The Ministry of Health continues active surveillance for additional cases. As this case report goes to press, 2 additional confirmed cases have been identified in Riyadh, Saudi Arabia. Contact investigations are in progress. Future work will focus not only on the origin of the virus and mechanisms of transmission, but also the host factors that influence pathogenesis and prognosis.

*Saudi Med J 2012; Vol. 33 (12): 1265-1269*

*From the Department of Internal Medicine (AlBarrak), Infectious Disease Division, Prince Sultan Military Medical City, the Public Health Directorate (Stephens, Memish), Ministry of Health, Riyadh, Kingdom of Saudi Arabia, and the Health Protection Agency (Hewson), Porton Down, Salisbury, United Kingdom.*

*Address correspondence and reprint request to: Dr. Ziad A. Memish, Ministry of Health, Riyadh 11176, Kingdom of Saudi Arabia. Tel. +966 (1) 2124052. Fax. +966 (1) 2125052. E-mail: zmemish@yahoo.com*

On 4 November 2012, the International Health Regulations National Focal Point of the Kingdom of Saudi Arabia (KSA) notified the World Health Organization of a laboratory confirmed case of novel coronavirus (nCoV) respiratory infection in a 45-year-old man hospitalized in Riyadh, KSA. The diagnosis was based on his clinical presentation with severe pneumonia, plus successful and independent detection of nCoV RNA in respiratory secretions by 2 facilities; one in Saudi Arabia, the Ministry of Health's Regional Laboratory located in Jeddah, KSA, and the second Health Protection Agency's (HPA) West Midlands Public Health Laboratory, Birmingham, United Kingdom (UK). Investigations to date have not shown person-to-person transmission within the patient's household, nor among exposed healthcare workers, to the extent that known contacts identified so far remain asymptomatic. Our patient becomes the third confirmed case of severe pneumonia linked to nCoV reported by health authorities since September 20.<sup>1,2</sup> He shares with both prior cases a lifelong residence in the Arabian Peninsula, and a similar clinical presentation of a rapidly progressive pneumonia requiring ventilator support. He also required hemodialysis during his intensive care unit (ICU) stay, however, the role his infection played in the development of temporary renal compromise is confounded by pre-existing kidney disease. Twenty-two days after admission, he was discharged home from the hospital.

**Case Report.** A 45-year-old gym teacher, and a heavy smoker with a medical history of type 2 diabetes mellitus controlled on oral medication, and a history

**Disclosure.** The authors have no conflict of interests, and the work was not supported or funded by any drug company. Dr. AlBarrak is a member of the Editorial Team, and was therefore excluded from any final editorial decisions regarding this paper. This paper underwent expedited publication due to its international importance and urgent clinical significance regarding new emerging infection.

of atrophied right kidney apparently since childhood, cause unknown. He also has a history of ischemic heart disease; he underwent percutaneous coronary intervention in July 2011 with successful placement of a stent, and an uneventful recovery. Three days prior to the onset of illness, he had visited a local farm near his home in Riyadh where he had a brief contact with farm animals. His only other environmental exposure was an evening spent in a garden one day before the respiratory symptoms developed. He had no travel history outside Riyadh, but had been in contact with one of his children who had a mild cold.

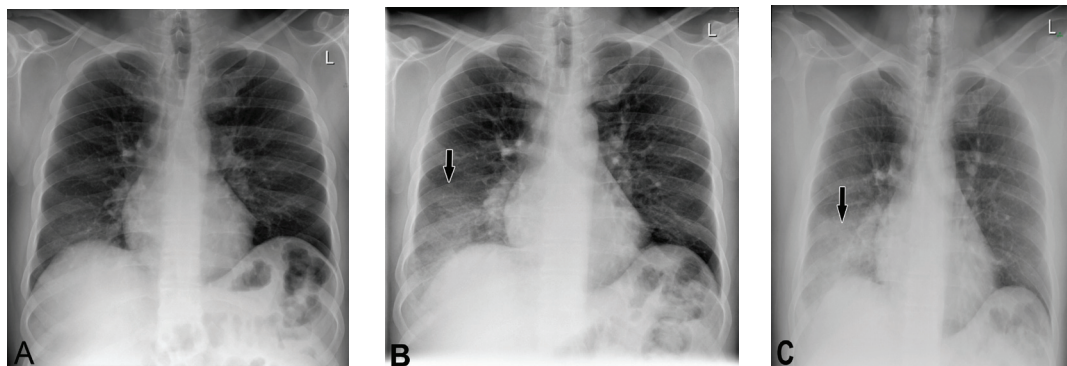
He was in his usual state of health until October 9, when he presented to a local private clinic for the first time with a complaint of fever of 38°C and a cough that had become productive. A chest film was unremarkable, and was discharged home. On October 10, he visited the hospital's emergency room with the same complaints; however, his oxygen saturation on room air and chest film was normal (**Figure 1A**); other vital signs were stable. He was again discharged home, this time on oral cefuroxime. Two days later, he returned to the emergency room with worsening dyspnea and required continuous positive airway pressure (CPAP) to maintain oxygenation. Chest film revealed patchy infiltrates in his right lower lobe (**Figure 1B**). Treatment with parenteral antibiotics (ceftriaxone and azithromycin) and oseltamivir were commenced after specimens were collected for diagnostic testing. He became progressively more hypoxic over the next 24 hours. An echocardiogram was carried out with no significant changes compared with a baseline exam one year ago. chest film revealed patchy infiltrates in his right lower lobe (**Figure 1B**). Additional specimens were collected for atypical pneumonia testing, and after routine bacteriology, acid-fast bacillus smears, and screening influenza exams were reported as negative.

On the morning of October 13, he was tachypneic, tachycardic, and required additional oxygen to maintain

saturation above 90%. An updated chest film showed dense consolidation of his right lower lobe (**Figure 1C**). That afternoon, he underwent intubation for mechanical ventilation and was transferred to the ICU with an admitting diagnosis of severe pneumonia.

**Intensive care unit course.** Antibiotics were changed to piperacillin-tazobactam plus linezolid; treatment with corticosteroids was initiated. His respiratory status stabilized. Immunofluorescent staining of respiratory epithelial cells for influenza A, B, respiratory syncytial virus (RSV), parainfluenza 1-3, and adenovirus were reported negative, and he was confirmed to be seronegative for human immunodeficiency virus (HIV), *Mycoplasma pneumoniae*, Q fever, and Brucella. On October 14, he became hypotensive and required fluid and inotropes to maintain his blood pressure. His renal function also began to deteriorate, and on October 15, he began continuous renal replacement for 2 days. This was followed by 3 hemodialysis sessions concluding on October 23. Between October 15 and 19, oxygen requirements were moderated and he gradually defervesced, although chest radiographs continued to show infiltrates. He was taken off inotropic support on October 17. Steroids were tapered; antibiotics and oseltamivir were discontinued 2 days later. He remained afebrile, and his oxygen requirements diminished. On October 20, the process of weaning him from the ventilator began. Three days later he was extubated. By October 27, his right lung infiltrates had resolved, and he could walk without feeling breathless. He was discharged home on November 4. A summary of the ICU ventilator and dialysis days, plus routine laboratory test values, pre- and post-admission is shown in **Table 1**.

**Coronavirus laboratory testing.** Upper tract swabs in viral transport media were forwarded to the Ministry of Health regional laboratory for nCoV upE reverse transcriptase polymerase chain reaction (RT-PCR). A second set of specimens including tracheal aspirate,



**Figure 1** - Chest radiographs obtained at: A) pre-admission on October 10; B) on admission (October 12); C) second day of admission (October 13).

**Table 1** - Routine laboratory test values, pre- and post-admission intensive care unit ventilator days, and dialysis treatment days.

Variables	Days												
	10 Oct ER	12 Oct ER2	13 Oct Day 2 ICU	14 Oct Day 3	15 Oct Day 4	16 Oct Day 5	19 Oct Day 8	21 Oct Day10	23 Oct Day12	25 Oct Day14	27 Oct Day16	4 Nov Day 24 Home	11 Nov Day 31
<i>Laboratory results (normal range)</i>													
White cells 4.0 - 11.0 (10 <sup>9</sup> /l)	13.8	6.9	5.5	5.4	6.2	6.6	9.8	8	7.8	9.2	7.9	8.7	ND
Lymphocytes 1.5 - 4.0 (10 <sup>9</sup> /l)	0.9	0.7	0.7	0.8	0.9	1.7	1.7	1.2	1.9	1.3	1.9	3.2	ND
Neutrophils 1.8 - 7.5 (10 <sup>9</sup> /l)	12.4	6	4.5	4.1	4.5	4.3	7.3	6.4	5.2	7.2	4.8	4.4	ND
Platelets 150 - 450 (10 <sup>9</sup> /l)	154	154	139	160	203	213	375	328	268	275	313	332	ND
Hemoglobin 12.5 - 18.0 (g/dl)	13.8	12.4	10.9	11.1	10.6	9.6	8.7	8	9.6*	9.2	9.4	12	ND
NT-pro BNP >300 pg/mL	ND	113	117	145	ND	ND	ND	ND	ND	ND	ND	ND	ND
Troponin T <0.1 ng/mL	ND	0.03	0.024	ND	0.046	0.045	ND	ND	ND	ND	ND	ND	ND
Total bilirubin 0 - 17 (umol/L)	8	4	4	4	ND	3	4	8	12	7	ND	5	5
Albumin 38 - 51 (g/L)	25	23	19	20	24	30	23	31	34	31	35	32	44
Alanine transaminase 2 - 40 (U/L)	53	28	23	26	ND	30	91	76	58	39	ND	22	24
Aspartate transaminase 2 - 37 (U/L)	ND	21	34	26	30	36	ND	20	19	ND	32	ND	ND
Creatine kinase 50 - 190 (U/L)	ND	30	40	34	100	390	ND	129	79	ND	99	ND	ND
Lactate dehydrogenase 135 - 255 (U/L)	ND	161	ND	223	369	227	ND	182	240	ND	257	ND	ND
Sodium 135 - 145 (mmol/L)	125	129	134	138	142	144	147	149	144	ND	149	135	138
Potassium 3.2 - 5.0 (mmol/L)	3.8	4.1	4.5	4.9	5.4	5.1	3.9	3.5	3.1	ND	4.4	4.3	4.6
Ventilator days			yes	yes	yes	yes	yes						
Dialysis days					CCRT	CCRT	HD	HD	HD				

\*after transfusion with packed red blood cells; ER - emergency room; ICU - intensive care unit; ND - not done; CCRT - continuous renal replacement treatment; HD - hemodialysis; NT-pro BNP - N-terminal prohormone of brain natriuretic peptide

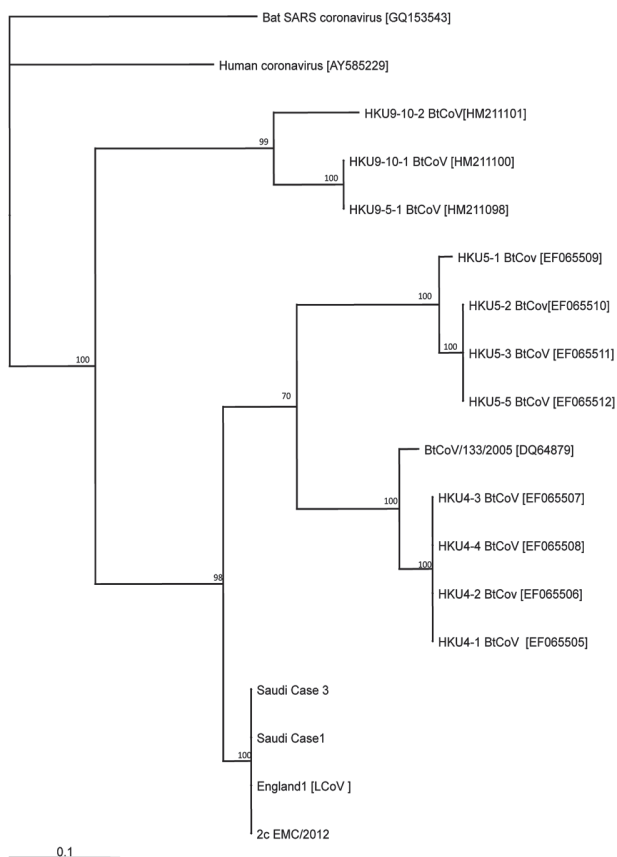
plasma, serum, and stool were collected on October 23 and sent to the HPA's West Midlands Public Health Laboratory, Birmingham UK, to evaluate the patient further for influenza A subtypes, RSV, adenovirus, metapneumovirus, and rhinovirus, in addition to nCoV upE gene and other coronavirus nucleic acid targets. All specimens were confirmed negative for minor coronaviruses. Novel coronavirus upE gene was detected in all respiratory specimens: swabs tested in Jeddah, and tracheal aspirates tested in Birmingham. In addition, the HPA Respiratory Virus Unit, Colindale, UK, confirmed detection of ORF 1B and N genes in the tracheal aspirates. None of his other specimens (stool, plasma, or serum) were positive for nCoV RNA targets. Testing for other respiratory agents was also negative.

**Sequencing of the ORF 1B and E gene fragments.**

Evaluating genetic diversity of this new agent awaits further studies, however, we undertook limited Sanger sequencing of a small portion of the E gene and the

ORF 1B gene (amplified in a PCR using published transcript primers)<sup>3</sup> for Saudi Arabia case one and our patient, Saudi Arabia case 3. Both samples produced identical reads and are aligned with the published sequences of human beta coronavirus 2c EMC/2012 (JX869059.2)<sup>4</sup> in **Figure 2**. Similar alignments were also conducted with the same gene fragments and case 2, the Qatar/London patient, the genomic sequence of which was recently published ([http://www.hpa.org.uk/webc/HPAwebFile/HPAweb\\_C/1317136950605](http://www.hpa.org.uk/webc/HPAwebFile/HPAweb_C/1317136950605)). The sequences are identical for all 3 cases. These sequence fragments were also compiled with the published sequences<sup>4</sup> of other closely related coronaviruses and alignments made to construct a simple phylogeny. **Figure 3** shows the phylogenetic context of the ORF 1B fragment with other related coronaviruses.

**Discussion.** On 20 September 2012, ProMed Mail<sup>1</sup> reported novel coronavirus infections in 2 patients who



**Figure 2** - Maximum likelihood phylogenetic tree compiled from alignments made from a 311 nt sequence length of Orf1B [nts18105-18414 2cEMC/2012 (JX869059.2)], rooted with Bat SARS CoV. Tree Alignments were made with ClustalW and phylogenetic placements reconstructed using TREE-PUZZLE.

**Sequence of E - Gene fragment (Case 3 = Case 1) alignment with Human betacoronavirus 2c EMC/2012 (gb JX869059.2)**

Strand=Plus/Plus

Case 1	63	1	ATACACCAAAACCATTTATTATTAGAACTTCGATCAGCGTTGCAGCTGTTCTCGTGT	60
EGene nt27278			ATACACCAAAACCATTTATTATTAGAACTTCGATCAGCGTTGCAGCTGTTCTCGTGT	27337
Case 1	61	61	TTTTATTGGACTCTTCCACTTATATAGAGTGCACTTATATTAGCCGTTTAGTAGATT	120
EGene nt27338			TTTTATTGGACTCTTCCACTTATATAGAGTGCACTTATATTAGCCGTTTAGTAGATT	27397
Case 1	121	121	AGCCTAGTTTCTGTAAGTACTTCTCCCTTAAACGGCAATGTTCCACTGTTTCTGCCT	180
EGene nt27398			AGCCTAGTTTCTGTAAGTACTTCTCCCTTAAACGGCAATGTTCCACTGTTTCTGCCT	27457
Case 1	181	181	GCAACGCGGATTGAGTTCCTTCCACATAATCGCCCGAGCTCGCTTATCGTTAAGCA	240
EGene nt27458			GCAACGCGGATTGAGTTCCTTCCACATAATCGCCCGAGCTCGCTTATCGTTAAGCA	27517
Case 1	241	241	GCTCTGGCTACTATGGTCCCGTGTAGAGGCTTAATCATTAGTCTCTCTTTGGACATAT	300
EGene nt27518			GCTCTGGCTACTATGGTCCCGTGTAGAGGCTTAATCATTAGTCTCTCTTTGGACATAT	27577
Case 1	301	301	GGAAACGAACACTATGTTACCTTTTGTCCAAAGCAATAGGTTGTTCTAGTAAACTTT	360
EGene nt27578			GGAAACGAACACTATGTTACCTTTTGTCCAAAGCAATAGGTTGTTCTAGTAAACTTT	27637
Case 1	361	361	TTCAATTTTACCGTAGTATGCTATAACACTCTTGGTGTATGGCTT	409
EGene nt27638			TTCAATTTTACCGTAGTATGCTATAACACTCTTGGTGTATGGCTT	27686

**Sequence of ORF 1B fragment (Case 3 = Case 1) alignment with Human betacoronavirus 2c EMC/2012 (gb JX869059.2)**

Strand=Plus/Plus

Case 1	63	CGAGTGATGAGCTTTGGCGTAATCTTAATTTACCCGCAATGTCCCACTCTCGTGT	61
Orf1B nt18105		CGAGTGATGAGCTTTGGCGTAATCTTAATTTACCCGCAATGTCCCACTCTCGTGT	18164
Case 1	121	TTTCAGGATGGGCTTTAAACTCGATGCAACAGTTCCTGGATATCCTAAGCTTTTCATTA	121
Orf1B nt18165		TTTCAGGATGGGCTTTAAACTCGATGCAACAGTTCCTGGATATCCTAAGCTTTTCATTA	18224
Case 1	181	CTGTGAAGAGGCTGTAAGGCAAGTTCGAAGCTGGATAGGCTTCGATGTTGAGGTGCTC	181
Orf1B nt18225		CTGTGAAGAGGCTGTAAGGCAAGTTCGAAGCTGGATAGGCTTCGATGTTGAGGTGCTC	18284
Case 1	241	ATGCTTCCCGTAATGCAATGGCAACCAATGTGCCCTTACAATTAGGATTTCAACTGGT	241
Orf1B nt18285		ATGCTTCCCGTAATGCAATGGCAACCAATGTGCCCTTACAATTAGGATTTCAACTGGT	18344
Case 1	301	TGACTTTGTTGTTGACGCAAGTGTGTTGTAGACACTGAGTGGGTAAACATGTTAACGG	301
Orf1B nt18345		TGACTTTGTTGTTGACGCAAGTGTGTTGTAGACACTGAGTGGGTAAACATGTTAACGG	18404
Case 1	311	GCATTGCTGC	311
Orf1B nt18405		GCATTGCTGC	18414

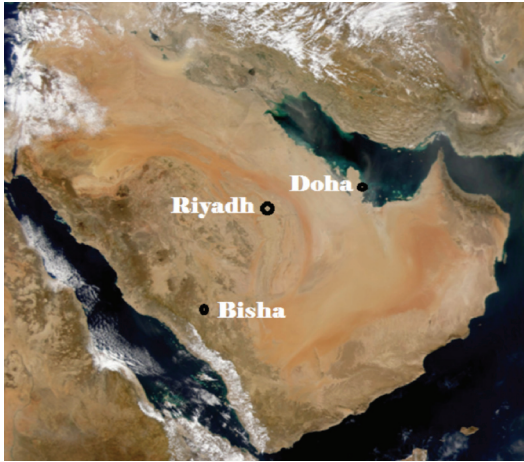
**Figure 3** - Case one and 3 nucleotide fragment sequences of E and ORF 1 B aligned to the reference sequence (JX869059.2) showing 100% identity with corresponding nucleotides.

were lifelong residents of the Arabian Peninsula (Figure 4). Both presented with severe pneumonia; the first in early June 2012, a 60-year-old Saudi businessman who died of his infection; and the second in early September, a 49-year-old Qatari businessman later transferred to London where he remains hospitalized. Both men also experienced renal compromise of uncertain etiology in the course of their illness. We report here a third patient with a similar syndrome, this time a gym-teacher from Riyadh with acute onset of respiratory distress requiring ventilation and an ICU admission. Although he has underlying cardiovascular disease, diabetes, and a single kidney, he survived his illness.

The virus responsible for all 3 cases was first isolated sometime in early June from case one at the Soliman Fakeeh Hospital in Jeddah, KSA. It has since been identified as a new human coronavirus (nCoV),<sup>5</sup> related to known bat coronaviruses, and to severe acute respiratory syndrome (SARS) coronavirus, which is

memorable for a 2003 outbreak that killed 916 people in more than 25 countries.<sup>6</sup> Despite the similarities, there is little evidence so far that nCoV transmits readily between humans. The ability to identify exposed cases will allow better understanding of nCoV epidemiology and the disease spectrum. Development of diagnostic tests should improve case identification; however, it is worth remembering that fewer than half of the SARS seroconversions were accompanied by positive RT-PCR tests.<sup>7-9</sup> This case is also a reminder that virus isolation methods cannot be replaced entirely by molecular detection tests, particularly where novel viruses are an issue.

Contact investigations are in progress; however, without a validated serologic test from international health authorities, these investigations will remain preliminary. Still to be identified is the agent responsible for 11 cases of severe respiratory disease at an ICU in Zarqa, Jordan. The report by the Jordanian Minister



**Figure 4** - Arabian Peninsula showing location of case one in Bisha, case 2 in Doha, Qatar, and case 3 in Riyadh.

of Health on April 17, 2012, noted that 8 cases were members of the healthcare staff.<sup>10</sup>

In conclusion, severe respiratory infections are commonly encountered in clinical practice. Many, perhaps a majority are never diagnosed. With the discovery of a new coronavirus, and rapid availability of molecular tests for diagnosis, other cases will be identified in the very near future. Our understanding of this virus will grow exponentially.

A few common denominators have emerged. All cases have been middle-aged male residents of the Arabian Peninsula; all have required intensive care admissions and mechanical ventilation, and all had experienced varying degrees of renal impairment while hospitalized. Both prior cases had been previously healthy, but suffered severe disease; one died. The current case survived despite underlying illness and a single kidney. The question of human-to-human transmission remains. None of the 3 cases have been associated with transmission of symptomatic disease to family members or care-givers, however serostatus evaluations of close contacts is pending the availability of a validated serology. Although SARS coronavirus was unquestionably virulent and transmitted readily in many circumstances, it did not cause disease in all whom it was able to infect. Is novel coronavirus a zoonotic disease? Exposure to farm animals has been identified as a risk factor for illness in case one, however exposures appear an insignificant risk factor for cases 2 and 3. However, all cases would have been exposed to recurring dust storms through an arid summer, and possibly aerosolized virus as well. Investigations of potential animal reservoirs are currently in progress.

**Addendum.** As this report goes to press, the Ministry of Health has identified 2 confirmed cases in Riyadh; one patient has died of the infection. Medical and epidemiology investigations are in progress. Active surveillance continues.

**Acknowledgment.** The authors gratefully acknowledge Dr. Ali AlShammari, Director, Laboratory Services, Ministry of Health, Dr. Mashaal A. AlMobrad, Consultant, Department of Medicine, Respiratory Division, Dr. Noura A. El-Khizzi, Consultant, Clinical Microbiology, Prince Sultan Military Medical City, Barry Atkinson of HPA Porton Down, Salisbury, UK, and the WHO Collaborative Centre for Virus Reference and Research for molecular studies and data interpretation. Also, the technical staff of Jeddah regional laboratory, as well as our colleagues at the HPA, Birmingham, and Colindale, UK.

## References

1. Zaki AM. Novel coronavirus - Saudi Arabia: human isolate. ProMED mail. International Society for Infectious Diseases. [updated 20 September 2012] Available from URL: <http://www.promedmail.org/direct.php?id=20120920.1302733>
2. Bermingham A, Chand MA, Brown CS, Aarons E, Tong C, Langrish C, et al. Severe respiratory illness caused by a novel coronavirus, in a patient transferred to the United Kingdom from the Middle East, September 2012. *Euro Surveill* 2012; 17: pii=20290.
3. Corman VM, Eckerle I, Bleicker T, Zaki A, Landt O, Eschbach-Bludau M, et al. Detection of a novel human coronavirus by real-time reverse-transcription polymerase chain reaction. *Euro Surveill* 2012; 17: pii: 20285.
4. Human betacoronavirus 2c EMC/2012, complete genome. GenBank: JX869059.2 Available from URL: <http://www.ncbi.nlm.nih.gov/nuccore/JX869059>
5. Zaki AM, vanBoheemen S, Bestebroer TM, Osterhaus ADME, Fouchier RAM. Isolation of a Novel Coronavirus from a Man with Pneumonia in Saudi Arabia. *N Engl J Med* 2012; 367: 1814-1820.
6. World Health Organization (WHO). WHO summary table of SARS cases by country, 1 November 2002-7. Geneva (CH): WHO; 2003. Available from URL: [www.who.int/csr/sars/country/country2003\\_08\\_15.pdf](http://www.who.int/csr/sars/country/country2003_08_15.pdf) / <http://www.who.int/csr/sars/country/en/>
7. Tang P, Louie M, Richardson SE, Smieja M, Simor AE, Jamieson F, et al. Interpretation of diagnostic laboratory tests for severe acute respiratory syndrome: the Toronto experience. *CMAJ* 2004; 170: 47-54.
8. Peiris JS, Chu CM, Cheng VC, Chan KS, Hung IF, Poon LL. Clinical progression and viral load in a community outbreak in coronavirus-associated SARS pneumonia: a prospective study. *Lancet* 2003; 361: 1767-1772.
9. National Advisory Committee on SARS and Public Health. Learning from SARS: renewal of public health in Canada. [updated 2003 Oct 15] Ottawa (Canada): Health Canada; 2003. Cat no H21-220/2003E. Available from URL: <http://www.hc-sc.gc.ca/english/protection/warnings/sars/learning.html>
10. European Centres for Disease Control (ECDC). Communicable disease threats report (week 18, 29 April-May 2012). Stockholm (Germany): ECDC; 2012. Available from URL: <http://ecdc.europa.eu/en/publications/Publications/CDTR%20online%20version%204%20May%202012.pdf>