

Case Report

# Combined cataract phacoemulsification and aniridia endocapsular rings implantation in a patient with bilateral congenital aniridia and cataract: A case report



Roberto Gonzalez-Salinas<sup>a,\*</sup>; Fabiola Pena-Guani<sup>b</sup>

## Abstract

The objective of this article was to determine the long-term outcome of surgical treatment in a patient with bilateral congenital aniridia and congenital cataracts. The patient was treated by cataract removal and implantation of a single piece IOL in both eyes. Two aniridia rings were also implanted in the capsular bag. The best-corrected visual acuity (BCVA), intraocular pressure (IOP), stability of the intraocular lens (IOL) and subjective glare reduction were measured for two years after the surgery. After 10 months, the IOP in the left eye had increased to 26 mmHg despite the fact that anti-glaucoma medication was added. Therefore, the patient was scheduled for an Ahmed valve implantation. These results suggest that good visual outcomes can be achieved in patients with bilateral congenital aniridia and cataracts. Nevertheless, the IOPs must be continuously monitored, and glaucoma screening performed to prevent further complications.

**Keywords:** Congenital aniridia, Cataract, Aniridia ring, Corneal leucoma

© 2015 The Authors. Production and hosting by Elsevier B.V. on behalf of Saudi Ophthalmological Society, King Saud University. This is an open access article under the CC BY-NC-ND license (<http://creativecommons.org/licenses/by-nc-nd/4.0/>). <http://dx.doi.org/10.1016/j.sjopt.2015.09.002>

## Introduction

Bilateral congenital aniridia is a rare disorder and is characterized by a partial or total absence of the iris associated with foveal hypoplasia which leads to a reduction of the visual acuity and nystagmus from an early age.<sup>1</sup> The prevalence of congenital aniridia is 1:64,000–1:96,000, and higher rates have been reported in patients who are younger than 20 years (1:47,000).<sup>2</sup> Congenital aniridia is associated with defects of the cornea, anterior chamber, iris, lens, retina, macula, and the optic nerve. Approximately, 85% of individuals with aniridia inherit it as an autosomal dominant trait and 13% as part of the autosomal-dominant WAGR

syndrome characterized by Wilms' tumor, aniridia, genitourinary abnormalities, and mental retardation. The remaining patients are associated with other syndromes such as Gillespie syndrome and Peters anomaly.<sup>3</sup> Mutations or intragenic deletions of the *PAX6* gene represent the major causes of aniridia.<sup>4</sup>

Abnormalities frequently associated with aniridia include cataracts, glaucoma, and opacifications of the cornea.<sup>5</sup> Keratopathy develops secondary to limbal stem-cell deficiency and is believed to have an incidence of about 20%. Aniridia associated with glaucoma has a reported incidence of 6 to 75% with 91% of these primarily due to angle and trabecular developmental abnormalities. These patients respond poorly

Received 16 August 2014; received in revised form 10 August 2015; accepted 7 September 2015; available online 30 September 2015.

<sup>a</sup> Biomedical Research Department, Faculty of Medicine, Autonomous University of Queretaro, Mexico

<sup>b</sup> Autonomous University of Queretaro, Mexico

\* Corresponding author at: Autonomous University of Queretaro, Faculty of Medicine, Department of Biomedical Research, Clavel 200, Prados de la Capilla, PO 76176, Querétaro, Mexico. Tel.: +52 4421921200/6240  
e-mail address: [dr\\_rgs@hotmail.com](mailto:dr_rgs@hotmail.com) (R. Gonzalez-Salinas).

to treatment resulting in blindness due to failure of pharmacological therapy, and these patients require frequent glaucoma surgery to achieve an adequate control of the intraocular pressure (IOP).<sup>5-7</sup>

Congenital aniridia is associated with cataracts in 50–85% of patients.<sup>5</sup> Lens opacities combined with the lack of the irides result in glare, photophobia, and reduced visual acuity. However, cataract extraction presents significant technical challenges including reduced visibility of the intraocular structures due to corneal opacities and fragile anterior lens capsule due to a significant thinning of the capsule.<sup>8</sup> This fragility may cause tears in the anterior capsular either during capsulorhexis or by subsequent manipulations. Such complications may require significant alterations of the surgical plan because intraocular lenses and iris prosthetic devices require an intact capsular bag.<sup>9</sup>

Among the options for prosthetic restoration of the irides are devices which allow the implantation of Morcher aniridia rings through an incision of about 3 mm. The aniridia rings are capsular tension rings with multiple fins separated by the same size spaces. Two such rings are implanted into the capsular bag and placed in such a way that the fins of one ring overlap the spaces of the other.<sup>10</sup> Combined phacoemulsification cataract extraction with an implantation of a foldable intraocular lens and aniridia rings placement have been shown to be particularly effective in reducing glare and photophobia in patients with aniridia and albinism.<sup>10,11</sup> We present our findings in a patient with bilateral congenital aniridia who was successfully treated with an implantation of an IOL and aniridia rings.

### Case report

A 26-year-old man presented with complaints of a progressive decrease in his vision and glare in both eyes of 8 months duration. His medical history revealed that his father was diagnosed with open angle glaucoma. The patient's best-corrected visual acuity (BCVA) was 1.0 logMAR units in both eyes. Horizontal pendular nystagmus was present in both eyes. The IOP measured by Goldmann applanation tonometry was 12 mmHg OD and 14 mmHg OS.

Slit-lamp examination of the right eye showed a 360° peripheral corneal vascular proliferation, inferior corneal leucoma, superficial punctate keratitis demonstrated by diffuse epithelial staining of the central cornea with fluorescein, total aniridia, and a NO2NC2 cataract according to the Lens Opacities Classification System II (LOCS II).<sup>12</sup> Slit-lamp examinations of his left eye showed a 300° peripheral corneal

vascular proliferation, mild superficial punctate keratitis, total aniridia, and a NO2NC2 cataract (Fig. 1). A fundus examination revealed absence of macular reflex and a normal optic disk in both eyes. Specular microscopy showed an endothelial cell density of 3289 for the right eye and 2906 cells/mm<sup>2</sup> for the left eye.

Small incision (2.2 mm) phacoemulsification was performed with an implantation of an acrylic foldable intraocular lens (Alcon Laboratories, Inc., Fort Worth, TX, USA). Additionally, a Morcher type 50C endocapsular aniridia ring was placed (Morcher® Type, Morcher Company, Germany), and both the IOL and the aniridia rings were inserted in the capsular bag in both eyes by the same surgeon with an interval of two weeks.

After two months, the BCVA improved to 0.89 logMAR units in both eyes with no signs of inflammation, and the BCVA in the right eye improved to 0.69 logMAR units at the 6 months visit; additionally, a subjective mild improvement in glare perception was referred (Fig. 2).

At the 10th month visit, the patient complained of decreased vision in the left eye (1.3 logMAR units) and was found to have an elevation of the IOP to 26 mmHg. There was also a displacement of one of the rings due to capsular fibrosis and contraction without IOL displacement (Fig. 3). Combined topical dorzolamide and timolol treatment was initiated in the left eye, and at the one year follow-up, the IOP was not significantly decreased despite the fact that a third anti-glaucoma medication was added. Therefore, the patient was treated with an implantation of an Ahmed glaucoma valve in the superotemporal quadrant and the removal of the displaced ring.

Six months later, the BCVA was 0.92 logMAR in the right eye, and the IOP in the left eye was maintained at 14 mmHg with topical timolol.

### Discussion

Cataract is found in 50–85% of the patients with congenital aniridia. Phacoemulsification cataract extraction in patients with aniridia will improve in the BCVA<sup>8-10</sup>; nonetheless, the surgical procedure is often challenging due to abnormalities associated with congenital aniridia, including shallow chamber, corneal leucoma and limited visualization. In addition, the outcome can be limited by a worsening of the keratopathy or the development of glaucoma in more than 50% of the cases.<sup>13</sup> Recent studies have demonstrated a significant association of intraocular surgery and progression of corneal opacities. Moreover, Reinhard et al.,<sup>14</sup>

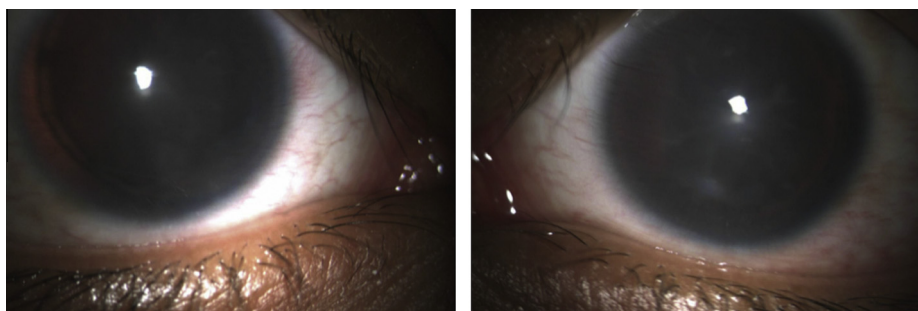
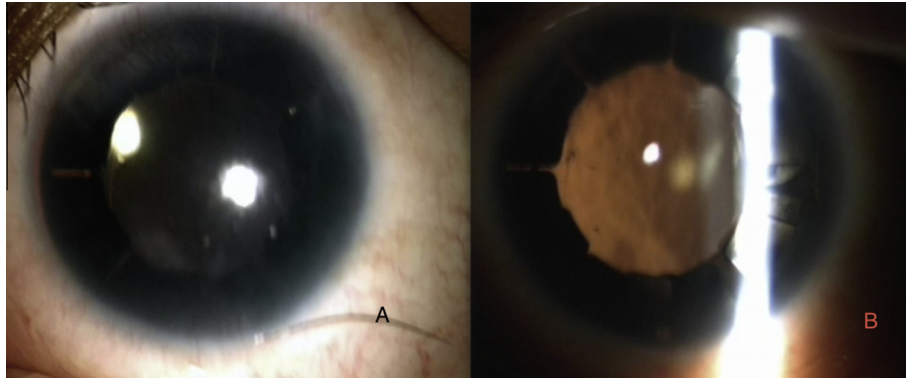
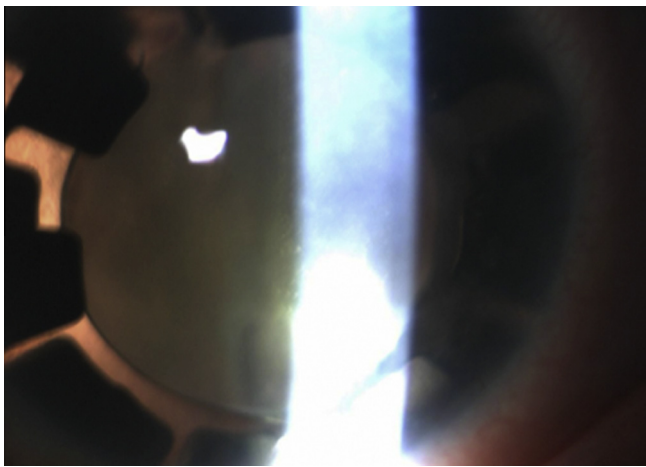


Fig. 1. Slit-lamp photographs of the right and left eyes showing 300° peripheral corneal vascular proliferation, mild superficial punctate keratitis, total aniridia, and cataracts.



**Fig. 2.** Slit-lamp photographs of both eyes. A. Slit-lamp examination of the left eye showing no signs of inflammatory disease two months after the surgical procedures. B. Slit-lamp photograph showing the red reflex of the left eye, with no ring misalignment present.



**Fig. 3.** Slit-lamp photograph of the left eye showing a displacement of one of the rings due to capsular fibrosis without displacement of the intraocular lens.

reported postoperative uveitis, secondary glaucoma, clinically significant macular edema, chronic endothelial cell loss, progression of corneal epithelial disorders, and hyphema. Cataract extraction with IOL implantation can lead to further damage of the limbal stem cells which can cause a permanent deficiency for recovery.

Likewise, Burk et al.,<sup>15</sup> in a 28 patient series of prosthetic iris implantation for congenital, traumatic, and functional iris deficiencies, of which 10 eyes had congenital aniridia, reported incomplete capsulorhexis, transient hypotony, persistent inflammation and glaucoma therapy addition among patients with elevated IOP after the surgical procedure, furthermore, described two capsulorhexis tears while implanting 50C rings due to the fragility of the anterior capsules in eyes with congenital aniridia; which made the rings mobile during the surgical procedure.

In our case, the occurrence of displacement of the iris implant due to a contraction of the capsular bag 10 months after the surgical procedure, leads to persistent inflammation, and constant rise in IOP measurements, which required removal of one of the rings with glaucoma valve surgery in the late post-operative period. Similarly, Gerreiro et al.,<sup>16</sup> described a contraction of the capsular bag, 8 months after cataract phacoemulsification and aniridic ring implantation (Morcher Aniridia rings 50 D) a patient with

Axenfeld-Rieger syndrome. UBM examination showed contraction of the capsular bag, which appeared wrinkled, fibrous, and thickened. The capsular bag comprised the aniridic ring fins, causing misalignment. After 8 months, the glare disability had dropped from grade 0 to 3. This outcome strongly suggests that capsular bag shrinking caused migration of the aniridic rings, 8 months after surgery.

## Conclusion

Combined phacoemulsification cataract extraction with foldable IOL implantation and aniridia rings placement suggests that good visual outcomes can be achieved in patients with bilateral congenital aniridia and cataract. Glaucoma assessment should be performed in all aniridia patients who undergo phacoemulsification cataract extraction; in addition, IOP levels must be evaluated frequently, including an optic disk examination. Refractory cases may require glaucoma filtering surgery.

## Financial disclosure

No author has a financial or proprietary interest in any material or method mentioned.

## Conflict of interest

The authors declared that there is no conflict of interest.

## References

1. Lee H, Khan R, O'Keefe M. Aniridia: current pathology and management. *Acta Ophthalmol* 2008;**86**:708–15.
2. Eden U, Beijar C, Riise R, Tornqvist K. Aniridia among children and teenagers in Sweden and Norway. *Acta Ophthalmol* 2008;**86**:727–9.
3. Eden U, Riise R, Tornqvist K. Corneal involvement in congenital aniridia. *Cornea* 2010;**29**:1096–102.
4. Cheng F, Song W, Kang Y, Yu S, Yuan H. A 556 kb deletion in the downstream region of the PAX6 gene causes familial aniridia and other eye anomalies in a Chinese family. *Mol Vis* 2011;**17**:448–55.
5. Nelson LB, Spaeth GL, Nowinski TS, Margo CE, Jackson L. Aniridia. A review. *Surv Ophthalmol* 1984;**28**:621–42.
6. Tsai JH, Derby E, Holland EJ, Khatana AK. Incidence and prevalence of glaucoma in severe ocular surface disease. *Cornea* 2006;**25**:530–2.
7. Weisschuh N, Wissinger B, Gramer E. A splice site mutation in the PAX6 gene which induces exon skipping causes autosomal dominant inherited aniridia. *Mol Vis* 2012;**18**:751–7.

8. Neuhann IM, Neuhann TF. Cataract surgery and aniridia. *Curr Opin Ophthalmol* 2010;**21**:60–4.
9. Marques FF, Marques DM, Osher RH, Osher JM. Fate of anterior capsule tears during cataract surgery. *J Cataract Refract Surg* 2006;**32**:1638–42.
10. Olson MD, Masket S, Miller KM. Interim results of a compassionate-use clinical trial of Morcher iris diaphragm implantation: report 1. *J Cataract Refract Surg* 2008;**34**:1674–80.
11. Karatza EC, Burk SE, Snyder ME, Osher RH. Outcomes of prosthetic iris implantation in patients with albinism. *J Cataract Refract Surg* 2007;**33**:1763–9.
12. Chylack Jr LT, Leske MC, McCarthy D, Khu P, Kashiwagi T, Sperduto R. Lens Opacities Classification System II (LOCS II). *Arch Ophthalmol* 1989;**107**:991–7.
13. Park SH, Park YG, Lee MY, Kim MS. Clinical features of Korean patients with congenital aniridia. *Korean J Ophthalmol* 2010;**24**:291–6.
14. Reinhard T, Engelhardt S, Sundmacher R. Black diaphragm aniridia intraocular lens for congenital aniridia: long-term follow-up. *J Cataract Refract Surg* 2000;**26**:375–81.
15. Burk SE, Da Mata AP, Snyder ME, Cionni RJ, Cohen JS, Osher RH. Prosthetic iris implantation for congenital, traumatic, or functional iris deficiencies. *J Cataract Refract Surg* 2001;**27**:1732–40.
16. Guerriero S, L'Abbate M, La Tegola MG, Alessio G, Sborgia G. Combined aniridia ring implantation and cataract surgery in an Axenfeld-Rieger syndrome: a UBM report. *Eye Contact Lens* 2011;**37**:45–7.