

Case Report

Severe ischemic retinopathy in a patient with systemic lupus erythematosus without antiphospholipid syndrome A case report



El Asri Fouad*, Momen Hanane, Belmalih Mounir, Zarrouk Rachid, Reda Karim, Oubaa Abdelber

Abstract

Systemic lupus erythematosus (SLE) is a chronic, autoimmune, multisystem disease which may affect the eyes and/or visual system in up to a third of patients. Severe retinal vaso-occlusive diseases have been rarely reported as manifestation in patients with SLE. We report the case of a 35-year-old female treated for systemic lupus erythematosus for 6 months, presented a sudden loss of vision. Fundus examination and fluorescein angiography revealed severe retinal vascular occlusion. This has motivated the search for antiphospholipid antibody syndrome and this was confirmed without the presence of anticardiolipin antibodies. And the treatment consisted in a laser therapy. The purpose of this case report is to demonstrate that an ocular vascular event can reveal the disease and that its diagnosis is important because this disease generally affects young people and may endanger ocular and vital prognosis.

Keywords: Panretinal photocoagulation, Retinal vascular occlusion, Systemic lupus erythematosus

© 2014 Saudi Ophthalmological Society, King Saud University. Production and hosting by Elsevier B.V. All rights reserved.
<http://dx.doi.org/10.1016/j.sjopt.2014.09.005>

Introduction

Systemic lupus erythematosus is a multisystem disease of unknown etiology characterized by numerous autoimmune phenomena with lesions in multiple organ systems. Ocular manifestations of systemic lupus erythematosus (SLE) include mucocutaneous involvement of the eyelids, secondary Sjogren's syndrome, optic neuropathy. The retinopathy generally consists of cotton wool spots with or without retinal hemorrhages.^{1–3}

Vaso-occlusive disease, particularly in the presence of antiphospholipid antibodies, usually cause devastating and permanent damage to visual function in spite of vigorous treatment and requires treatment with anticoagulation and proliferative retinopathy is treated with laser therapy.^{2,3}

Case report

A 35-year-old woman was admitted because of sudden decrease of visual acuity in the left eye. She had been diagnosed as suffering from systemic lupus erythematosus 6 months ago on the basis of oral ulcers, and general aching and malar rashes on her face and immunological disorder and antinuclear antibody according to the criteria of the revised American College of Rheumatology. She was treated with oral prednisone (60 mg per day) and hydroxychloroquine 400 mg/day.

At presentation she underwent a complete ophthalmological examination. Visual acuity was no light perception in the left eye. Examination of the anterior segment was normal and the lens was clear. The ophthalmoscopic examination with mydriasis showed severe ischemic retinopathy in the left

Received 28 December 2013; accepted 15 September 2014; available online 22 September 2014.

Department of Ophthalmology, Mohammed V Military Teaching Hospital, Rabat, Morocco

* Corresponding author at: Department of Ophthalmology, Mohammed V Military Teaching Hospital, Hay Riad, Rabat, Morocco. Tel.: +212 661881679.

e-mail address: elasri_76@hotmail.com (E.A. Fouad).



Peer review under responsibility of Saudi Ophthalmological Society, King Saud University



Production and hosting by Elsevier

Access this article online:
www.saudiophthaljournal.com
www.sciencedirect.com

eye with papillary neovascularisation (Fig. 1). Retinal fluorescein angiography showed ischemic retinopathy and confirmed the papillary neovascularisation (Fig. 2).

The visual acuity of her right eye was 20/20, with a normal anterior segment and fundus (Fig. 3). The bilateral intraocular pressures (IOP) were both 12 mmHg. Laboratory evaluation revealed abnormal titers of antinuclear antibodies, increased level of erythrocyte sedimentation rate and IgG, with low C3 and C4 complement levels.

On the other hand, the levels of antiphospholipid antibodies (APAs) (including lupus anti-coagulant, anti-cardiolipin and anti-beta2 glycoprotein 1 antibodies), blood lipid, screening for thrombophilia were within normal range. Cardiovascular evaluation (including electrocardiogram, heart color ultrasound, carotid Doppler and head CT) were normal.

These features suggested the clinical diagnosis of vaso-occlusive disease secondary to ocular SLE. The treatment consists in a Panretinal argon laser photocoagulation on the second day after admission but a week later, the patient had a vitreous hemorrhage secondary to neovascularization.

Discussion

SLE is an autoimmune inflammatory disease characterized by numerous autoimmune phenomena with lesions in multiple organ systems. The thrombotic and inflammatory process can affect any part of the eye and result in manifestations such as keratoconjunctivitis, scleritis, uveitis and ischemic optic neuropathy.¹⁻³

Most common retinal findings in SLE are cotton-wool spots, hemorrhage, and vascular abnormalities, these lesions occur in 3% to 29% of cases and generally are found late in the disease. The underlying disease involves microvascular occlusion mediated by circulating immune complexes causing retinal nerve fiber layer infarction.^{1,2} By contrast, a less common but more severe form of ocular disease in SLE is occlusive ocular vascular disease. The process is generally one of diffuse arteriolar occlusion with extensive capillary non-perfusion. After such extensive ischemia various consequences of neovascularisation, such as vitreous hemorrhage, traction retinal detachment, and thrombotic glaucoma, may occur.¹⁻⁴

The pathogenesis of SLE is the production of autoantibodies against cellular components and forming

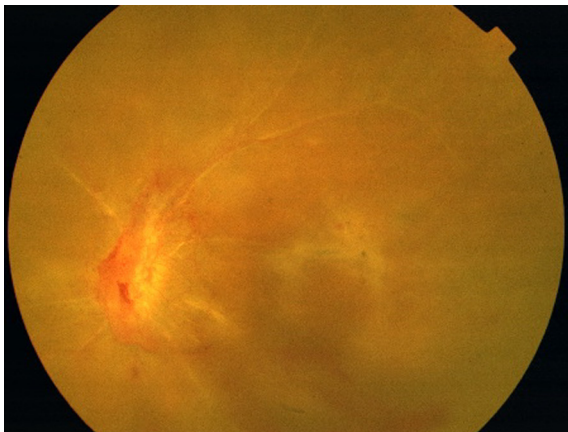


Figure 1. Fundus of the left eye showed severe ischemic retinopathy in the left eye with papillary neovascularisation.

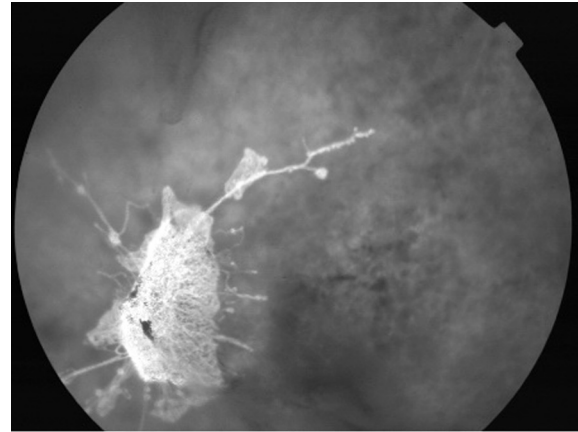


Figure 2. Retinal fluorescein angiography showed ischemic retinopathy and papillary neovascularisation.

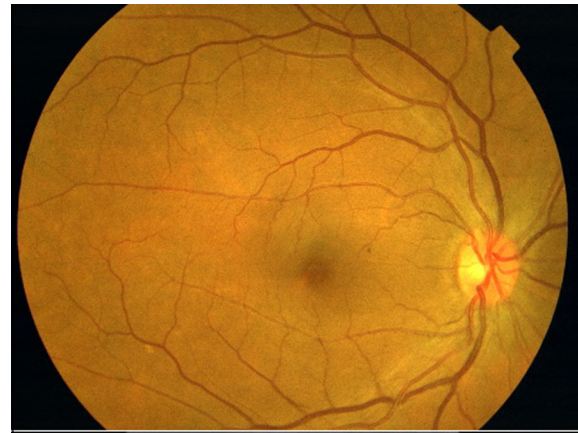

Figure 3. fundus of the right eye was normal.

immune-complex deposition in the end-organ. The activation of complement and inflammatory cells induces tissue damage and systemic disease. Severe vaso-occlusive retinopathy is classically a microangiopathy with diffuse capillary non-perfusion and small arterial or arteriolar occlusions in the retina. It is typically characterized by microthrombosis and immune complex mediated vasculopathy rather than vasculitis.²⁻⁵

A higher risk of developing ocular vascular occlusion is usually indicated in SLE patients with increased serum concentrations of APAs such as the lupus anticoagulant and anti-cardiolipin antibodies. However, low APAs level may occasionally occur in patients of retinal vaso-occlusive retinal disease.³⁻⁵

The clinical significance of the lupus anticoagulant and related antiphospholipid antibodies in patients with SLE are their association with thrombotic events, recurrent fetal wastage and thrombocytopenia. The frequency of the lupus anticoagulant or related antiphospholipid antibodies in patient with SLE has been estimated to be 6.7% to 25%.^{5,6} The differences in incidence of lupus anticoagulants and anticardiolipin antibodies in SLE is not merely a matter of test sensitivities.

Poor visual prognosis is reported in SLE retinopathy with visual loss in 80% of cases and neovascularization in 40% of cases. The permanent loss of visual acuity is likely due to retinal ischemia.^{3,7} The mainstay of treatment for significant retinal disease is systemic immunosuppression. In unilateral

or asymmetric disease, regional corticosteroid injections are sometimes used in addition.

In the presence of significant vaso-occlusive disease (particularly when APA are present), anti-coagulation and the addition of low dose acetylsalicylic acid may be beneficial. Proliferative retinopathy usually requires treatment with laser (panretinal photocoagulation) akin to the treatment of proliferative diabetic retinopathy.^{2,4}

Other therapies that have been reported for severe disease include plasmapheresis and plasma exchange, intravitreal antivascular endothelial growth factor agents, and vitrectomy may also be considered for the treatment of complications of ocular ischemia.⁶⁻⁸

Retinal disease affects around 10% of SLE patients, reflecting a reduction in frequency associated with improved control of systemic disease. Such visual symptoms are therefore an indication for urgent ophthalmic review. The retinal signs often parallel the severity of systemic inflammation, and may indicate inadequate control of the systemic disease. The presence of APA is associated with more severe retinopathy and vascular occlusions.

Conclusion

The presence of retinopathy is suggestive of high disease activity during the history of SLE and may reflect systemic, particularly vascular damage. Close communication between the consultant ophthalmologist and treating rheumatologist

is critical in the effective management of these complex clinical situations.

Conflict of interest

The authors declared that there is no conflict of interest.

References

1. Asherson RA, Merry P, Acheson JF, Harris EN, Hughes GRV. Antiphospholipid antibodies: a risk factor for occlusive ocular vascular disease in systemic lupus erythematosus and the 'primary' antiphospholipid syndrome. *Ann Rheum Dis* 1989;**48**:358-61.
2. Sivaraj RR, Durrani OM, Denniston AK, Murray PI, Gordon C. Ocular manifestations of systemic lupus erythematosus. *Rheumatology* 2007;**46**:1757-62.
3. Zou X, Zhuang Y, Dong F, Zhang F, Chen Y. Sequential bilateral central retinal artery occlusion as the primary manifestation of systemic lupus erythematosus. *Chin Med J* 2012;**125**:1517-9.
4. Ushiyama O, Ushiyama K, Koarada S, Tada Y, Suzuki N, Ohta A, et al. Retinal disease in patients with systemic lupus erythematosus. *Ann Rheum Dis* 2000;**59**:705-8.
5. Leibovitch I, Goldstein M, Loewenstein A, Barak A. Combined central retinal artery and vein occlusion in a patient with systemic lupus erythematosus. *Rheumatology* 2001;**40**:1195-6.
6. Song YH, Kim CG, Kim SD, Kim YY, Chae JY. SLE presenting as retinal vaso-occlusion. *Korean J Intern Med* 2001;**16**:3.
7. Palejwala Neal V, Walia Harpreet S, Yeh S. Ocular manifestations of systemic lupus erythematosus: a review of the literature. *Autoimmune Dis* 2012;**2012**. Article ID: 290898.
8. Sanders MD, Graham EM. Retinal vasculitis. *Postgrad Med J* 1988;**64**:488-96.