

## VIABILITY OF COSTOCHONDRAL GRAFT IN TEMPOROMANDIBULAR JOINT ANKYLOSIS

<sup>1</sup>SAEED AHMED, BDS, MDS

<sup>2</sup>MUHAMMAD ARSHAD BADAR, BDS, FCPS

<sup>3</sup>ARSALAN WAHID, BDS, MPhil

<sup>4</sup>SYED ADNAN ALI SHAH, BDS, MDS, FDSRCS

### ABSTRACT

*Temporomandibular joint (TMJ) ankylosis is a very distressing structural condition that causes severe facial disfigurement leading to pathopsychological stress. Impairment of speech, difficulty with mastication, rampant caries, poor oral hygiene, disturbances of facial growth and severely compromised airway are the leading consequences of TMJ ankylosis. Surgical intervention is the widely accepted treatment modality of TMJ ankylosis. Current study was performed on 30 patients for three years (2009-2012) department of Oral and Maxillofacial Surgery, Children Hospital and Department of Nuclear Medicine, Shaukat Khanum Memorial Cancer Hospital and Research Center, Lahore and costochondral graft was used to treat mandibular ankylosis. 21 (70%) patients were males and were divided into age groups of 2-5, 6-12 and 13-18 years. Regarding the side of mandible involved in male patients, unilateral ankylosis was found in 15(50%) and bilateral ankylosis were found in 6(20%) patients. Similarly in female patients, unilateral ankylosis was found in 7(23%) and bilateral ankylosis was seen in 2(7%) patients. Regarding post operative monitoring of graft, bone scintigraphy was performed one week after the surgery and then after 12 weeks and 16 weeks to assess the viability and uptake of costochondral graft. Tc.99m MDP bone scan was performed in supine position with intravenous administration of 370MBq one week after the placement of graft. Results showed that out of 30 patients, CCG graft was viable in 28(93%) while it was non viable in 2(7%) patients.*

**Key Words:** TMJ ankylosis, Costochondral graft, Bone scintigraphy.

### INTRODUCTION

Temporomandibular joint (TMJ) ankylosis is a very distressing structural condition that causes severe facial disfigurement leading to pathopsychological stress.<sup>1</sup> Ankylosis causes functional and esthetic disturbances and interferes with the nutrition and oral hygiene.<sup>2</sup> Impairment of speech, difficulty with mastication, rampant caries, poor oral hygiene, and disturbances

<sup>1</sup> Assistant Professor and Head (Oral & Maxillofacial Surgery) Children Hospital, Lahore, Pakistan 593-E, Gulshan Ravi, LAhore, Pakistan Phone: +92334-9700958, +92300-4252958 Email: saeedahemd@hotmail.co.uk

<sup>2</sup> Associate Professor and Head (Oral & Maxillofacial Surgery) University Medical & Dental College, Faisalabad, Pakistan Phone: +923334080297 Email: arshad\_badar@hotmail.com

<sup>3</sup> Senior Registrar & Head (Oral & Maxillofacial Pathology) University Medical & Dental College, Faisalabad, Pakistan Phone: +923216685228 Email: dr.arsalanmalik@gmail.com

<sup>4</sup> Professor & Head (Oral & Maxillofacial Surgery) University of Manitoba, Canada Phone: +12049631962 Email: adnan.shah.92@facebook.com

**Received for Publication:** February 8, 2014  
**Revision Received:** February 20, 2014  
**Revision Accepted:** February 25, 2014

of facial growth are the leading consequences of TMJ ankylosis. In addition to these, severely compromised airway results in physical and psychological disability of the patient. It can be so severe in young children that they are completely unable to open their mouth.<sup>3</sup> It may present as unilateral or bilateral. When it occurs before facial growth is completed, it produces micrognathia, especially if the disease is bilateral. In case of unilateral ankylosis, mandible deviates to the affected site.<sup>4</sup> According to the studies performed regarding this, the leading causative factors of TMJ ankylosis are trauma, severe infections (fever of childhood, aural or odontogenic sepsis), forcep delivery, tumors or some degenerative diseases (arthritis) and complications of previous TMJ surgery.<sup>5,6</sup> Treatment guidelines suggested that TMJ ankylosis must be treated as soon as the condition is recognized to prevent the possibility of facial growth restriction.<sup>1</sup> According to the studies conducted in various parts of the world, surgical intervention is the widely accepted management of TMJ ankylosis.<sup>7-10</sup>

A number of surgical techniques have been developed for correction of TMJ ankylosis but the most widely accepted technique is interpositional arthroplasty followed by reconstruction with autogeneous costochondral graft (CCG).<sup>11,12</sup> The growth potential of the costochondral graft makes it the ideal choice in management of TMJ ankylosis in children.<sup>13</sup> After surgical management, post operative monitoring of graft is of prime importance.<sup>14</sup> Several methods have been described in the literature to monitor the circulatory status of the graft but everyone has certain limitations.<sup>15</sup> With the development of sophisticated imaging techniques, bone scintigraphy gained wide spread use in the imaging of bone blood flow and metabolism.<sup>14</sup> Akbay et al used this technique to assess the viability of CCG in his clinical trial.<sup>16</sup> This technique is used with radioactive tracers Methylene diphosphonate and dicarboxy propane diphosphonate (DPD), the most commonly used tracers in clinical bone research.<sup>16</sup> Soundararajan et al used these tracers in his study and reported significant results in this regard.<sup>17</sup> These tracers are highly sensitive for blood flow and metabolic activity of the bony tissues and are in widespread use for graft monitoring in the maxillofacial region.<sup>18</sup> For recording the findings, single photon emission computed tomography (SPECT)<sup>19</sup> should be preferred over conventional planer scanning, because of the complex anatomy of the craniomaxillofacial region.<sup>20</sup>

## METHODOLOGY

This is an interventional study carried out for three years at the Department of Oral and Maxillofacial Surgery, Children Hospital and Department of Nuclear Medicine, Shaukat Khanum Memorial Cancer Hospital and Research Center, Lahore. Total 30 patients of both genders with TMJ ankylosis (unilateral or bilateral) reporting to the Children Hospital Lahore were included in the study. The eligibility criteria for the study was; one, patients of age group 5 to 20 years, two, diagnosed cases of TMJ ankylosis, three, patients medically fit for general anesthesia, four, patients willing to be the part of study. Medically compromised patients, previously operated cases and patients with re-ankylosis were excluded from this study.

A detailed history of the patients was taken and meticulous clinical examination was performed on all the patients presented with TMJ ankylosis. Examination included TMJ examination, occlusal relation, recording of maximum interincisal opening, excursion of mandible and deviation. Standard panoramic view

(orthopantomogram) was obtained as routine for all study subjects. Lateral cephalometric images were taken to assess hypopharynx in relation to sleep apnea and facial profile. Axial and coronal sections of computed tomography of TMJ were advised to reach conclusion. Definitive diagnosis of TMJ ankylosis was established with the help of clinical and radiological findings.

## Details of Intervention

Condylectomy of the patients was performed in the Department of Oral and Maxillofacial Surgery, Children Hospital, Lahore using combined Bramly-Alkayat, modified retromandibular and submandibular incisions. Following gap arthroplasty of 1 to 1.5 cm, the temporalis muscle attachments were severed by carrying out the temporalis myotomy and the temporalis flap was interpositioned in the gap. Costochondral graft was harvested using 5<sup>th</sup> or 6<sup>th</sup> rib on the opposite side. Costochondral graft was fixed to the lateral border of the ramus by the 3 titanium screws measuring 2 x 14mm. Post operative physiotherapy was instituted next day of surgery.

Post operative bone scintigraphy was performed in the Department of Nuclear Medicine, Shaukat Khanum Memorial Cancer Hospital and Research Center, Lahore one week after the surgery and then after 12 weeks and 16 weeks to assess the viability and uptake of costochondral graft. Tc.99m MDP bone scan was performed in supine position with intravenous administration of 370MBq one week after the placement of graft. Images were obtained immediately after the intravenous injection to see the blood flow to the graft. 5-10 minutes later blood pool images were also obtained. Delayed images were taken 3 hours later by a large field of gamma camera interfered with the computer. 10 minutes images were taken for the planer views followed by SPECT (single photon emission computed tomography) image. 64 frames were taken for SPECT image. Each image was for 20-25 seconds. Data was projected on films and reviewed on the computer monitor.

## RESULTS

The study was comprised of 30 patients. Out of them, 21 (70%) were males (Table 1). Patients were divided into age groups of 2-5, 6-12 and 13-18 years. Details of age distributions are summarized in Table 2. The side of mandible involved in ankylosis is shown in Table 3. Patients with unilateral as well as bilateral ankylosis were observed in this study. Pre-oper-

ative inter-incisal opening (IIO) was summarized in Table 4.

The viability of CCG was assessed by using bone scintigraphy and results showed that CCG graft was

TABLE 1: GENDER DISTRIBUTION

	Number	Percentage (%)
Male	21	70
Female	9	30
Total	30	100

TABLE 2: AGE DISTRIBUTION

Age Group (Years)	Male		Female		Total	
	No.	%	No.	%	No.	%
2-5	3	10.0	1	3.0	4	13.0
6-12	12	40.0	6	20.0	18	60.0
13-18	6	20.0	2	7.0	8	27.0

TABLE 3: FREQUENCY OF ANKYLOSIS (UNILATERAL & BILATERAL)

	Male		Female		Total	
	No.	%	No.	%	No.	%
Unilateral	15	50.0	7	23.0	22	73.0
Bilateral	6	20.0	2	7.0	8	27.0

TABLE 4: PRE-OPERATIVE INTER INCISAL OPENING (IIO) 1-9MM

	No.	Percentage (%)
Unilateral ankylosis IIO (3-9mm)	23	77.0
Bilateral ankylosis IIO (0-3mm)	7	23.0
Total	30	100.0

TABLE 5: PERCENTAGE OF RE-ANKYLOSIS

	No.	Percentage (%)
Yes	2	7.0
No	28	93.0
Total	30	100

TABLE 6: POST-OP INTER INCISAL OPENING (IIO)

Age Group (years)	Post Op IIO	Male		Female		Total	
		No.	%	No.	%	No.	%
2-5	25-30mm	3	10.0	1	3.0	4	13.0
6-12	30-35mm	12	40.0	6	20.0	18	60.0
13-18	40-45mm	6	20.0	2	7.0	8	27.0

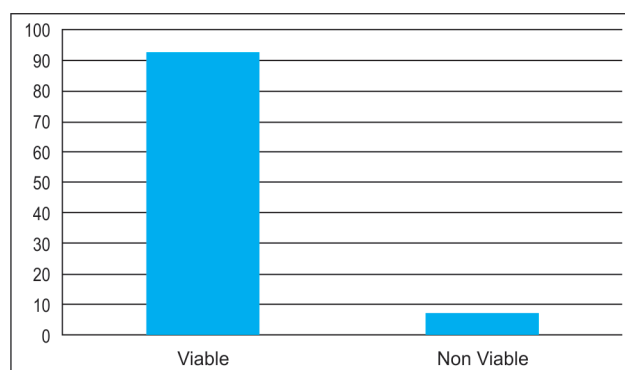


Fig 1: Viability of CCG in bone Scintigraphy

viable in 28(93%) while it was nonviable in 2(7%) patients (Figure 1). Post operative examination of patients revealed that re-ankylosis appeared in 2(7%) patients (Table 5) while post operative IIO was highest in age group of 6-12 years (60%) (Table 6).

DISCUSSION

This interventional study enrolled a sample size of 30 patients which is in agreement with the studies previously performed in various countries.<sup>21-23</sup> TMJ ankylosis involves fusion of the mandibular condyle to the base of skull. This condition is very distressing for patient that makes him unable to avail the benefits of normal diet and causes facial disfigurement as well as significant psychological stress.<sup>24</sup>

Literature has described various causative factors of TMJ ankylosis. In a review, author described the data of 32 cases it was found that ankylosis is most commonly associated with trauma (1-98%), local or systemic infection (10-49%) or systemic diseases. Other studies carried out by Roy Choudhry et al, 1999 and El-Sheikh, 1999, trauma was found to be 86% and 98% cause of TMJ ankylosis respectively.<sup>25</sup>

This study evaluated 30 cases of TMJ ankylosis. Trauma was the cause in every case. The high incidence of TMJ ankylosis in children is because of ignorance and delay in the treatment of condylar fracture.<sup>26</sup>

The pattern of TMJ ankylosis in this study showed the involvement of unilateral TMJ in 73% of cases

and bilateral in 27%. These findings are comparable to a study performed in Turkey where Behcet Erol et al.<sup>27</sup> reported that in his study, 68% of cases were unilateral and 32% bilateral cases. However, gender distribution in the current study differs from his study. In this study male (70%) constituted the group with the highest incidence of ankylosis while in their study female constituted the highest incidence of ankylosis (61%). The age of patients at surgery ranged from 2 years to 18 years. The mean age was 9 years for both genders.<sup>27</sup>

In this study, range of mouth opening was 0-10 mm and the mean value was 4.2 mm. It is in accordance with some other studies. According to Cosanova et al, patients who presented a TMJ ankylosis have a limited opening of the mouth, 1 to 2mm.<sup>28</sup>

Regarding the treatment outcome and post operative assessment, a satisfactory improvement in occlusion and facial harmony was achieved in all cases of this study. In addition, the mean maximal interincisal distance improved by 25-30mm in 2-5 years of patients, 30-35mm in 6-12 years of patients and 40-45mm in patients above 12 years. This is more than the improvement that has been reported by Posnick and Goldstein, 1993.<sup>10</sup> Their post operative values were 11.5mm for bilateral ankylosis and 19.4 for unilateral ankylosis. Others have reported an improvement from the range of 0-12mm to 20-30mm in 29% and to over 30mm in 62% of patients.<sup>10</sup>

The purpose of using the CCG was the fact that it is recognized to be a biological anatomical reconstruction with minimal additional detriment to the patients. Specially in children, the growth potential of the CCG makes it the ideal choice and it also showed good results as an initial reconstruction in adults with congenital deformity or arthritis. It is, however, the variable biological behavior of the graft that can cause problems including overgrowth, resorption and particularly recurrent ankylosis.<sup>29</sup>

In the current study, CCG was taken from the sternal end of the 5<sup>th</sup> or 6<sup>th</sup> rib and used to reconstruct the opposite side for reconstruction of the mandibular condyle of adults as well as children. This is the same technique which was performed in other interventional studies performed in management of TMJ ankylosis. The CCG seems to be the most commonly recommended autogenous graft for this purpose because it adapts easily to the recipient site, it is morphologically similar to the mandibular condyle, the morbidity rate at the

donor site is low and it has verified growth potential in children.<sup>30</sup>

Monitoring of bone graft used in reconstructive surgery can be a major problem. During the first few months, radiographic analysis is unreliable because a 30%-40% alteration in mineral content of bone is necessary before changes are visible. In contrast, bone scintigraphy has proved to be of value especially for the evaluation of grafts to the mandible. Since the introduction of 99m Tc labeled phosphate compounds, new substances have been discovered which provide improved localization capabilities and specificity.

Georg Berding et al. used bone scintigraphy in 11 patients to assess the post operative status of microvascularized bone graft. Each patient had a radionuclide bone study in the third to seventh post operative day (average 3.5). These findings are in agreement with the current study. Researchers advised bone scintigraphy (SPECT) immediately one week, 12 weeks and 16 weeks post operatively for evaluation of CCG viability. Uptake of the radionuclide in the grafted bone is usually interpreted as evidence of bone survival and patent microvascular anastomoses. Metabolically active revascularized bone grafts typically show normal or diffusely increased tracer uptake throughout the grafted bone. However, the failed graft does not concentrate tracer. Hervas et al. applied bone scintigraphy in the follow up of 8 patients who received free fibula flap for mandibular reconstruction.<sup>31</sup> In this study post operative bone scintigraphy was applied in each patient to assess the CCG viability. Out of total 30 CCGs, 2(7%) grafts showed absence of tracer uptake.

## CONCLUSION

TMJ ankylosis especially in children impairs mandible growth and function which may produce a severe facial disfigurement. Trauma is the major cause of TMJ ankylosis in Pakistan. A proper screening of maxillofacial injuries especially condylar injury and referral to maxillofacial centre for early treatment of this injury should be sought. CCGs have proved best reconstruction material mainly because of their biologic similarities and their capacity to regenerate. Bone scintigraphy can be a useful tool for assessment of viability of CCGs. Vascular patency to the graft is characterized by normal or diffusely increased tracer uptake throughout the graft. Non-viable grafts do not concentrate tracer and will appear as photon deficient area in delayed images with reduced flow on the perfusion studies.

## REFERENCES

- 1 Su-Gwan K. Treatment of temporomandibular joint ankylosis with temporalis muscle and fascia flap. *Int J Oral Maxillofac Surg.* 2001; 30: 189-93.
- 2 Erdem E, Alkan A. The use of acrylic marbles for interposition arthroplasty in the treatment of temporomandibular joint ankylosis: follow-up of 47 cases. *Int J Oral Maxillofac Surg.* 2001; 30: 32-36.
- 3 Chidzonga MM. Temporomandibular joint ankylosis: review of thirty-two cases. *Br J Oral Maxillofac Surg.* 1999; 37: 123-36.
- 4 Manganello-Souza LC, Mariani PB. Temporomandibular joint ankylosis: report of 14 cases. *Int J Oral Maxillofac Surg.* 2003; 32: 24-29.
- 5 Balaji SM. Modified temporalis anchorage in craniomandibular reankylosis. *Int J Oral Maxillofac Surg.* 2003; 32: 480-85.
- 6 He D, Cai Y, Yang C. Analysis of Temporomandibular Joint Ankylosis Caused by Condylar Fracture in Adults. *J Oral Maxillofac Surg.* 2013.
- 7 Maki MH, Al-Assaf DA. Surgical management of temporomandibular joint ankylosis. *J Craniofac Surg.* 2008; 19: 1583-88.
- 8 Zhang Y, He DM, Ma XC. [Posttraumatic temporomandibular joint ankylosis: clinical development and surgical management]. *Zhonghua Kou Qiang Yi Xue Za Zhi.* 2006; 41: 751-54.
- 9 El-Sheikh MM. Temporomandibular joint ankylosis: the Egyptian experience. *Ann R Coll Surg Engl.* 1999; 81: 12-18.
- 10 Posnick JC, Goldstein JA. Surgical management of temporomandibular joint ankylosis in the pediatric population. *Plast Reconstr Surg.* 1993; 91: 791-98.
- 11 Kalra GS, Kakkar V. Temporomandibular joint ankylosis fixation technique with ultra thin silicon sheet. *Indian J Plast Surg.* 2011; 44: 432-38.
- 12 Dimitroulis G. The interpositional dermis-fat graft in the management of temporomandibular joint ankylosis. *Int J Oral Maxillofac Surg.* 2004; 33: 755-60.
- 13 Qudah MA, Qudeimat MA, Al-Maaita J. Treatment of TMJ ankylosis in Jordanian children - a comparison of two surgical techniques. *J Craniofac Surg.* 2005; 33: 30-36.
- 14 Liu G, Li Z, Dong Y. [Autogenous costochondral graft applied in the reconstruction of the temporomandibular joint]. *Zhonghua Zheng Xing Wai Ke Za Zhi.* 2000; 16: 163-65.
- 15 Al Qattan MM, Boyd JB. "Mini paddle" for monitoring the fibular free flap in mandibular reconstruction. *Microsurgery.* 1994; 15: 153-54.
- 16 Akbay E, Aydogan F. Reconstruction of isolated mandibular bone defects with non-vascularized corticocancellous bone autograft and graft viability. *Auris Nasus Larynx.* 2014; 41: 56-62.
- 17 Soundararajan R, Naswa N, Sharma P, Karunanithi S, Nazar AH, Das KJ, et al. SPECT-CT for characterization of extrasosseous uptake of <sup>99m</sup>Tc-methylene diphosphonate on bone scintigraphy. *Diagn Interv Radiol.* 2013; 19: 405-10.
- 18 Jovanovic V, Maksin T, Rastovac M, Bzenic J. Comparative quality control of <sup>99m</sup>Tc-Pyrophosphate and <sup>99m</sup>Tc-diphosphonate radiopharmaceuticals. *Eur J Nucl Med.* 1983; 8: 179-82.
- 19 Ogunsalu C, Archibald A, Ezeokoli C. Emerging applications of an experimental single photon emission computed tomography: an analysis of 16 areas of interest in the pig's model. *West Indian Med J.* 2012; 61: 916-20.
- 20 Schimming R, Juengling FD, Lauer G, Schmelzeisen R. Evaluation of microvascular bone graft reconstruction of the head and neck with 3-D <sup>99m</sup>Tc-DPD SPECT scans. *Oral Surg Oral Med Oral Pathol Oral Radiol Endod.* 2000; 90: 679-85.
- 21 Yazdani J, Ali Ghavimi M, Pourshahidi S, Ebrahimi H. Comparison of clinical efficacy of temporalis myofascial flap and dermal graft as interpositional material in treatment of temporomandibular joint ankylosis. *J Craniofac Surg.* 2010; 21: 1218-20.
- 22 Liu Y, Li J, Hu J, Zhu S, Luo E, Hsu Y. Autogenous coronoid process pedicled on temporal muscle grafts for reconstruction of the mandible condylar in patients with temporomandibular joint ankylosis. *Oral Surg Oral Med Oral Pathol Oral Radiol Endod.* 2010; 109: 203-10.
- 23 Danda AK, SR, Chinnaswami R. Comparison of gap arthroplasty with and without a temporalis muscle flap for the treatment of ankylosis. *J Oral Maxillofac Surg.* 2009; 67: 1425-31.
- 24 Widmark G. On surgical intervention in the temporomandibular joint. *Swed Dent J Suppl.* 1997; 123: 1-87.
- 25 El-Sheikh AM, Hobkirk JA, Kelleway JP. Effects of superstructure type and design on force transmission via implant-stabilised mandibular prostheses. *Eur J Prosthodont Restor Dent.* 1999; 7: 45-50.
- 26 Das UM, Keerthi R, Ashwin DP, VenkataSubramanian R, Reddy D, Shiggaon N. Ankylosis of temporomandibular joint in children. *J Indian Soc Pedod Prev Dent.* 2009; 27: 116-20.
- 27 Erol B, Tanrikulu R, Gorgun B. A clinical study on ankylosis of the temporomandibular joint. *J Craniofac Surg.* 2006; 34: 100-106.
- 28 Casanova MS, Tuji FM, Ortega AI, Yoo HJ, Haiter-Neto F. Computed tomography of the TMJ in diagnosis of ankylosis: two case reports. *Med Oral Patol Oral Cir Bucal.* 2006; 11: E413-16.
- 29 Fan R, Wang H, Wang D. [A preliminary report of histological study on TMJ reconstruction with autogenous costochondral graft]. *Zhonghua Kou Qiang Yi Xue Za Zhi.* 1997; 32: 224-26.
- 30 Katsnelson A, Markiewicz MR, Keith DA, Dodson TB. Operative management of temporomandibular joint ankylosis: a systematic review and meta-analysis. *J Oral Maxillofac Surg.* 2012; 70: 531-36.
- 31 Hervas I, Floria LM, Bello P, Baquero MC, Perez R, Barea J, et al. Microvascularized fibular graft for mandibular reconstruction: detection of viability by bone scintigraphy and SPECT. *Clin Nucl Med.* 2001; 26: 225-29.