

## *Leishmania major* in *Tatera indica* in Estahban, Southern Iran: Microscopy, culture, isoenzyme and PCR

Davood Mehrabani<sup>1</sup>, Mohammad Hossein Motazedian<sup>2</sup>, Qasem Asgari<sup>3</sup>,  
Gholam Reza Hatam<sup>4</sup>, Seyed Mohammad Owji<sup>5</sup>, Ahmad Oryan<sup>6</sup>

### ABSTRACT

**Objectives:** This study identifies the infected rodent hosts to *Leishmania major* in Estahban town, southern Iran during 2004-2005.

**Methodology:** The rodents were caught alive from April 2004 to April 2005 in Estahban town, south of Iran and examined for any skin lesion. An impression was provided from the tissues of feet, tail, ears and any patent lesion, stained with Giemsa and studied microscopically for the presence of amastigotes. All samplings were cultured at 25°C in rabbit blood agar and considered negative if no promastigotes were visible during a two months period. The parasites from any positive culture were cryopreserved in liquid nitrogen pending their identification in PCR and isoenzyme electrophoresis. The femoral bones were histologically and ultrastructurally studied.

**Results:** Among 13 captured rodents, 8 were *Tatera indica* (5 male and 3 female Indian gerbils) and 5 were *Rattus rattus* (3 males and 2 females). Just one female *T. indica* was smear-positive for amastigotes in Mohammad Abad village. This rodent was also found culture positive for leishmanial infection which was confirmed by PCR and enzyme electrophoresis. At histological and ultrastructural levels, many clusters of amastigotes were noticed in the foamy macrophages of the femoral bone marrow.

**Conclusion:** *T. indica* was found for the first time in the area and can be one of the rodents to be a potential reservoir host of *L. major*. It was also shown that femoral bone marrow was the tissue of choice to confirm the presence of macrophages containing the amastigote form of the parasite.

**KEY WORDS:** Cutaneous Leishmaniasis, Epidemiology, Rodent, Reservoir, *L. Major*, *T. Indica*, Iran.

Pak J Med Sci July - September 2011 Vol. 27 No. 4 734-738

### How to cite this article:

Mehrabani D, Motazedian MH, Asgari Q, Hatam GR, Owji SM, Oryan A. *Leishmania major* in *Tatera indica* in Estahban, Southern Iran: Microscopy, culture, isoenzyme and PCR. Pak J Med Sci 2011;27(4):734-738

### INTRODUCTION

Zoonotic cutaneous leishmaniasis (ZCL) caused by *Leishmania major* occurs widely in Iran and is reported as the causative organism in 15 out of 32 provinces of the country.<sup>1</sup> The incidence has doubled over the last decade.<sup>2</sup> In Fars Province, southern Iran, *L. major* was identified in *M. libycus* in Arsanjan,<sup>3,4</sup> Neiriz,<sup>5</sup> Marvdasht,<sup>6</sup> in *T. indica* in Larestan<sup>7</sup> and Shiraz<sup>8</sup> and in *Gerbillus* in Larestan region.<sup>7</sup> Regarding pathological studies, several reports showed the correlation between histopathologic features and prognosis in cutaneous leishmaniasis.<sup>9-11</sup>

---

#### Correspondence:

Gholam Reza Hatam, PhD,  
Associate Professor,  
Department of Parasitology and Mycology,  
Shiraz University of Medical Sciences,  
P.O. Box 71345-1744,  
Shiraz, Iran.  
E-mail: mehrabad@sums.ac.ir

- \* Received for Publication: September 9, 2010
- \* Revision Received: July 30, 2011
- \* Revision Accepted: August 5, 2011

As there was no data available in relation to infection of rodents to *L. major* in Estahban town, this study was performed in the area to determine the rodents infected to *L. major* using different methods of identification including classical microscopy, culture, isoenzyme electrophoresis, PCR, histology and electron microscopy.

## METHODOLOGY

**Study area:** Estahban is located in Fars Province, southern Iran. Its geographical coordinates 28° 56' 22" North and 53° 39' 0" East. The area is dry, dusty and mountainous, with a mean elevation or altitude of about 1500m above the sea level. The summer is warm and winter is mild with much sun throughout the year.

**Trapping:** The rodents were caught alive from April 2004 to April 2005 as described previously<sup>7</sup> in urban and rural localities of Estahban town. The identification of trapped animals was undertaken by Department of Biology of Shiraz University based on relevant taxonomic criteria.<sup>12</sup> The permission for trapping was provided from Fars Environmental Protection Organization. The handling and sacrifices methods were based on the approval of Iranian Veterinary Organization. The study was approved by Shiraz University of Medical Sciences Ethics Committee.

**Smears and Cultures:** Chloroform was used for all scarifications, and then animals were examined for any skin lesions. An impression was provided from the tissues of feet, tail, ears and any patent lesion,<sup>13</sup> popliteal lymph nodes, spleen and liver and stained with Giemsa and studied microscopically for the presence of amastigotes. All samplings were under aseptic condition and cultures were at 25°C in rabbit blood agar as described by Evans.<sup>14</sup> The cultures were regularly checked and considered negative if no promastigotes were visible during a two months period. The parasites from any positive culture were cryopreserved in liquid nitrogen pending their identification in PCR and isoenzyme electrophoresis.

**Enzyme electrophoresis:** Enzyme extraction from the pelleted organism was performed as described previously.<sup>8</sup> Analysis was carried out by discontinuous polyacrylamide gel electrophoresis (PAGE) using a 3% sacking gel, 7.5% separating gel, stacking buffer of Tris/HCL (pH=6.7), resolving buffer of Tris/HCL (pH=8.9) and a tank buffer of Tris/HCL (pH=8.3) run under a constant current of 2mA/well for 150 minutes. Each stain was checked for the activity of five enzymatic systems of nucleoside hydrolase I (NH1) E.C.3.2.2.1, nucleoside hydrolyse II (NH2)

E.C.3.2.2.1, glucose-phosphate isomerase (GPI) E.C. 5.3.1.9, phosphoglucomutase (PGM) E.2.7.5.1 and malate dehydrogenase (MDH) E.C.1.1.37. Electrophoretic band developing conditions were used for each enzyme system as described earlier.<sup>14</sup>

**PCR:** DNA extraction from promastigote cultures and the primers used were identical to Mehrabani et al's study.<sup>7</sup> Samples (10 µL) of the PCR products were each mixed with 5 µL of loading buffer and then separated by electrophoresis in a 1.5% agarose gel. The bands were stained with ethidium bromide and visualized by ultra-violet transillumination. The reference strains were provided from the Pasteur Institute in Tehran including *L. major* (MHOM/TM/1973/5ASKH), *L. tropica* (MHOM/AZ/1974/SAF-K27) and *L. infantum* (MHOM/TN/1980/IPT1) which were also run in the PCR.

**Histology:** The animals were euthanized and the femoral bones, popliteal lymph nodes, spleen and liver were removed and sections of 5mm in thickness were provided and stained with hematoxylin and eosin for histological studies.

**Electron microscopy:** A small part of the fresh tissue with dimensions of 1mm from the femoral bones, popliteal lymph nodes, spleen and liver of each rodent was provided for ultrastructural study under a transmission electron microscope and screened for the presence of amastigotes.<sup>15</sup>

## RESULTS

Thirteen rodents were trapped close to houses. Eight were *T. indica* (5 male and 3 female Indian gerbils) and five were *Rattus rattus* (3 male and 2 female). Just one female *T. indica* was smear-positive for amastigotes in Mohammad Abad village. This rodent was also found culture positive for leishmanial infection. The results of isoenzyme electrophoresis (Figure.1) and PCR (Figure.2) indicated that this rodent was infected to *L. major*. The isoenzyme electrophoretic patterns demonstrated the similarity to *L. major* with RFs of 0.72 and 0.75 in MDH, 0.51 and 0.53 in P6M, 0.35, 0.38, 0.51 and 0.58 in GPI, 0.53 and 0.61 in NH1 and 0.62 in NH2 systems.

Grossly, there were no lesions on the skin of ears, feet, tail and other parts of the body. At histological level, many clusters of amastigotes were observed in the foamy macrophages of the femoral bone marrow containing intracellular *Leishmania* amastigotes (Figure.3). No amastigote was observed in the sections from the lymph node, spleen, liver, and skin. At ultrastructural level, the amastigotes were shown in the cytoplasm of the macrophages of the femoral bone marrow (Figure.4). No

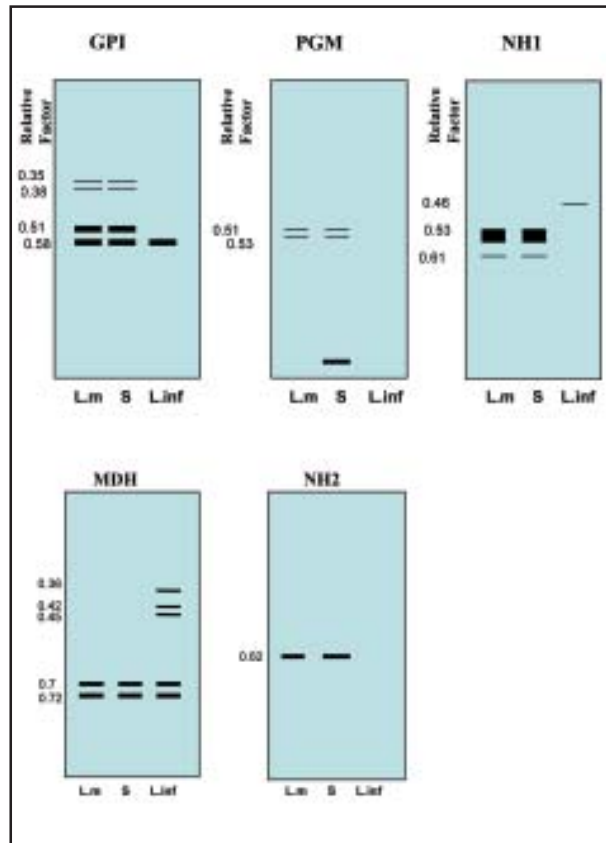


Fig-1: Gel electrophoresis obtained with soluble extracts of *Leishmania* promastigotes of six enzymatic systems from *T. indica* in Estahban town; s = sample, L.inf = *L. infantum*, Lm = *L. major*.

infection was evident in tissue sections of the spleen, popliteal lymph node, or liver.

### DISCUSSION

*T. indica* was demonstrated as the reservoir hosts in northwest parts of Iran.<sup>16,17</sup> In Fars Province, in Shiraz, Larestan and Fasa towns, *T. indica* was reported as the reservoir host of *L. major* respectively.<sup>7,8,18</sup> In Estahban town, just one *T. indica* was infected to *L. major* in Mohammad Abad village and no other collected rodents were infected to the parasite. This rodent was reported as the reservoir host for *L. major* in other parts of the country too.<sup>7,8,17,19</sup>

There are several reports using enzyme systems of GPI, PGM, MDH, NH1 and NH2 to discriminate *L. major* from *L. tropica* and *L. infantum*. We showed that The MDH, GPI, NH1 and NH2 enzyme systems were more efficient to characterize these parasites. Our results are identical to other reports.<sup>20,21</sup> The electrophoretic mobility of our isoenzyme bands was also similar to other reports.<sup>22,23</sup> Le Blancq et al<sup>24</sup> and

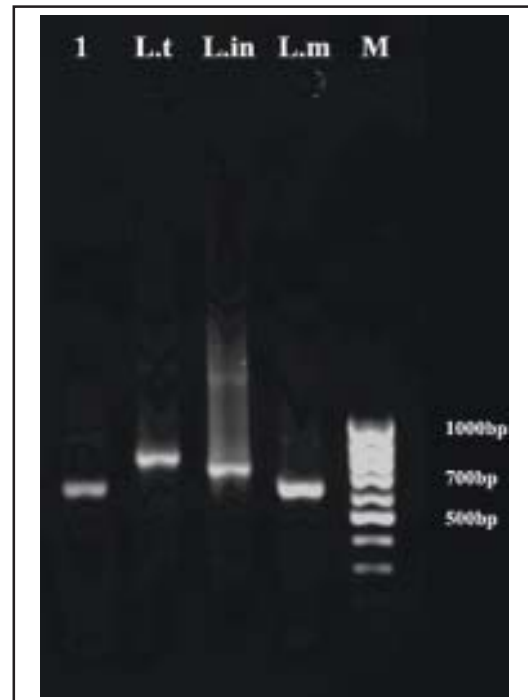

Fig-2: The amplicons produced, in the PCR based on the LINR4 and LIN17 primers, from samples from a male *T. indica* caught in Estahban town. For reference, a sample from *Leishmania tropica* MHOM/AZ/1974/SAF-K27 (L.t), *L. infantum* MHOM/TN/1980/IPT1 (L.in), *L. major* MHOM/TM/1973/5ASKH (L.m) and molecular-weight markers (M) were also run.

Mebrahtu et al<sup>20</sup> recommended MDH system to identify *L. major* and *L. tropica*. Some authors suggested GPI and NH systems for differentiation of *L. major* and *L. tropica* which are identical to our findings.<sup>20,25</sup> It seems that *M. libycus*, *T. indica* and *Gerbillus sp.* are the main rodent hosts of *L. major* in southern Iran.<sup>3-8,18</sup> *T. indica* appears to be a host of *L. major* in Estahban town too which is the first report of infection in a focus of human CL in Fars Province, southern Iran. In histological study of *T. indica*, the femoral bone marrow was the tissue with macrophages infected with amastigote forms of *L. major*. Identical results were shown in golden hamster infected with *L. brasiliensis* in Brazil indicating to amastigote forms of the *Leishmania* parasite in macrophages.<sup>26</sup>

Our results demonstrated that parasitized macrophages are noticed only in the femoral bone marrow. So femoral bone marrow of rodents can be regarded as the tissue of choice for histological and ultrastructural studies to confirm the presence of macrophages containing the amastigote form of the parasite. Changes in socioeconomic status, urban and rural construction developments, new agricultural projects, the storage of waste products nearby the

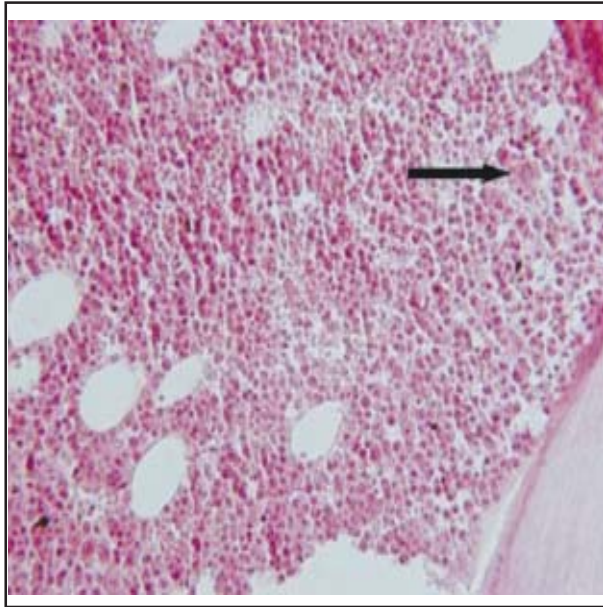


Fig-3: Femoral bone marrow of animal infected with *L. major* showing parasitized macrophages (hematoxylin and eosin, 250X)

town all may be the reason for the increase in the number of wild rodents in the area. Our limitation of the study was the few numbers of captured rodents in the area while just one *T. indica* was infected to *L. major*. As there were several reports of cutaneous leishmaniasis in this region, this rodent which was reported for the first time in the area needs to be followed as a potential reservoir host of *L. major*.

#### ACKNOWLEDGEMENT

The authors would like to thank the Office of Vice Chancellor for Research of Shiraz University of Medical Sciences for financial support. They wish also to thank the Department of Biology of Shiraz University for their cooperation.

**Conflict of Interest:** None declared.

#### REFERENCES

1. Yaghoubi-Ershadi MR, Akhavan AA, Zahraei-Ramazani AV, Abaei MR, Ebrahimi B, Vafaei-Nezhad R, et al. Epidemiological study in a new focus of cutaneous leishmaniasis in the Islamic Republic of Iran. *East Mediterr Health J* 2005;1:816-826.
2. Motazedian MH, Mehrabani D, Oryan A, Asgari Q, Karamian M, Kalantari M. Life cycle of cutaneous leishmaniasis in Larestan, southern Iran. *Iranian J Clin Infec Dis* 2006;1:137-143.
3. Moemenbellah-Fard MD, Kalantari M, Rassi Y, Javadian E. The PCR-based detection of *Leishmania major* infections in *Meriones libycus* (Rodentia: Muridae) from southern Iran. *Ann Trop Med Parasitol* 2003;97:811-816.

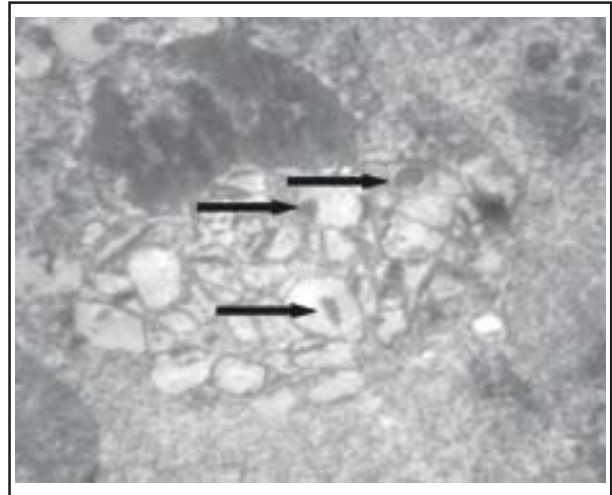


Fig-4: Ultrastructural features of femoral bone marrow section of rodent infected with *L. major* (several *Leishmania* bodies are noticed in macrophages; uranium acetate, lead citrate, 3500x)

4. Rassi Y, Jalali M, Javadian E, Motazedian MH. Confirmation of *Meriones libycus* (Rodentia: Gerbillidae) as the main reservoir host of zoonotic cutaneous leishmaniasis in Arsanjan, Fars Province, south of Iran (1999-2000). *Iranian J Public Health* 2001;30:143-144.
5. Rassi Y, Javadian E, Amin M, Rafizadeh S, Vatandoost H, Motazedian MH. *Meriones libycus* is the main reservoir of zoonotic cutaneous leishmaniasis in south Islamic Republic of Iran. *East Mediterr Health J* 2006;12:474-477.
6. Rassi Y, Gassemi MM, Javadian E, Rafizadeh S, Motazedian MH, Vatandoost H. Vectors and reservoirs of cutaneous leishmaniasis in Marvdasht district, southern Islamic republic of Iran. *East Mediterr Health J* 2007;13:686-693.
7. Mehrabani D, Motazedian MH, Oryan A, Asgari Q, Hatam GR, Karamian M. A search for the rodent hosts of leishmania mojar in the Larestan region of southern Iran: demonstration of the parasite in *Tatera indica* and *Gerbillus* sp. by microscopy, culture and PCR. *Ann Trop Med Parasitol* 2007;101:1-9.
8. Asgari Q, Motazedian MH, Mehrabani D, Oryan A, Hatam GR, Owji SM, et al. Zoonotic cutaneous leishmaniasis in Shiraz, southern Iran. A molecular isoenzyme and morphologic approach. *J Res Med Sci* 2007;12:7-15.
9. Bryceson ADM. Diffuse cutaneous leishmaniasis in Ethiopia: I. The clinical and histological features of the disease. *Trans R Soc Trop Med Hyg* 1969;74:508-521.
10. Destombes P. Application du concept de "systematization polaire" aux leishmaniasis cutanees. *Bull Soc Pathol Exot* 1960;53:299-301.
11. Ridley DS, Marsden PD, Cuba CC, Barreto AC. A histological classification of mucocutaneous leishmaniasis in Brazil and its clinical evaluation. *Trans R Soc Trop Med Hyg* 1980;74(4):508-514.
12. Eisenberg JF, Redford K. Mammals of the Neotropics. Volume 3. The central Neotropics: Ecuador, Peru, Bolivia, Brazil. Chicago, IL. University of Chicago Press. 1999.
13. Edrissian G, Zovein Z, Nadim A. A simple technique for preparation of smears from the ear of *Rhombomys opimus* for the detection of leishmania infection. *Trans R Soc Trop Med Hyg* 1982;76:706-707.

14. Evans DA. Handbook on isolation, characterization and crypreservation of Leishmania. Geneva: World Health Organization. 1989.
15. Rasmusson B, Descoteaux A. Contribution of electron and confocal microscopy in the study of Leishmaniamacrophage interactions. Microscope Microanal 2004;10(5):656-661.
16. Pourmohammadi B, Motazedian MH, Kalantari M. Rodent infection with *Leishmania* in a new focus of human cutaneous leishmaniasis, in northern Iran. Ann Trop Med Parasitol 2008;102:127-133.
17. Javadian E, Dehestani M, Nadim A, Rassi Y, Tahvildar-Bidruni C, Seyedi-Rashti MA, et al. Confirmation of *Tatera indica* (Rodentia: Gerbillidae) as the main reservoir host of zoonotic cutaneous leishmaniasis in the west of Iran. Iranian J Public Health 1998;27:55-60.
18. Mehrabani D, Motazedian MH, Asgari Q, Hatam GR, Owji SM, Oryan A. *Leishmania major* in *Tatera indica* in Estahban, Southern Iran: microscopy, culture, isoenzyme, and PCR. Asian J Anim Vet Sci 2009;6(3):255-264.
19. Seyedi-Rashti MA, Salehzaeh A. A new focus of zoonotic cutaneous leishmaniasis near Tehran, Iran. Bull Soc Pathol Exot 1990;8(2):1145.
20. Mebrahtu YB, Lawyer PG, Pamba H, Koech D, Perkins PV, Roberts CR, et al. Biochemical characterization and zymodeme classification of *Leishmania* isolates from patients, vectors, and reservoir hosts in Kenya. Am J Trop Med Hyg 1992;47(6):852-892.
21. Hosseini SM, Hatam GR, Ardehali S. Characterization of *Leishmania* isolated from unhealed lesions caused by leishmanization. East Mediterr Health J 2005;11(1-2):240-243.
22. Ebert F. Isoenzyme studies on *Leishmania* stocks from Peru by ultrathin-layer isoelectrofocusing. Trop Med Parasitol 1987;38(1):37-40.
23. Kreutzer RD, Souraty N, Semko ME. Biochemical identities and differences among *Leishmania* species and subspecies. Am J Trop Med Hyg 1987;36(1):22-32.
24. Le Blancq SM, Schnur LF, Peters W. *Leishmania* in the Old World: 1. The geographical and hostal distribution of *L. major* zymodemes. Trans R Soc Trop Med Hyg 1986;80:99-112.
25. Al-Tagi M, Evans DA. Characterization of *Leishmania spp* from Kuwait by isoenzyme electrophoresis. Trans R Soc Trop Med Hyg 1978;72(1):56-65.
26. Kahl LP, Byram JE, David JR, Comerford SA, Von Lichtenberg F. *Leishmania* (*Viannia*) *braziliensis*: comparative pathology of golden hamsters infected with isolates from cutaneous and mucosal lesions of patients residing in Tres Bracos, Bahia, Brazil. Am J Trop Med Hyg 1991;44(2):218-232.

**Authors' contributions:**

**Davood Mehrabani:** Main researcher, Concept provider, Pathology, Manuscript writing.

**Mohammad Hossein Motazedian:** PCR and approval of manuscript draft.

**Qasem Asgari:** Field and Lab collaboration.

**Gholam Reza Hatam:** Isoenzyme electrophoresis.

**Seyed Mohammad Owji:** Electronic microscope.

**Ahmad Oryan:** Consultant.

---

Authors:

1. Davood Mehrabani,
2. Mohammad Hossein Motazedian,
3. Qasem Asgari,
4. Gholam Reza Hatam,
5. Seyed Mohammad Owji,  
Department of Pathology,
6. Ahmad Oryan<sup>†</sup>,
- 1,3: Stem Cell and Transgenic Technology Research Center,
- 2-4: Department of Parasitology and Mycology,
- 1-6: Shiraz University of Medical Sciences,  
P.O. Box 71345-1744,  
Shiraz, Iran.