

DEFINITIVE MANAGEMENT OF MORBIDLY ADHERENT PLACENTA: ANALYSIS OF MATERNAL OUTCOMES

Naila Tahir, Muhammad Adil, Bushra Afzal*, Sidra Kiani**, Raza Kiani**, Shahbaz Khan***

Combined Military Hospital Abbottabad/National University of Medical Sciences (NUMS) Pakistan, *Sughra Shafi Medical College Narowal Pakistan, **Shifa International Hospital Islamabad Pakistan, ***Independent Research Specialist

ABSTRACT

Objective: To identify risk factors predisposing to morbidly adherent placenta and to study obstetric outcome in such patients.

Study Design: Retrospective descriptive study.

Place and Duration of Study: Department of Obstetrics and Gynaecology Military Hospital Rawalpindi, from Jan 2014 to Dec 2014.

Material and Methods: A total of 54 patients with morbidly adherent placenta were studied retrospectively. Patient's data including demographic data, previous obstetric history and outcome was collected from hospital records. Data was analyzed by using SPSS version 20.

Results: The incidence of morbidly adherent placenta was 4.74 per 1000 deliveries. Mean age of patients was 33.33 ± 2.82 years with mean gestational age of 35.13 ± 0.91 weeks. All patients had history of prior caesarean section with 4 (7.40%) patients having four, 32 (59.25%) having three, 16 (29.62%) having two and 2 (3.70%) having one previous caesarean section. Associated placenta previa was present in 43 (79.62%) patients. Out of 54 patients 39 (72.22%) had placenta accreta, 11 (20.37%) had placenta percreta while 4 (7.4%) had placenta increta. Obstetric hysterectomy was done in 51 patients while in remaining 3 uterus was preserved. Out of these three, one died as a result of septicemia while methotrexate was started in remaining two cases. However an interval hysterectomy was performed in these two cases because of massive postpartum hemorrhage.

Conclusion: Previous caesarean section and placenta previa are major risk factors for morbidly adherent placenta. Patient education, antenatal diagnosis with well planned surgical intervention and anticipation of blood loss are keys to successful management.

Keywords: Accrete, Caesarean section, Increta, Morbidly adherent placenta, Percreta.

This is an Open Access article distributed under the terms of the Creative Commons Attribution License (<http://creativecommons.org/licenses/by/4.0>), which permits unrestricted use, distribution, and reproduction in any medium, provided the original work is properly cited.

INTRODUCTION

Morbidly Adherent Placenta (MAP), a dreaded obstetric complication that has risen to an alarming rate over the last two decades paralleling the rise of caesarean deliveries¹. Incidence has increased dramatically from 1:2500 to 1:110 deliveries over the last few years². It is catastrophic complication that puts mother at greater risk of life threatening hemorrhage adding significantly to maternal and fetal morbidity and mortality³. It causes negative economic impact due to need for interventional surgical procedures, protracted hospitalization and critical unit care.

MAP or abnormally invasive placenta (AIP) implies abnormal attachment of placenta to uterine myometrium due to some defect in deciduas basalis resulting in atypical insidious placentation⁴. MAP can be total-involving entire placenta, partial-involving a portion of placenta consisting of at least two lobes and focal-involving a single lobe of placenta⁵. MAP has three variants depending upon degree of placental penetration i.e. accrete, increta and percreta. Placenta accreta (75%) is firmly adherent to uterine muscles, increta (17%) invades the myometrium while percreta (7%) extend throughout the length of myometrium and may penetrates surrounding pelvic organs such as bladder and colon⁶. During pregnancy, presentation may either be asymptomatic or patients may present with antepartum hemo-

Correspondence: Dr Naila Tahir, House No 11, St No 7, Sector H, DHA-II Islamabad Pakistan (Email: dr_naila@hotmail.com)

Received: 18 Jul 2016; revised received: 20 Jul 2017; accepted: 04 Dec 2017

rrhage, acute abdomen and abdominal pain while intrapartum it usually manifests as massive hemorrhage, retained products of placenta and uterine rupture⁷.

The risk of MAP increases in parallel with increase number of caesarean deliveries. Preceding uterine surgery (myomectomy, D & C), placenta previa and increasing maternal age are other associated risk factors⁸. Scarred uterus is major risk factor and it has almost doubled the incidence of MAP as reported in literature⁹. The risk of having MAP is about 5% in patient with placenta previa without prior uterine surgery, 24% in those having scarred uterus and 67% in patients having previous four caesarean scars¹⁰.

Different diagnostic modalities including

Table: Baseline characteristics.

S No.	Characteristics	Values
1	Age (years)	
	26-29	2 (3.7%)
	30-34	17 (31.48%)
	35-38	35 (64.81%)
2	Mean Gestational Age (mean \pm SD)	35.13 \pm 0.91
3	Mean Gravidity (mean \pm SD)	3.98 \pm 0.99
4	History of Caesarean section	
	1 C Section	2 (3.7%)
	2 C Section	16 (29.62%)
	3 C Section	32 (59.25%)
	4 C Section	4 (7.40%)
5	Associated Plcenta Previa	43 (79.62%)

grey scale USG, Color Doppler and 3D power Doppler has revolutionized the management. USG is the primary modality for diagnosis with sensitivity/specificity of 93%/79% for grey scale USG and 100%/92-96% for color Doppler⁷. MRI has comparable diagnostic accuracy to USG, so it should be reserved for cases where resection has to be performed to determine the degree of infiltration and where USG is inconclusive¹.

The successful management of MAP requires multidisciplinary approach and depends primarily on prenatal diagnosis. Current management options involve caesarean hysterectomies and conservative (uterine sparing) approach.

Conservative approach may be followed by medical management with methotrexate, internal iliac ligation, uterine artery embolization, D & C or hysteroscopic loop resection¹¹. Management options vary in different patient and in different centres. In current study, we analyze the outcome of MAP management.

MATERIAL AND METHODS

This descriptive retrospective study was conducted at Pak Emirates Military Hospital Rawalpindi, a tertiary care setup from Jan 2014 to Dec 2014 over a period of one year. A total of 54 pregnant females with gestational age greater than 26 weeks who had clinical diagnosis of MAP on USG color Doppler or MRI were included in study while patients with normally situated

placenta delivered normally or via abdominal route were excluded from study. All the patients were selected by non probability convenience sampling technique. Informed consent was taken from all patients.

Hospital record of all the patients meeting inclusion criteria was studied and data was collected on pre designed proforma. Parameters include age, gestational age, history of previous caesarean delivery, history of any intrauterine operative procedure, type of placenta and maternal outcome were studied. All the data was entered, coded and analyzed in SPSS software. Descriptive statistics were produced. Qualitative

variables were expressed as mean \pm SD while quantitative as frequency and percentage.

RESULTS

A total of 13420 deliveries were conducted during study duration, of which 54 patients had MAP giving an incidence of 4.02 per 1000 deliveries. Age range was 26-38 years with mean age of 33.33 ± 2.82 years. Mean gestational age was 35.13 ± 0.91 weeks with range of 35-36 weeks while mean gravidity was 3.98 ± 0.99 . None of the patient was primigravida. Of 54, 4 (7.40%) had history of four previous caesarean section, 32 (59.25%) had three previous caesarean section, 16 (29.62%) had two previous caesarean section and 2 (3.70%) had previous one caesarean section. Associated placenta previa was present in 43 (79.62%) patients. Table shows baseline characteristics of all the patients.

Out of 54 patients, 39 (72.22%) had placenta accreta, 11 (20.37%) had placenta percreta while 4 (7.4%) had placenta increta. Obstetric hysterectomy was done in 51 patients while in remaining 3 uterus was preserved. Out of these three, one died as a result of septicemia while methotrexate was started in remaining two cases. However, an interval hysterectomy was performed in these two cases because of massive postpartum hemorrhage. Figure shows percentage of different type of placentation.

DISCUSSION

In developing countries, obstetric hemorrhage is the leading cause of maternal mortality. Abnormal placental implantation is associated with potential morbidity and mortality. MAP is challenging condition with about 10% reported morbidity and mortality due to massive hemorrhage¹². Its etiology is still unclear; however it is considered that defect in deciduas basalis, remodeling of maternal vasculature and excessive trophoblastic invasion may give rise to adherent placenta. Defective deciduas basalis may results in attachment of placental villi to myometrium leading to abnormal placental invasion which are named as accreta, increta and

percreta depending upon degree of invasion¹³. Placenta accreta is the most common form accounting for 75-78% of the cases of MAP.

Over the last two decades there has been a paradigm shift in the incidence of this entity towards higher side. This shift is attributed to increasing trend in number of c-sections. In our study incidence came out to be 4.02 per 1000 deliveries. Different incidence has been observed at different centres in Pakistan and around the globe. Being tertiary care centre, referred cases form major portion of patient with complicated

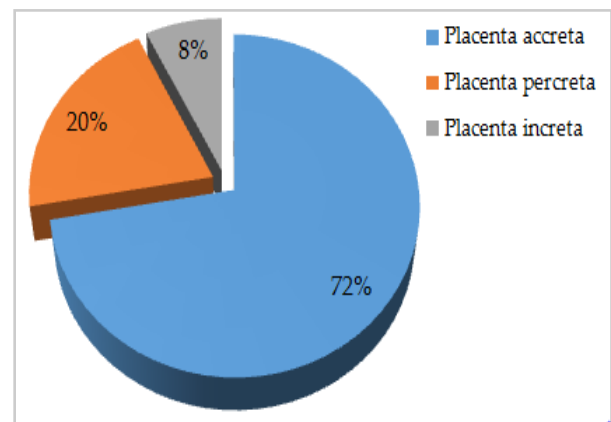


Figure: Type of placentation.

pregnancy. Sultana *et al*¹⁴ reported an incidence of 3.63 per 1000 deliveries while Bailit *et al*¹⁵ came out with an incidence of 1.36 per 1000 deliveries. Difference is due to study population.

The average gestational age in our study was 35.13 ± 0.91 weeks. Rac *et al*¹⁶ reported a gestational age of 33.3 ± 2.8 weeks while Desai *et al*⁶ found average gestational age of 32.1 weeks. According to RCOG, planned delivery at 36-37 weeks of gestation should be done with corticosteroid cover in selected patients¹⁷. Individual characteristics should be kept in mind. Mean gravidity at our setting was 3.98 ± 0.99 . It has been observed in literature that chances of having MAP increases with increasing gravidity. Pekar-Zlotin *et al*¹⁸ stated mean gravidity of 5 ± 2.6 .

Scarred uterus is prime risk factor for the development of MAP in subsequent pregnancy. In our study all patients had prior history of

C-section. Pathological implantation in previous scar is another complication of previous scar leading to Caesarean Scar Pregnancy (CSP)¹⁹. Placenta previa is another recognized risk factor that predisposes to MAP. In our study associated placenta previa was diagnosed in 43 (79.62%) cases. It is stated that previous scar increases the risk of developing MAP 24 times as compared to unscarred uterus. On the other hand, placenta previa in the presence of prior scar is 585 times more prone to develop this condition²⁰. According to Sultana *et al* about 75% cases of MAP are associated with placenta previa¹⁴. In our study 7.40% patients had previous four previous caesarean sections, 59.25% had three, 29.62% had two and 3.70% had previous one caesarean section. Chaudhari *et al*²¹ stated a figure of 50%, 30% and 10% for one, two and three previous scar respectively. In our study population, none of the patient underwent any intrauterine procedure other than c-section so their association with MAP cannot be measured.

Management of adherent placenta is still challenging because of associated morbidity and mortality. A maternal morbidity of 60% and mortality of 7% has been reported in literature²². To cope with these, antenatal diagnosis and multidisciplinary approach are the ways to successful management. In our study 51 patients underwent obstetric hysterectomy which is traditional approach and it has reduced mortality to about 2%². These days, obstetrician and patients prefer conservative approach especially in cases where future fertility is desired. It was first described in 1986 by Arulkumarran and colleagues by using methotrexate²³. In our study, 3 patients were managed conservatively out of which one died of septicemia. Systemic methotrexate was started in remaining two but they had to undergo interval hysterectomy because of postpartum hemorrhage.

In Pakistan, many patients with these obstetric complications are not diagnosed antenatally because they are either unbooked pregnancies or booked at local maternity clinics due to ignorance and poverty. Ultimately such

patients land in drastic complications like massive hemorrhage. Also deficit knowledge to understand the happening and lack of expertise to manage it puts patient's life in risk because of massive blood loss. Such cases reach tertiary care hospital with hemodynamic instability. Its need of time to develop guidelines to revolutionize obstetric care especially antenatal visits, proper antenatal scanning and management interventions in such cases²⁴.

CONCLUSION

Previous caesarean section and placenta previa are major risk factors for morbidly adherent placenta. Patient's education, antenatal diagnosis with well planned surgical intervention and anticipation of blood loss are keys to successful management. Obstetric hysterectomy involving multidisciplinary approach remains the definitive treatment to reduce morbidity and mortality.

CONFLICT OF INTEREST

This study has no conflict of interest to declare by any author.

REFERENCES

1. D'Antonio F, Palacios-Jaraquemada J, Lim P, Forlani F, Lanzone A, Timor-Tritsch I et al. Counseling in fetal medicine: Evidence-based answers to clinical questions on morbidly adherent placenta. *Ultrasound in Obstetrics & Gynecology* 2016; 47(3): 290-301.
2. Vora K, Chandana P, Patel A, Jain M. A prospective study of 20 cases of maternal outcome in morbidly adherent placenta in tertiary care hospital. *Intl J Reproduction, Contraception, Obstetrics Gynecology* 2017; 6(2): 571.
3. Zhang N, Lou W, Zhang X, Fu J, Chen Y, Zhuang Z et al. Vascular complications following prophylactic balloon occlusion of the internal iliac arteries resolved by successful interventional thrombolysis in a patient with morbidly adherent placenta. *J Zhejiang University-Science B*. 2017; 18(3): 272-76.
4. Abuhamad A. Morbidly adherent placenta. *Seminars in Perinatology* 2013; 37(5): 359-64.
5. The Alarming Rise of Adherent Placenta - The Risk of Cesarean Section [Internet]. *Empoweringfertility.com*. 2017 [cited 2017].
6. Available from: <http://empoweringfertility.com/2015/03/the-alarming-rise-of-adherent-placenta-the-risk-of-cesarean-section/>
7. Desai R, Jodha B, Garg R. Morbidly adherent placenta and it's maternal and fetal outcome. *International Journal of Reproduction, Contraception, Obstetrics and Gynecology* 2017; 6(5): 1890.
8. Jalil S, Nausheen S, Akhter AZ. Reducing morbidity and mortality in morbidly adherent placenta: an experience. *Pak J Surg* 2011; 27(1): 59-63

9. Ansar A, Malik T, Shuja S, Khan S. Hysterectomy as a management option for morbidly adherent placenta. *J Coll Physicians Surg Pak* 2014; 24(5): 318-22.
10. Higgins MF, Monteith C, Foley M, O'Herlihy C. Real increasing incidence of hysterectomy for placenta accreta following previous caesarean section. *Eur J Obstet Gynecol Reprod Biol* 2013; 171: 54-6.
11. Cali G, Giambanco L, Puccio G, Forlani F. Morbidly adherent placenta: Evaluation of ultrasound diagnostic criteria and differentiation of placenta accreta from percreta. *Ultrasound in obstetrics & gynecology* 2013; 41(4): 406-12.
12. Hetty M, Dryden D. Morbidly adherent placenta: Ultrasound assessment and supplemental role of magnetic resonance imaging. *Seminars in Ultrasound, CT and MRI* 2015; 36: 324-31.
13. Bennett MJ, S. en RC. Conservative management of placenta previapercreta: Report of two cases. *Aust Z J Obstet Gynaecol* 2003; 43: 249-51.
14. Ibrahim M, Liu A, Dalpiaz A, Schwamb R, Warren K, Khan S. Urological manifestations of placenta percreta. *Current Urology* 2015; 8(2): 57-65.
15. Sultana N, Mohyuddin S, Jabbar T. Management and maternal outcome in morbidly adherent placenta. *J Ayub Med Coll Abbottabad* 2011; 23(2): 14-8.
16. Bailit J, Grobman W, Rice M, Reddy U, Wapner R, Varner M et al. Morbidly adherent placenta treatments and outcomes. *Obstetrics & Gynecology* 2015; 125(3): 683-89.
17. Rac M, Wells C, Twickler D, Moschos E, McIntire D, Dashe J. Placenta accreta and vaginal bleeding according to gestational age at delivery. *Obstetrics & Gynecology* 2015; 125(4): 808-13.
18. Royal College of Obstetricians and Gynaecologists. Green-top Guideline No. 7: Antenatal corticosteroids to reduce neonatal morbidity and mortality. London: RCOG; 2010.
19. Pekar-Zlotin M, Melcer Y, Levinsohn-Tavor O, Tovbin J, Vaknin Z, Maymon R. Cesarean scar pregnancy and morbidly adherent placenta: Different or similar?. *The Israel Medical Association journal: IMAJ* 2017; 19(3): 168.
20. Timor-Tritsch I, Monteagudo A, Cali G, Palacios-Jaraquemada J, Maymon R, Arslan A et al. Cesarean scar pregnancy and early placenta accreta share common histology. *Ultrasound in Obstetrics & Gynecology* 2014; 43(4): 383-95.
21. Cheng K, Lee M. Rising incidence of morbidly adherent placenta and its association with previous caesarean section: A 15-year analysis in a tertiary hospital in Hong Kong. *Hong Kong Med J* 2015.
22. Chaudhari H, Shah P, D'Souza N. Morbidly adherent placenta: Its Management and maternal and perinatal outcome. *J Obstetrics Gynecology India* 2016; 67(1): 42-47.
23. Eller AG, Porter TF, Soisson P. Optimal management strategies for placenta accreta. *BJOG* 2009; 116(5): 648-54.
24. dei Malatesta M. Conservative management of placenta accreta by systemic metho-trexate: Report of two cases and review of the literature. *J Clinical Case Reports* 2016; 06(02).
25. Aziz S, Ather R. Morbidly adherent placenta: Can we limit the aftermath? *J Coll Physicians Surg Pak* 2011; 21(9): 556-8.