

# Cystic Lesions of Lung in Infancy

Nasir Saleem Saddal, Muhammad Anwar, Jamshed Akhtar

## ABSTRACT

*Objective* To describe clinical presentations, investigations performed for diagnosis, treatment provided and outcome of cystic lesions of the lung in infancy.

*Study design* Descriptive case series.

*Place & Duration of study* Department of Paediatric Surgery, National Institute of Child Health Karachi, from January 2010 to February 2012.

*Methodology* Infants admitted with respiratory distress and later suspected of having structural / anatomical cause for the dyspnea were included. X-ray chest was performed in all the cases. CT scan was advised for detail assessment.

*Results* A total of twelve patients were managed during the study period. There were seven male and five female patients. Seven lesions were in left lung and five in right lung. This included seven cases of congenital lobar emphysema (CLE), two of pneumatocele, one each of bronchogenic cyst, isolated lung cyst and necrotizing pneumonia. All patients underwent thoracotomy and procedure was tailored according to the pathological lesion. Excision of involved segment of lung was performed in cases of CLE ( five left upper lobes and two right middle lobes) and necrotizing pneumonia (right upper lobe). Lung cyst was found in the fissure between right upper and middle lobes. In two cases of pneumatocele cyts were opened and after partial excision of the wall. Margins of cysts were over sewed. In a single case of bronchogenic cyst which was adherent to left bronchus excision of cyst and repair of bronchus was done. One patient died in this series.

*Conclusion* Cystic lesions presents in a spectrum; most common being acute respiratory distress. An early diagnosis and prompt surgical intervention is required to prevent morbidity and mortality.

*Key words* Congenital lobar emphysema, Cystic adenomatoid malformation, Bronchogenic cyst, Pneumatocele, Infancy.

## INTRODUCTION:

Cystic lesions of lung can be of congenital and acquired origin. Their origin can be traced to the embryological processes that lead to the development of bronchopulmonary tree. These lesions occur in spectrum.<sup>1</sup> Of the congenital lesions cystic adenomatoid malformations (CCAM) are most commonly encountered.<sup>2</sup> These are frequently reported on antenatal ultrasound and many of the

fetuses develop hydrop fetalis and may die in utero.<sup>3</sup> Other congenital cystic lesions are congenital lobar emphysema, bronchopulmonary sequestrations (intra and extra lobar), lung cysts and bronchogenic cysts.<sup>4</sup>

Pneumonia is a common cause of respiratory distress in paediatric population though there can be host of other conditions that may lead to same symptoms. The structural causes / anomalies related to lung and mediastinum form a distinct group. All have propensity to either remain asymptomatic for variable time and may present with respiratory distress both due to pressure symptoms and pneumonia. This can result in significant morbidity and mortality when treatment is delayed though over the period of

## Correspondence:

Dr. Nasir Saleem Saddal  
Department of Paediatric Surgery  
National Institute of Child Health  
Karachi  
E mail: saddalna@gmail.com

time with increasing early detection of lesions on antenatal ultrasound morbidity and mortality are reduced.<sup>5</sup>

This study was undertaken in a tertiary care hospital which is a referral center so as to find out pattern of presentation of patients with cystic lesions of the lung and outcome following surgical intervention. This will provide an evidence based data upon which further studies can be conducted.

**METHODOLOGY:**

This was a descriptive case series conducted in the Department of Paediatric Surgery, National Institute of Child Health Karachi, from January 2010 to February 2012. Infants admitted with respiratory distress or pneumonia in whom on x-ray chest cystic lesion of lung was suspected, were included. Patients underwent routine medical care for the medical condition including respiratory support, intravenous antibiotics and were subjected to CT scan chest to define details of the lesions.

Infants in whom cystic lesions was identified underwent thoracotomy. Open surgical approach was employed. Surgical procedure was tailored according to the pathological lesion identified and included lobectomy where indicated. Chest tube was routinely placed and infants were kept in intensive care unit till their condition stabilized. Postoperative complications were noted. Outcome in terms of death or discharge was documented.

Data was collected on a proforma. Descriptive statistics were used to present data. Numbers and percentages were used for computation of the results and presented in the form of table.

**RESULTS:**

During the study period twelve patients presented with cystic lesions of the lung. This included seven males and five females. In seven cases the cyst was on left side and in five on right. There was no case with bilateral lung involvement. All patients were initially managed in pediatric medical units as cases of pneumonia. All had an acute onset of respiratory distress. In none of the cases antenatal diagnosis was made (table-I).

Out of twelve cases two were labeled as acquired cases. These were the cases of pneumatoceles as a result of pneumonia. In one case of necrotizing pneumonia it was not clear whether right upper lobe was involved as a secondary phenomenon or was acquired on pre existing lung lesion. In nine cases the cysts were of congenital origin. This included

seven cases of congenital lobar emphysema (CLE), and one case each of bronchogenic cyst and isolated lung cyst.

All patients underwent thoracotomy. In CLE group five lesions were in left upper lobe and two in right middle lobe (Fig I a, b). In two cases pneumatoceles were found. In one of these cases cyst was found in the lower lobe of the left lung (Fig II a, b, c, d). At operation cyst was opened and partial excision of the wall was done. In a single case of bronchogenic cyst which was adherent to left bronchus excision of cyst performed. This was a female baby who developed respiratory distress at the age of 3 days. She was referred from another city. Bronchoscopy was done which showed narrowing of left main bronchus (Fig IIIa, b). At thoracotomy a small cyst measuring 3 cm x 2 cm intimately adherent to left bronchus found. The cyst was excised with difficulty and during dissection bronchus got opened and repaired. The cyst contained mucoid material. This patient developed pussy discharge and lung remained collapsed.

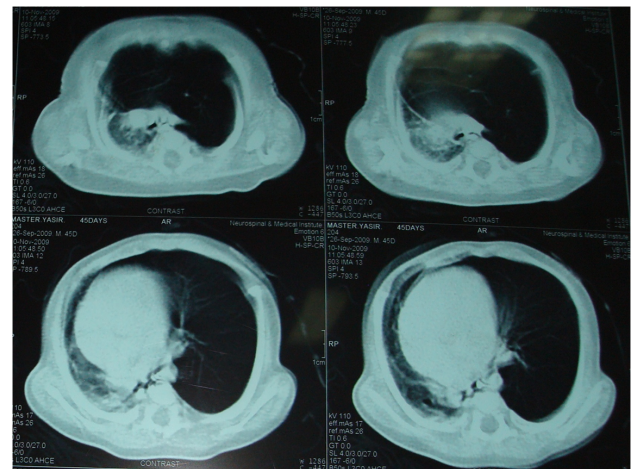


Fig I a: CT scan showing overinflated left upper lobe of the lung.

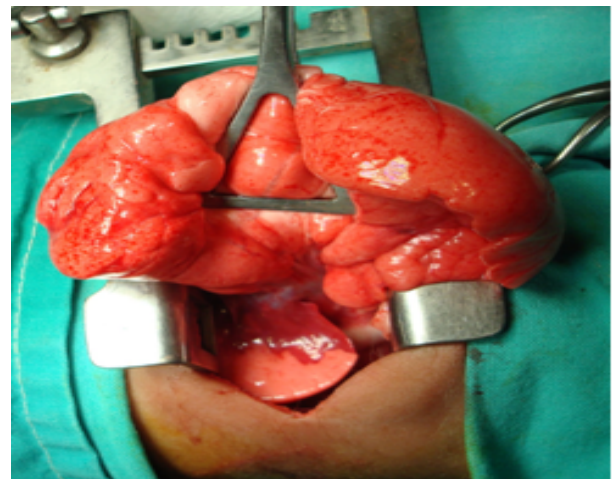


Fig I b: At thoracotomy overinflated lobe popped out.

Table I: Details of cystic lesions of the lung							
	Male	Female	Age	Right	Left	Total	Outcome
Congenital Lobar Emphysema	4	3	6 W to 10 M	2	5	7	All alive
Congenital lung cyst	1	-	8 Month	1	-	1	Died
Bronchogenic cyst	-	1	3 Day	-	1	1	Aive
Necrotizing pneumonia ? secondary to pre existing lung cyst	1	-	4 Week	1	-	1	Alive
Pneumatocele	1	1	4 Month 6 Month	1	1	2	Both Alive
Total	7	5		5	7	12	

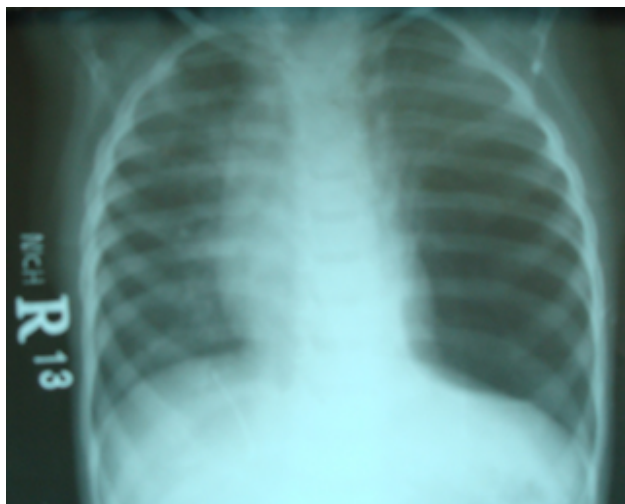

Fig II a: Plain x ray chest showing cystic lesion in the left lower lung field.

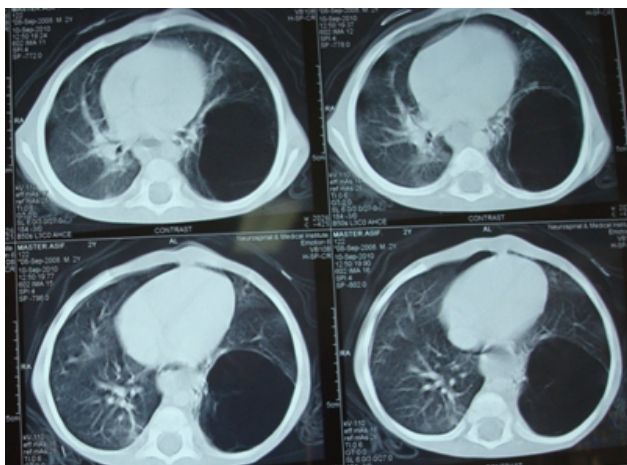


Fig II b: CT scan of same patient delineating anatomical details of lung cyst.

With non operative treatment patient improved and finally discharged. Biopsy report of the cyst revealed cartilage and muscles in the cyst wall.

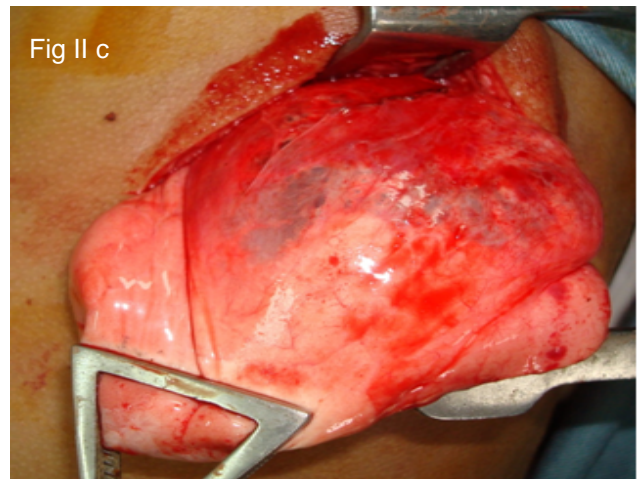


Fig II c

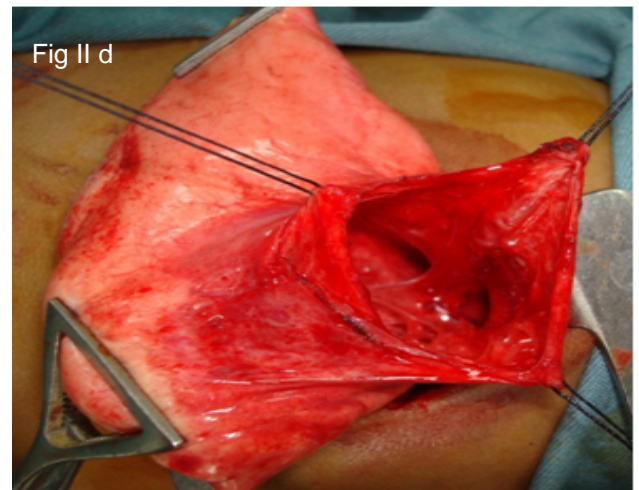


Fig II c & d: Pneumatocele in the lower lobe of the left lung.

The patient with necrotizing pneumonia was four week old, male baby, weighing 3.5 kg. He developed respiratory distress since 15th day of life with high grade fever and episodes of peripheral cyanosis. CT scan showed lesion involving right upper lobe.

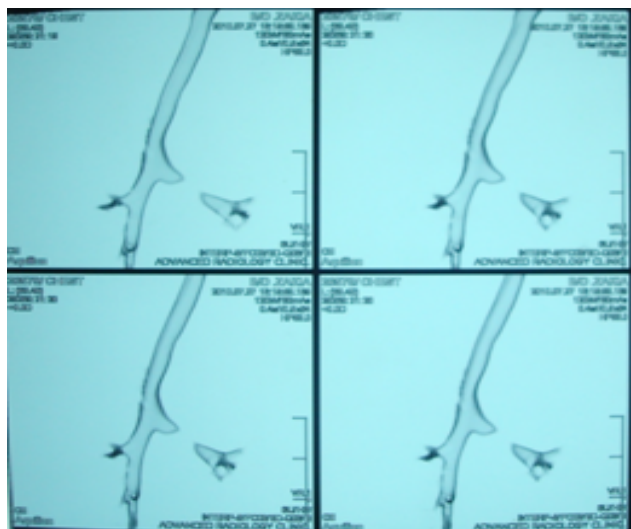


Fig III a: Virtual bronchogram showing narrowing of left main bronchus.

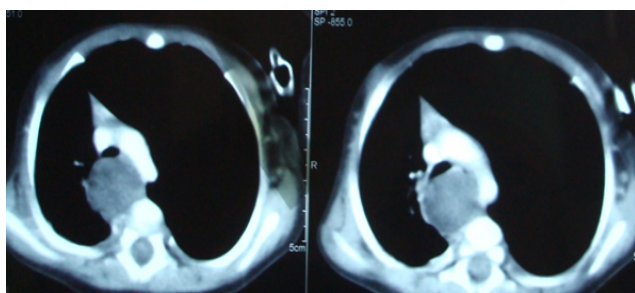


Fig III b: CT scan chest showing location of cyst just to the right of midline causing air trapping in left lung.

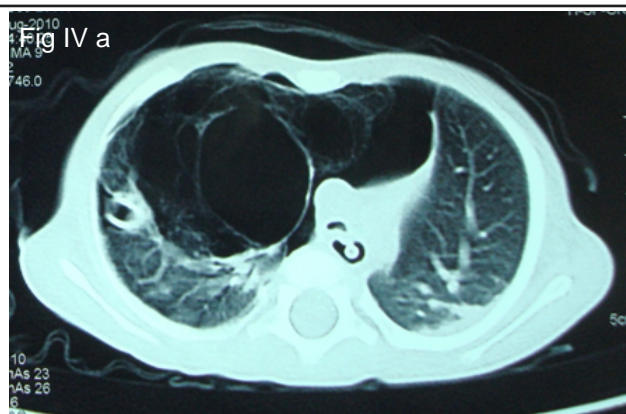


Fig IV a

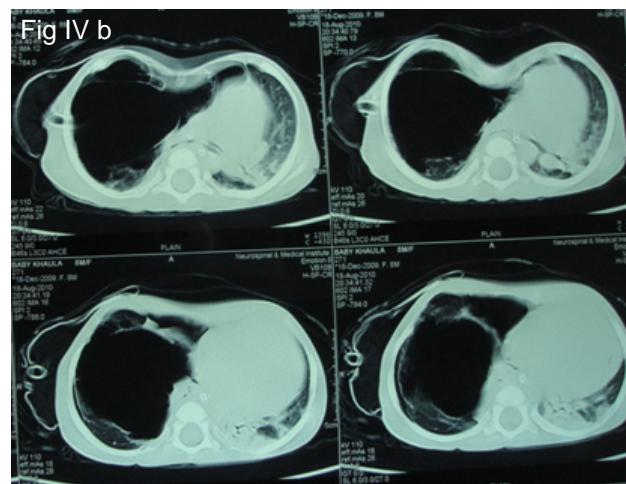


Fig IV b

Fig IV a & b: Congenital lung cyst in an eight month old baby in the right middle zone of lung field with chest wall deformity.

At thoracotomy adhesions were present between upper lobe of Right lung with the parietal pleura and chest wall. Right upper lobectomy was done in this case.

The only mortality in this series was an eight month old female baby weighing 5.0 kg. The patient had history of high grade fever, cough and respiratory distress for last five days. Similar complaints were reported off and on since birth and chest wall deformity was also noticeable. On x ray chest cyst was noted between right upper and middle lobes. Same findings were also present in x-ray chest done six months earlier but were missed. CT scan at admission provided greater details (Fig IV a & b). This patient was operated and cyst was excised. Postoperative course was not smooth. Patient remained on ventilator and later died.

**DISCUSSION:**

With the advances in technology cystic lesions of lung are increasingly reported on antenatal ultrasound. The subject has raised many controversies and

is still being debated. The overall incidence remains low. In a study from Thailand 25 cases of cystic lesions were reported over a period of eleven years.<sup>6</sup>

In current study twelve cases, both congenital and acquired were managed, including nine cysts of congenital origin in a two year period. A recent review article by Di Prima FA et al, where all reported cases of CCAM in PubMed and Cochrane database from 2003 to 2011 were analyzed, provides greater insight on CCAM.<sup>7</sup> Reviewing the literature authors quoted that Stocker et al initially described three types of CCAM and later on proposed new classification where five varieties were proposed in relation to anatomical origin / location as tracheal, bronchial, bronchiolar, bronchiolar/alveolar duct and alveolar/distal acinar. With more refinement in ultrasound, addition of Doppler and fetal MRI, Stocker classification is challenged and now CCAM are broadly divided either into cystic or solid variety.<sup>8</sup> However in our series no case was diagnosed in antenatal ultrasound. In fact there was not a single case of CCAM in this series. This may be a chance findings or the patten of CCAM may be

a chance findings or the patter of CCAM may be different from our region. This requires further studies where pooling of data from various hospital from Pakistan can be done to analyze the pattern.

The management of cystic lesions remains controversial as non operative management also works. Thus it is still not agreed upon if all cystic lesions of lung need surgery.<sup>9,10</sup> All of our patients presented in severe respiratory distress and did not show improvement on medical and supportive treatment. Surgery was done for the relief of symptoms. The policy of observation is appropriate in a set up where patients can be brought immediately into a hospital where facilities of ventilation and operation are available.

Congenital lobar emphysema was the most common congenital cystic lung lesion managed in this series. Its congenital origin is debated by some. Both intrinsic and extrinsic causes for overinflation of lung have been suggested.<sup>11</sup> This condition may become alarming when sudden trapping of air occurs in the lung during episode of infection. Emergency thoracotomy and resection of affected lobe is considered most appropriate treatment in life threatening situation. The anesthetic management and surgical approach are challenging. Gentle ventilation pre operatively helps in preventing overinflation.<sup>12</sup> Selective intubation of one lung with special precautions while inducing and maintaining anesthesia are reported in literature.<sup>13,14</sup> In this series three patients were operated in emergency because of deteriorating condition of the babies. Others were operated electively as their symptoms did not abate on medical management.

Pneumatocele is a cyst filled with air within lung parenchyma. Usually these are multiple and of variable sizes. These are not uncommon in neonates on artificial ventilation and usually resolve spontaneously.<sup>15</sup> They are more sinister when found in association with pneumonia and in older infants. At times these cysts do not disappear and have potential to worsen the condition of the patient and demands intervention. Minimal approaches have been described for decompression of the pneumatocele.<sup>16</sup> In this study both the patients with the pneumatoceles were operated and cysts laid open.

A case of bronchogenic cyst in this series was referred from another city in severe respiratory distress. This patient became symptomatic early in new born period though many of such cysts are not apparent till late in infancy and early childhood.<sup>17</sup> In

this patient cyst was more to the right of midline but but caused compression of left main bronchus. In this case lesion was approached from right thoracotomy and excised with great difficulty. Bronchogenic cysts can be present at unusual location with variable symptoms.<sup>18</sup> A single case of necrotizing pneumonia was managed. In this condition minimally invasive approach has been described but in index case upper lobe of the right lung was totally destroyed thus lobectomy was performed.<sup>19</sup>

#### CONCLUSIONS:

Cystic lesions of lung are not commonly seen. A high index of suspicion must be exercised in interpreting plain x ray chest in patients with respiratory distress. CT scan in stable patient must be acquired early to localize such pathologies. Early surgical consult in patients not responding to medical treatment, good anesthesia support and post operative care in ICU set up with ventilator facility, if needed, helps in salvaging these sick babies.

#### REFERENCES:

1. Sfakianaki AK, Copel J. Congenital cystic lesions of the lung: congenital cystic adenomatoid malformation and bronchopulmonary sequestration. *Rev Obstet Gynecol.* 2012; 5:85-93.
2. Fulghum H, Vasquez E. Congenital Cystic Adenomatoid Malformation: A Case Study. *Internet J Adv Nurs Pract.* 2002;5:2.
3. Durell J, Lakhoo K. Congenital cystic lesions of the lung. *Early Hum Develop.* 2014;90:935-9.
4. Kuroda T, Nishijima E, Maeda K, Fuchimoto Y, Hirobe S, Tazuke Y, et al. Clinical features of congenital cystic lung diseases: a report on a nationwide multicenter study in Japan. *Eur J Pediatr Surg.* 2015; 27:
5. Ierullo AM, Ganapathy R, Crowley S, Craxford L, Bhide A, Thilaganathan B. Neonatal outcome of antenatally diagnosed congenital cystic adenomatoid malformations. *Ultrasound Obstet Gynecol.* 2005; 26:150-3.
6. Karunasumetta C, Kuptarnond C, Prathanea S, Intanoo W, Wongbuddha C. Surgical outcomes for congenital lung malformations:

- 10 years experience at a single center. *J Med Assoc Thai.*2014;*97*:52-9.
7. Di Prima FA, Bellia A, Inclimona G, Grasso F, Teresa M, Cassaro MN. Antenatally diagnosed congenital cystic adenomatoid malformations (CCAM): Research review. *J Prenat Med.* 2012;*6*:22-30.
  8. Monni G, Paladini R, Ibba RM, Teodoro A, Zoppi MA, Lamberti A, et al. Prenatal ultrasound diagnosis of congenital cystic adenomatoid malformation of the lung: a report of 26 cases and review of the literature. *Ultrasound Obstet Gynecol.* 2000;*16*:159-62.
  9. Hermoso Torregrosa C, Moreno Medinilla E, Pérez Ruiz E, Caro Aguilera P, Pérez Frías FJ. [Congenital lobar hyperinflation: conservative management as an alternative therapy]. *An Pediatr (Barc).*2014;*81*:45-8.
  10. Ng C, Stanwell J, Burge DM, Stanton MP. Conservative management of antenatally diagnosed cystic lung malformations. *Arch Dis Child.* 2014;*99*:432-7.
  11. Idro RI, Kisémbó H, Mugisa D. Congenital lobar emphysema: a diagnostic challenge and cause of progressive respiratory distress in a 2 month-old infant. *Afr Health Sci.* 2002;*2*:121-3.
  12. Chandran-Mahaldar D, Kumar S, Balamurugan K, Raghuram AR, Krishnan R, Kannan. Congenital lobar emphysema. *Indian J Anaesth.* 2009;*53*:482-5.
  13. Prabhu M, Joseph TT. Congenital lobar emphysema: Challenges in diagnosis and ventilation. *Anesth Essays Res.* 2012;*6*: 203-6.
  14. Nandihalli MC, Thammaiah SH, Kotekar N, Putran PR. Congenital lobar emphysema: A modified approach to anesthetic management. *Indian J Crit Care Med.* 2015;*19*:47-9.
  15. Arora P, Kalra VK, Natarajan G. Pneumatoceles in infants in the neonatal intensive care unit: clinical characteristics and outcomes. *Am J Perinatol.* 2013;*30*: 689-94.
  16. Park TH, Kim JK. Nonsurgical management of an enlarging pneumatocele by fibrin sealant injection via pigtail catheter. *Pediatr Pulmonol.* 2015;*9*: doi: 10.1002/ppul.23311
  17. Vimala LR, Sathya RK, Lionel AP, Kishore JS, Navamani K. Unilateral obstructive emphysema in infancy due to mediastinal bronchogenic cyst - Diagnostic challenge and management. *J Clin Diagn Res.* 2015;*9*:3-5.
  18. Goswamy J, de Kruijf S, Humphrey G, Rothera MP, Bruce IA. Bronchogenic cysts as a cause of infantile stridor: case report and literature review. *J Laryngol Otol.* 2011;*125*:1094-7.
  19. Hoffer FA, Bloom DA, Colin AA, Fishman SJ. Lung abscess versus necrotizing pneumonia: implications for interventional therapy. *Pediatr Radiol.* 1999;*29*:87-91.