

# Bilateral superior vena cava with right superior vena cava draining into left atrium



Mohammed H. Alghamdi<sup>a,b,\*</sup>, Wafa Elfaki<sup>a</sup>, Fahad Al-Habshan<sup>b,c</sup>,  
Abdullah S. Aljarallah<sup>a</sup>

<sup>a</sup> King Fahad Cardiac Centre, King Saud University, Riyadh

<sup>b</sup> King Abdulaziz Medical City, Riyadh

<sup>c</sup> King Saud bin Abdulaziz University for Health Sciences, Riyadh

<sup>a,b,c</sup> Saudi Arabia

Anomalies of systemic venous return are extremely heterogeneous congenital malformations with variable ranges from completely normal physiology to severe forms of right to left shunting requiring surgical treatment. Anomalous drainage of a right-sided superior vena cava (SVC) to the left atrium (LA) is one of the rarest variants of systemic venous return anomalies, characterized by right-to-left shunt physiology and cyanosis. Here we report a 2 years old girl presented with cyanosis which was observed shortly after birth by her parents but not further investigated. She is otherwise active girl and with normal growth and development. Her clinical examination was unremarkable apart from mild clubbing of the fingers and low oxygen saturation of 88–90% in room air. Her ECG and chest X-ray were unremarkable. Echocardiography showed bilateral SVC connected by a small innominate vein. The right SVC drains directly into the LA while the left SVC drains into the right atrium (RA) via a dilated coronary sinus. There is a small superior sinus venosus type atrial septum defect (ASD) with left to right shunt. Also, there is partial anomalous pulmonary venous return with right upper and right middle pulmonary veins draining directly into the right SVC, which is connected to LA. The right lower pulmonary vein and left pulmonary veins drain directly to LA. The rest of her echocardiography demonstrated normal heart structures and function. This patient was referred for surgical correction, including baffling of the right SVC to the RA and closure of the ASD. We describe this case to highlight the importance of recognizing this rare anomalous systemic venous connection as one of the very rare causes of cyanosis in the pediatric age group as well as at older age.

© 2014 Production and hosting by Elsevier B.V. on behalf of King Saud University. This is an open access article under the CC BY-NC-ND license (<http://creativecommons.org/licenses/by-nc-nd/3.0/>).

**Keywords:** Superior vena cava, Left atrium, Sinus venosus type atrial septal defect, Congenital heart disease, Cyanosis

## Case report

Our patient is a two-year-old girl, the third child of healthy, non-consanguineous parents with no family history of congenital heart

disease (CHD). She was born at full term after an uncomplicated pregnancy and uneventful delivery. Her Apgar score was 8 at one minute and 9 at five minutes, and her birth weight was 2.2 kg. She was discharged after 24 h in good health.

**Disclosure:** Authors have nothing to disclose with regard to commercial support.

Received 30 May 2014; revised 30 August 2014; accepted 19 October 2014.  
Available online 28 October 2014

\* Corresponding author at: King Fahad Cardiac Centre, College of Medicine, King Saud University, PO Box 7805, Riyadh 11472, Saudi Arabia. Tel.: +966 11 4671609; fax: +966 11 4671232.

E-mail addresses: [mohalghamdi@ksu.edu.sa](mailto:mohalghamdi@ksu.edu.sa), [mhomry@yahoo.com](mailto:mhomry@yahoo.com) (M. H. Alghamdi).



1016–7315 © 2014 Production and hosting by Elsevier B.V. on behalf of King Saud University. This is an open access article under the CC BY-NC-ND license (<http://creativecommons.org/licenses/by-nc-nd/3.0/>).

Peer review under responsibility of King Saud University.

URL: [www.ksu.edu.sa](http://www.ksu.edu.sa)

<http://dx.doi.org/10.1016/j.jsha.2014.10.001>



P.O. Box 2925 Riyadh – 11461KSA

Tel: +966 1 2520088 ext 40151

Fax: +966 1 2520718

Email: [sha@sha.org.sa](mailto:sha@sha.org.sa)

URL: [www.sha.org.sa](http://www.sha.org.sa)



Production and hosting by Elsevier

There were no concerns, apart from circumoral cyanosis during episodes of crying that was noted by her parents but not fully investigated by medical health professionals. She had normal growth and development, and no history of recurrent chest infections. She presented to our pediatric emergency with acute history of fever and cough with unremarkable systemic review.

Her physical examination revealed stable vital signs, apart from low oxygen saturation via pulse oximetry (88–90% in room air). There were no dysmorphic features and no signs of respiratory distress. Her weight was 11.5 kg (50th percentile) and her height was 91 cm (75–95th percentile). Her cardiovascular and respiratory examination was unremarkable, apart from finger clubbing. All other examinations were unremarkable.

Laboratory investigation showed normal complete blood count with hemoglobin of 13.4 g/dl and hematocrit of 40 mg/dl with normal red blood cell indices. Chest X-ray depicted normal heart size, clear lung fields, and normal pulmonary vascular marking. Her renal and liver function tests were normal.

Echocardiography demonstrated situs solitus, levocardia, atrio-ventricular concordance, ventriculo-arterial concordance, and normally related great arteries. The bilateral superior vena cava (SVC) with left SVC drained via a dilated coronary sinus into the right atrium (RA) (Fig. 1) and right SVC drained into the left atrium (LA) which had inter-atrial communication with RA via a small restrictive sinus venosus type atrial septal defect (ASD), shunting from left to right (Fig. 2). Both SVCs were connected to a small bridging ‘innominate’ vein. The right upper and right middle pulmonary veins were partially anomalous and drained directly into the right SVC while the right lower and all left pulmonary veins drained normally to the LA. The inter-ventricular septum was intact. There was no inflow or outflow tract obstruction. Heart chambers were normal in size with good biventricular systolic function. The origins of both coronary arteries were normal. There was no pericardial effusion.

Cardiac computed tomography (CT) was performed to further delineate the anatomy of the pulmonary veins, and confirmed the above findings (Fig. 3).

The patient underwent cardiac surgery in which all of the above findings were also confirmed, and the anomalous right-sided pulmonary veins were baffled to the LA using autologous pericardial patch and the right SVC was repositioned to drain directly into the RA. To this end, the junction

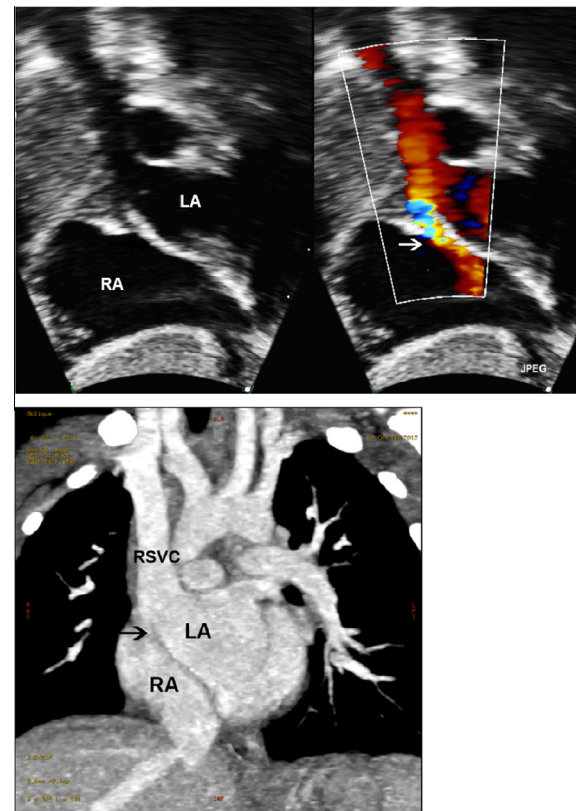


Figure 1. Two-dimensional (2D) echocardiography (upper left image) with Color Doppler Flow (upper right image) from subcostal views in comparison with cardiac CT findings at same plane (lower image): The right SVC is seen draining into left atrium with a small sinus venosus type ASD (arrow). LA indicates left atrium; RA, right atrium; RSVC, right superior vena cava.

between the right SVC and the RA was augmented with another smaller patch.

The patient's post-operative echocardiography showed no residual ASD and unobstructed right-sided pulmonary venous return to the LA. The right SVC drained adequately into the RA with only mild flow acceleration at the junction site (estimated mean gradient of 4–5 mmHg by Doppler flow assessment) but with biphasic flow.

One-year follow-up showed a well-looking child with oxygen saturation of 98% in room air. Her echocardiographic findings were similar to post-operative findings.

## Discussion

Drainage of the right SVC to the LA is an exceedingly rare congenital malformation of systemic veins [1]. In a previously published case report, Van Praagh and colleagues were able to identify 18 cases of LA drainage of the right SVC, and an additional seven cases of biatrial

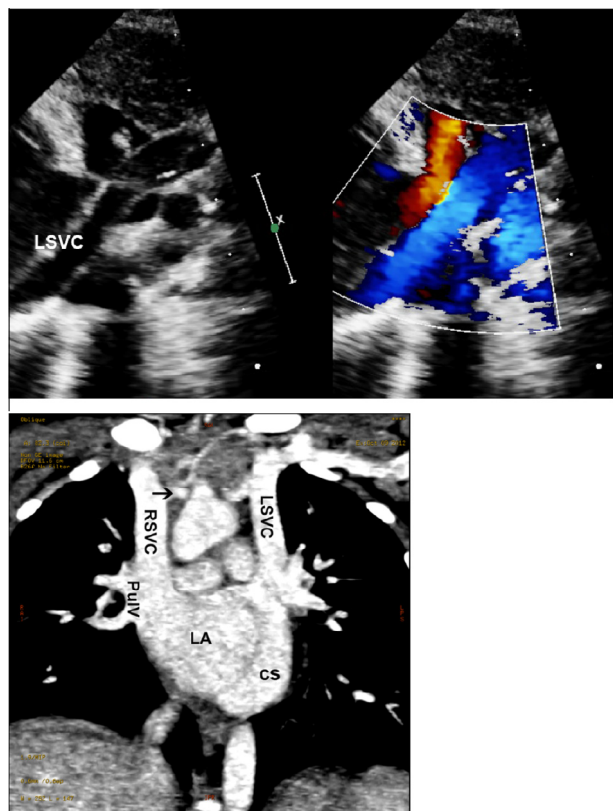


Figure 2. 2D echocardiography (upper left image) with CFD (upper right image) from suprasternal view in comparison with cardiac CT findings at same plane (lower image): The left superior vena cava is seen draining into the coronary sinus. Both SVCs are connected to a small innominate vein (arrow). CS indicates coronary sinus; LA, left atrium; LSVC, left superior vena cava; PulV, pulmonary vein; RSVC, right superior vena cava.

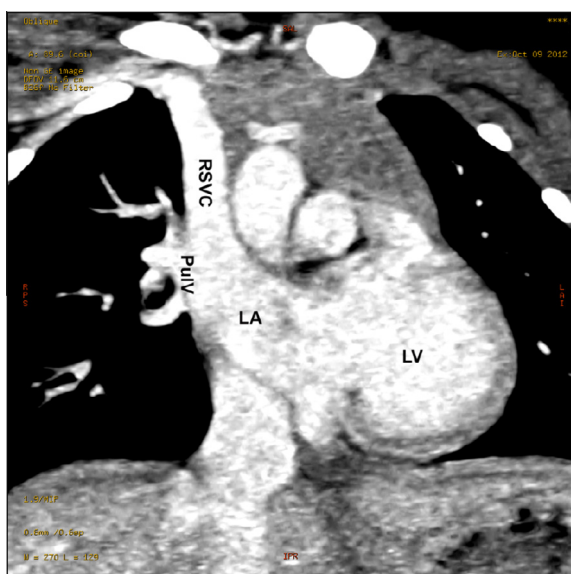


Figure 3. Cardiac CT showing anomalous drainage of right upper and right middle pulmonary veins into right superior vena cava. LA indicates left atrium; LV, left ventricle; PulV, pulmonary vein; RSVC, right superior vena cava.

drainage of right SVC in viscera-atrial situs solitus [2]. Another 17 cases have since been reported with similar diagnoses. The majority of these cases were identified in anatomically normal hearts apart from findings such as persistent left SVC, sinus venosus atrial septal defect and partial anomalous drainage of the right upper pulmonary veins (RUPV) into the right SVC, all of which are not infrequently associated with this condition. Anatomically, the anterior wall of RUPV is ‘fused’ with the posterior wall of the right SVC close to its junction with the RA. Deficiency in this common wall shared by both structures appears to be the most likely explanation of this malformation [2]. Our patient had a connection between right SVC and RUPV at the level of the right SVC before entering the LA. The only communication with the RA was through a small sinus venosus type ASD.

Sinus venosus ASD causes left-to-right shunt, increases pulmonary to systemic blood flow, and does not cause cyanosis. In our patient, the drainage of right SVC into the left atrium added another right-to-left shunt which was greater than the shunt caused by the small sinus venosus ASD. Therefore, the net shunt physiology was right-to-left with diminished pulmonary to systemic blood flow, leading to cyanosis in our patient [3].

Despite this small inter-atrial communication, our patient had minimal clinical symptoms except for mild cyanosis. Most likely, this is explained by the presence of the bridging vein connecting the right SVC to the left SVC, which is the relatively larger systemic upper vein.

Although extremely rare, this anomaly, if left untreated, may cause serious complications such as fatal brain abscess [4–7]. When diagnosed accurately, it can be treated surgically with excellent short-term results similar to the follow-up findings in our patient [8]. However, long-term follow up is lacking.

A major goal of this case report is to highlight the importance of recognizing this infrequent anomalous systemic venous connection as one of the very rare causes of cyanosis in the pediatric age group as well as at an older age.

We also report this case to demonstrate and confirm the persisting importance of using pulse oximetry in the evaluation of pediatric patients. With pulse oximetry screening before discharge becoming the standard of care on the detection of critical CHD in newborns [9–11], the finding of a borderline oxygen saturation needs full medical work-up, including a thorough echocardiography study.

## Acknowledgments

Authors are thankful to Prof. Mesud Yelbuz from King Abdulaziz Medical City, Riyadh, Saudi Arabia, for his insight in reviewing and revising the content of this manuscript.

## References

- [1] Gorenflo M, Sebening C, Ulmer HE. Anomalous connection of the right superior caval vein to the morphologically left atrium. *Cardiol Young* 2006;16(2):184–6.
- [2] Van Praagh S, Geva T, Lock JE, Nido PJ, Vance MS, Van Praagh R. Batrial or left atrial drainage of the right superior vena cava: anatomic, morphogenetic, and surgical considerations—report of three new cases and literature review. *Pediatr Cardiol* 2003;24(4):350–63.
- [3] Shariat M, Grosse-Wortmann L, Yoo SJ, Seed M, Honjo O. Normal drainage, abnormal connection: partial anomalous pulmonary venous connection and sinus venosus atrial septal defect with a net right-to-left shunt. *World J Pediatr Congenit Heart Surg* 2012;3(4):508–10.
- [4] Park HM, Summerer MH, Preuss K, Armstrong WF, Mahomed Y, Hamilton DJ. Anomalous drainage of the right superior vena cava into the left atrium. *J Am Coll Cardiol* 1983;2(2):358–62.
- [5] Nazem A, Sell JE. Closed technique for repair of right superior vena cava draining to left atrium. *Ann Thorac Surg* 1993;55(6):1568–70.
- [6] King RE, Plotnick GD. Isolated right superior vena cava into the left atrium detected by contrast echocardiography. *Am Heart J* 1991;122(2):583–6.
- [7] Schick Jr EC, Lekakis J, Rothendler JA, Ryan TJ. Persistent left superior vena cava and right superior vena cava drainage into the left atrium without arterial hypoxemia. *J Am Coll Cardiol* 1985;5(2 Pt. 1):374–8.
- [8] Oppido G, Pace Napoleone C, Turci S, Giardini A, Formigari R, Angeli E, et al. Right superior vena cava draining in the left atrium: anatomical, embryological, and surgical considerations. *Ann Thorac Surg* 2006;81(6):2313–5.
- [9] de-Wahl Granelli A, Wennergren M, Sandberg K, Mellander M, Bejlum C, Inganäs L, et al. Impact of pulse oximetry screening on the detection of duct dependent congenital heart disease: a Swedish prospective screening study in 39,821 newborns. *BMJ* 2009. 338:a3037.
- [10] Mahle WT, Newburger JW, Matherne GP, Smith FC, Hoke TR, Koppel R, et al. Role of pulse oximetry in examining newborns for congenital heart disease: a scientific statement from the AHA and AAP. *Pediatrics* 2009;124(2):823–36.
- [11] Thangaratinam S, Brown K, Zamora J, Khan KS, Ewer AK. Pulse oximetry screening for critical congenital heart defects in asymptomatic newborn babies: a systematic review and meta-analysis. *Lancet* 2012;379(9835):2459–64.