

Case Report

A Case of Temporal Arteritis Due to Oral Cavity Lesion of Tuberculosis

M. Rostami MD*, Z. Emami**

ABSTRACT

Oral lesions of TB have frequently been reported but its probable association with arteritis has rarely been noted. A 57 year old woman is presented here with chronic headache associated with oral lesion of TB.

Keywords: Headache, Arteritis, Temporal Arteritis, Tuberculosis

Tuberculosis may involve anywhere in the body including skin and mucosa. Physicians facing benign skin or mucosal lesions which are resistant to conventional medical treatments should bear in mind that it is likely a case of TB. The clinical picture of all cutaneous mycobacterial infections including tuberculosis is highly variable. Any unexplained skin lesion, especially if it has nodular, ulcerative or papulonecrotic components may be due to tuberculosis^{1, 2}. Oral lesions of TB have frequently been reported³⁻⁵ but its probable association with arteritis has rarely been noted^{6, 7}. We believe that the presented case might be the second one in the series reported worldwide.

Case Report

The patient was a 57 year old Isfahani (Iran) woman. She noticed a lesion in her palate with pain and white discharge since 4 March 2002. She received nonspecific treatment and underwent diagnostic work up for two consecutive months. During this period, she started profuse sweating and lost 5 kg weight but no fever was ever detected. She had a past history of headache during the previous two years and biopsy proved the diagnosis of temporal arteritis. She received corticosteroid for that but no response achieved during treatment. Physical examination revealed a round nodular lesion 1 by 1.5 cm with irregular borders (figure 1) located right side of midline on her soft palate. No adenopathy was found. Laboratory investigations

except for an ESR of 40 mm/hr were normal. Tuberculin skin test was negative. She showed no response to prednisolone and her soft palate lesion was growing up. In the biopsy of oral lesion caseating necrosis including multinucleated giant cells and granuloma compatible with tuberculosis were seen. Culture demonstrated Mycobacterium tuberculosis. Chest radiography was within normal limits and three samples of sputum were negative for acid fast bacilli.

Discussion

Temporal arteritis occurs almost exclusively in individuals older than 55 years and its associated symptoms are quite sensitive to glucocorticoid therapy⁸. In the present case lack of response to glucocorticoid made it an unusual form. Iden et al² reported a case of papulonecrotic tuberculoid that eruption in it flared whenever the patient received low doses of prednisone to control symptoms of temporal arteritis. A cervical lymph node biopsy demonstrated acid fast bacilli, and then growth of *M. Bovis* confirmed the diagnosis and symptoms completely cleared with antituberculous therapy². This is the only report which matches with our case in a full search of medical literature but the author had no intention to denote the association of the two diseases. However, many other aspects of associated arterial complications due to neighboring lesions of TB have been reported. Kilani et al⁹

*Assistant Professor, Department of Infectious diseases, Isfahan University of Medical Sciences, Isfahan, Iran.

**Infectious diseases specialist .Physician in charge of tuberculosis in Molahadi Sabzevari center, Isfahan, Iran.

Correspondence to: Dr Mojtaba Rostami, Al-Zahra Medical Center, Isfahn, Iran.

reported infarction resulted from arterial englobement or embolus, which involved the area of middle cerebral artery in 12 cases of TB meningitis. Also Shigemitsu et al¹⁰ reported an unusual case of tuberculous pseudoaneurysm of the ascending aorta which developed 7 months after the onset of multiple intracranial tuberculoma in a 59 year old man. A case of TB meningitis and an intraventricular hemorrhage secondary to a ruptured left posterior inferior cerebellar artery mycotic aneurysm has been reported by Griffiths et al¹¹. Furthermore Kolawole et al⁶ described four cases of vasculitis in different vessels next to the tuberculous foci and suggested that in cases of aortitis and arteritis tuberculosis must be ruled out as an

etiologic cause. Sharma et al⁷ reported autopsy findings of 10 patients who died of Takayasu arteritis and four of them had associated tuberculosis. Frances et al¹² reported another case of tuberculosis associated Takayasu arteritis¹². We think that these associations has to be considered. False-negative tuberculin reactions, though uncommon in otherwise healthy patients with tuberculosis, occur in at least 20% of all persons with known active tuberculosis¹³ but in our case, negative tuberculin test can be attributed to corticosteroid therapy. We need to suggest that any case of unusual arteritis deserves to be evaluated for tuberculosis.

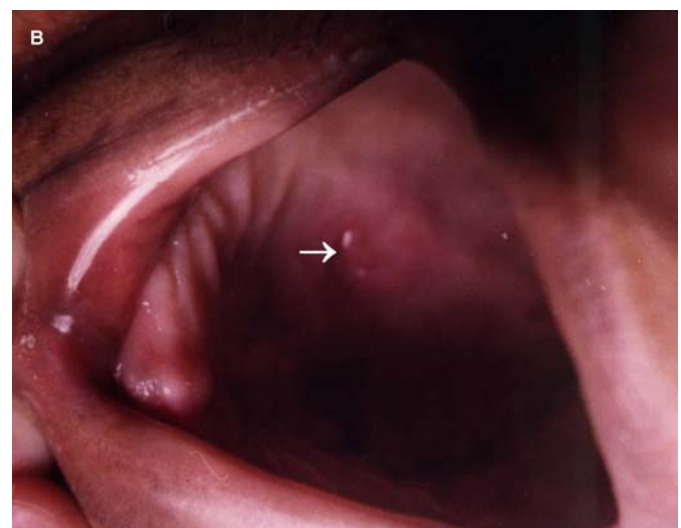
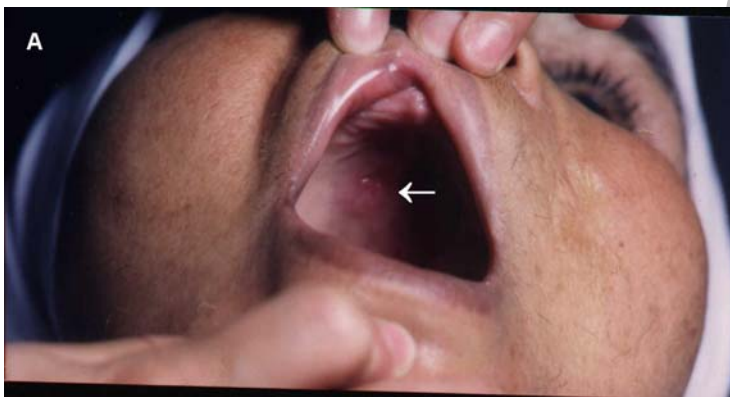

Figure 1. A: a round nodular lesion 1 by 1.5 cm with irregular borders located right side of midline on the soft palate. B: Zoomed view of the lesion

References

1. Rohatgi PK, Palazzolo JV, Saini NB. Acute miliary tuberculosis of the skin in acquired immunodeficiency syndrome. *J Am Acad Dermatol* 1992; 26: 356-359
2. Iden DL, Rogers RS, Schroeter AL. Papulonecrotic tuberculoid secondary to *Mycobacterium bovis*. *Arch Dermatol* 1978 Apr; 114(4): 564-6.
3. Magina S, Lisboa C, Resende C, Azevedo F, Amado F, Cardoso V, et al. Tuberculosis in a child presenting as asymptomatic oropharyngeal and laryngeal lesions. *Pediatr Dermatol* 2003 Sep-Oct; 20(5): 429-31.
4. Nagabhushana D, Balaji Rao B, Rajeshwari A, Mamatha GP. Oral tuberculosis: a case report. *J Indian Soc Pedod Prev Dent* 2003 Mar; 21(1): 16-18.
5. Galli J, Nardi C, Contucci AM, Cadoni G, Lauriola L, Fantoni M [Review]. Atypical isolated epiglottic tuberculosis: a case report and a review of the literature. *Am J Otolaryngol* 2002 Jul-Aug; 23(4): 237-40.
6. Kolawole TM, Onadeko BO. Vascular lesions in tuberculosis. *Diagn Imaging* 1980; 49(6): 303-10.
7. Sharma BK, Jain S, Radotra BD. An autopsy study of Takayasu arteritis in India. *Int J Cardiol* 1998 Oct 1; 66 Suppl 1:S85-90; discussion S91.
8. Hunder GG. Giant cell arteritis and polymyalgia rheumatica. In: *Textbook of Rheumatology*, 6th ed, Kelly, WN, Harris, ED, Ruddy, S (Eds), WB Saunders Company, Philadelphia, 2001.
9. Kilani B, Ammari L, Tiouiri H, Goubontini A, Kanoun F, Zouiten F, et al. Neuroradiologic manifestations of central nervous system tuberculosis in 122 adults *Rev Med Interne* 2003 Feb; 24(2): 86-96.
10. Shigemitsu O, Hadama T, Miyamoto S, Anai H, Sako H. Tuberculous pseudoaneurysm of the ascending aorta associated with intracranial tuberculoma. *J Cardiovasc Surg (Torino)* 2002 Feb; 43(1): 59-62.
11. Griffiths SJ, Sgouros S, James G, John P. Intraventricular haemorrhage due to ruptured posterior inferior cerebellar artery aneurysm in tuberculous meningitis. *Childs Nerv Syst* 2000 Dec; 16(12): 872-4.
12. Frances C, Boisnic S, Blety O, Dallot A, Thomas D, Kieffer E, et al. Cutaneous manifestations of Takayasu arteritis: a retrospective study of 80 cases. *Dermatologica* 1990; 181(4): 266-72.
13. Nash DR, Douglass JE. Anergy in active pulmonary tuberculosis: A comparison between positive and negative reactors and an evaluation of 5 TU and 250 TU skin test doses. *Chest* 1980; 77: 32-37.