

Original Article

The Normal Position of Umbilicus in the Newborn: An Aid to Improve Cosmetic Result in Exomphalos Major

H. Davari MD*, M. Nazem MD*

ABSTRACT

Background: Position of umbilicus is an important esthetic landmark and its absence or deformity may be associated with poor self-image. In abdominoplasty, the creation of a normal-looking, well shaped and sufficiently deep umbilicus on a normal position seems essential. The aim of this study was to determine the normal position of umbilicus and hence to improve the cosmetic result of exomphalos major repair.

Methods: In a cross-sectional study the position of umbilicus was determined in a random sample of 200 healthy and normal neonates (107 boys and 93 girls) who were born in Isfahan University hospitals from Oct. 2002 till Mar. 2003, with respect to the xiphisternum and pubis.

Results: The normal umbilical position was 59.3 ± 5.2 percent of the way from the inferior border of xiphisternum to the superior border of the pubis in the midline and it was independent of gender and neonatal growth indices.

Conclusions: Recent years have witnessed major improvements in the survival of newborns with exomphalocoele. The primary repair of the abdominal wall with umbilicoplasty is generally considered the treatment of choice, and the cosmetic appearance of the navel becomes increasingly important as children grow older. In repair of exomphalos major, the most esthetically pleasing result is obtained if the umbilicus is placed 59.3% of the way from the xiphisternum to the pubis.

Key Words: Umbilicus, Exomphalos, Neonate, Umbilicoplasty, Isfahan

Umbilicus is a round dermal projection on the center of anterior abdominal wall. Position of umbilicus is a significant factor in making the abdomen esthetically pleasing, so its loss or deformity may be a cause of psychological distress in future¹. Umbilicus lies over the umbilical ring, which is the last part of abdomen closed in fetus or after birth.

In some conditions such as omphalocele, gastroschisis, bladder or cloacal extrophy, prune-belly syndrome and umbilical hernia^{2,3} this defect is not closed and may be too large and change the appearance and position of umbilicus (Fig.1,A). The defect in babies with an exomphalos may extend from a few centimeters below the xiphisternum to a few centimeters above the pubis. It may therefore be difficult to select

the most appropriate segment of abdominal skin from the margin of defect to create an umbilicus in a normal position when performing surgery. This may be particularly difficult if a staged silo reduction or mesh closure has been used and the anatomy distorted at the time of definitive closure⁴ (Fig.1, B). While repairing these cases and other conditions such as abdominal wall trauma, burning etc. in which the appearance and location of umbilicus have already been destroyed (Fig.2, A), the reconstruction of a cosmetically designed umbilicus seems essential. So far, there has been no good evidence to suggest where it exactly should be placed on the abdominal wall^{1,2}. We could find just one similar study done before to help in this regard⁵.

* Department of Pediatric Surgery, Al-Zahra University hospital, Isfahan University of Medical Sciences, Iran.

As there are anatomic differences among different nations and races, this study was done for the first time in Isfahan, Iran. We tried to find the best position of umbilicus with respect to the xiphisternum and pubis in normal newborns in Isfahan city.

Materials and Methods

This cross-sectional study was done on a random sample of 200 newborn babies of up to 15 days old (107 boys and 93 girls), who were born in Isfahan University's medical centers. Gestational age, birth weight, length, body mass index, and sex were recorded. Our inclusion criteria were as follows:

Healthy and normal neonates with 1-15 days of age, gestational age between 37-42 weeks, birth weight 2.5-4 kg, height 45-55cm, and head circumference 32-36 cm⁶. The babies who were not in the normal range or had any specific abdominal wall abnormalities were excluded. Distances between the lower border of xiphisternum and the center of umbilicus (XU), and also from the lower border of xiphisternum to the upper border of pubis (XP) were measured while the babies were lying in a supine position. All measurements were done by the same surgeon with standard tools for all newborns. Results were analyzed with SPSS-9 using t-test and Pearson-correlation test.

Results

The mean and standard deviation (SD) of the distance between the xiphisternum and the upper border of the pubis (XP) was 10.7 ± 1.2 cm in boys, and 10.9 ± 1.4 cm in girls ($P > 0.05$). The mean and SD of the distance between the xiphisternum and the umbilicus center (XU) was 6.4 ± 1.0 cm in boys, and 6.5 ± 1.1 cm in girls ($P > 0.05$), and 6.5 ± 1.1 cm for both. The ratio of the XU to XP was $59.2 \pm 5.3\%$ in boys and $59.3 \pm 5.1\%$

in girls ($P = 0.87$) and $59.3 \pm 5.5\%$ for both. (Table 1).

The mean values and SD of height, weight, head circumference, BMI (Body Mass Index) and neonates' gestational age in boys and girls were 48.7 ± 2.5 and 48.6 ± 2.4 cm ($P = 0.8$), 3.0 ± 0.4 and 2.8 ± 0.4 cm ($P = 0.029$), 33.9 ± 1.5 and 33.5 ± 1.8 cm ($P = 0.14$), 12.7 ± 1.4 and 12.2 ± 1.4 ($P = 0.015$), 38.5 ± 4.2 and 38.9 ± 1.5 weeks ($P > 0.05$), respectively.

Discussion

The position of umbilicus in newborns was 59.3 ± 5.2 (54.1-64.5) percent of the way from the lower border of the xiphisternum to the upper border of pubis (Figure 1) and is independent of the variables measured in this study (in all cases $P > 0.5$ and $r < 0.1$). Therefore, according to this study, this is where the new umbilicus should be made while repairing exomphalos major and in abdominoplasty, to get the most esthetically pleasing result (Fig.2B).

During the past 25 years, the mortality rate of newborns with omphalocele and gastroschisis has significantly decreased while survival and outcome of treatment have remarkably improved due to development in neonatal care, surgical techniques and nursing⁷. As the scar is the only persistent blemish in later life, the creation of the navel is an essential aspect of this treatment, and umbilicus is an important esthetic landmark and its absence or deformity may be associated with poor self-image. Absence of umbilicus usually occurs after treatment of exomphalos and after abdominoplasty and umbilical hernia repair^{2,1} and the cosmetic results are often limited in patients with exomphalos major¹. There have been several reports on abdominoplasty and reconstruction of a normal-looking, well shaped and sufficiently deep umbilicus in neonates with exomphalos and prun-belly syndrome^{8,4,10},

but there are few reports on the exact location of the neoumbilicus ^{2,1}.

We found just one study in the literature on the normal position of umbilicus. It was done on 50 neonates in England and the normal position of umbilicus was about 60% of the way from xiphisternum to pubis and was independent of variables mentioned above in our study ⁵.

There were a few reports on the approximate position of normal umbilicus in

plastic surgery references. In one of them, it is notified that umbilicus is located below the abdominal midpoint, between the xiphoid process and symphysis pubis. Situated over the disc between the third and fourth vertebrae, it is located approximately 2 to 4 cm above the line joining the crests of iliac and its position may vary considerably with the type of individual habitus ^{2,3}.

Table 1. Mean xiphisternum and the upper border of the pubis (XP), xiphisternum and the center of umbilicus (XU) and $\frac{XU}{XP}$ % in boys and girls

Gender		Mean \pm SD	Minimum	Maximum
Girl	XP	10.9 \pm 1.35	8	14
	XU	6.49 \pm 1.04	4.9	9
	$\frac{XU}{XP}$ %	59.34 \pm 5.1	50	69.23
Boy	XP	10.7 \pm 1.23	8	14
	XU	6.39 \pm 1.014	4.6	9.5
	$\frac{XU}{XP}$ %	59.22 \pm 5.34	50	80
Total	XP	10.85 \pm 1.2	8	14
	XU	6.44 \pm 1.03	4.5	9.5
	$\frac{XU}{XP}$ %	59.28 \pm 5.2	50	80

P XU > 0.05

P XP > 0.05

P $\frac{XU}{XP}$ % > 0.05

Acknowledgment

Authors would like to express their thanks to Dr. A. Yazdani for his efforts and cooperation.

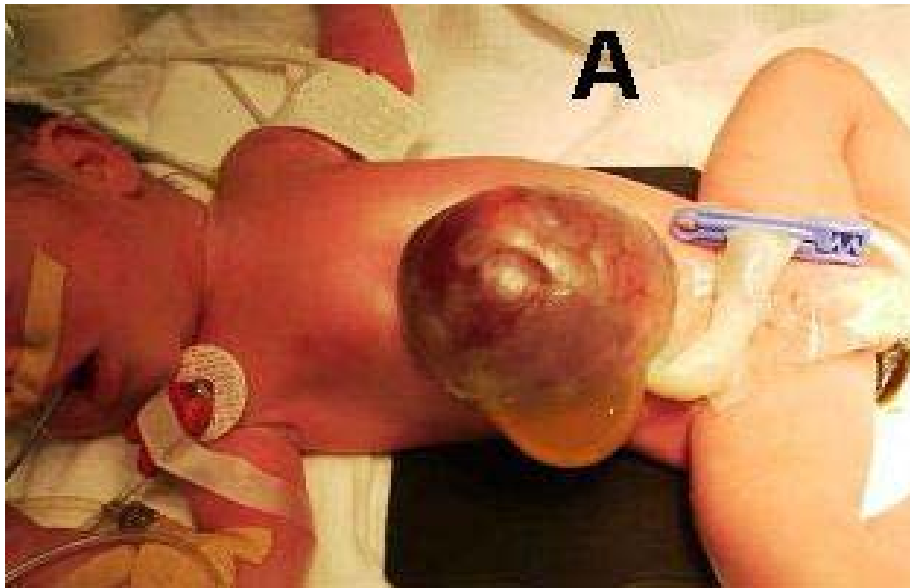

Fig 1, A.

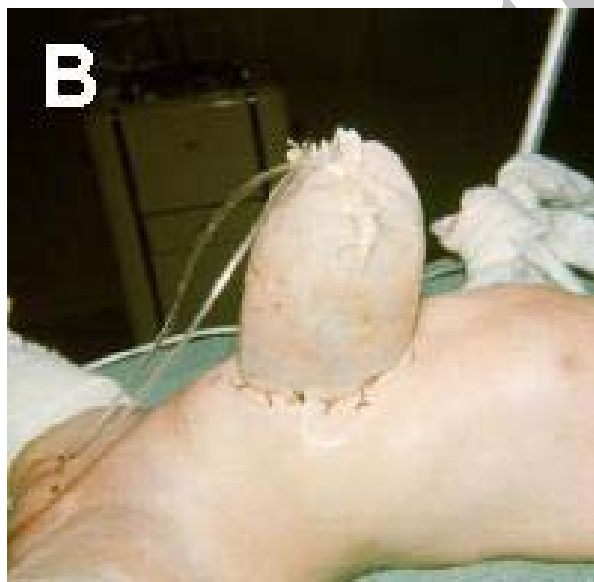


Fig 1, B.

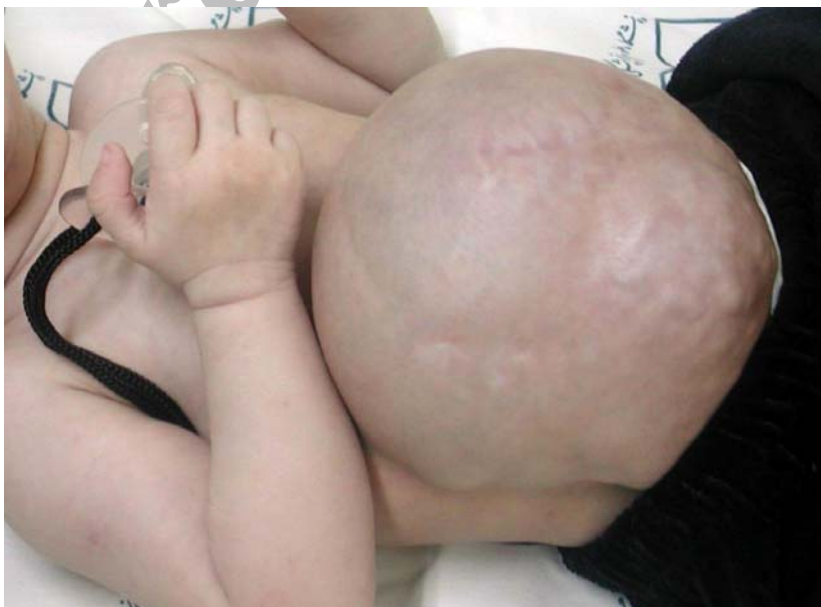

Fig 2, A.

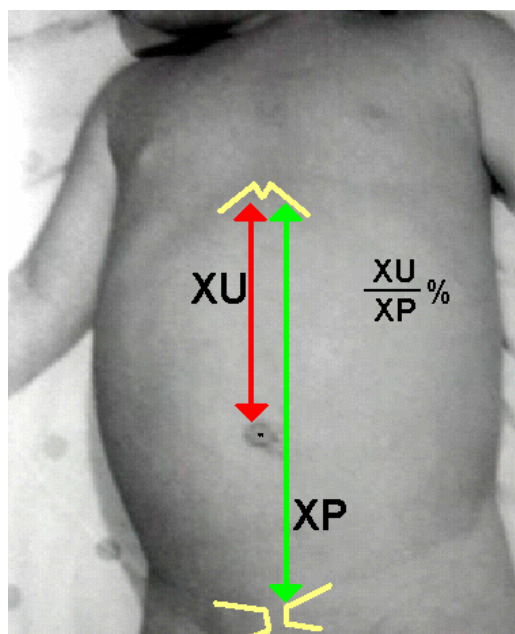
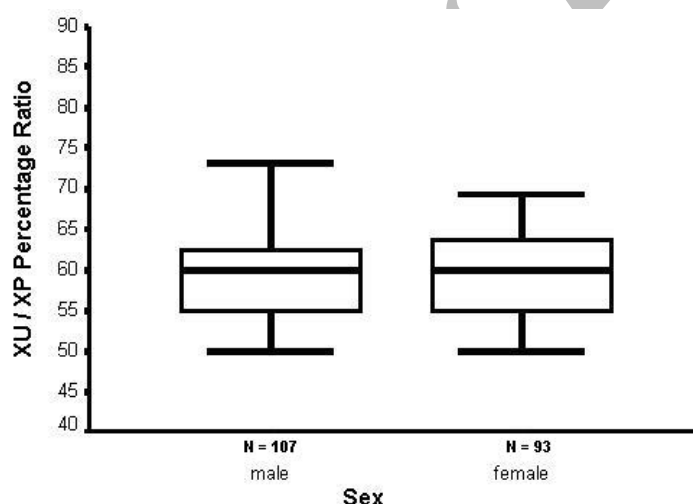


Fig 2, B.



References

- 1- Park S, Hata Y, Ito O, Tokioka K, Kagawa K. Umbilical reconstruction after repair of omphalocele and gastroschisis. *Plast Reconstr Surg* 1999 ;104(1):204-7
- 2- Matarasso A. Abdominoplasty. In: Bahman G, Wilkins EG, Editors. *Plastic Surgery*. St. Louis: Mosby, 2000; Vol. 5, pp2783-2821
- 3- Gaines BA, Holcomb GW, Neblett WW. Gastroschisis and omphalocele. In: Ashcraft KW, editor. *Pediatric Surgery*, Third ed. W.B Saunders 2000; pp639-49
- 4- Lee SL, DuBios JJ, Greenholz SK, Huffman SG. Advancement flap umbilicoplasty after abdominal wall closure: Postoperative results compared with normal umbilical anatomy. *J Pediatr Surg* 2001 ; 36(8):1168-70
- 5- Williams AM, Brain JL. The normal position of the umbilicus in the newborn: an aid to improving the cosmetic result in exomphalos major. *J Pediatr Surg* 2001 l; 36(7): 1045-6
- 6- Behrman RE, Kliegman RM, Tenson HB. *Nelson textbook of pediatrics*. 16th ed. Philadelphia W.B. Saunders 2000; pp30-33
- 7- Weber TR, Au-fliegner M, Downard CD, Fishman ST. Abdominal wall defects. *Curr Opin Pediatr* 2002 ; 14(4):491-7
- 8- Friogo E, Rettinger- Schimmerl S, Rokitansky AM. Umbilicoplasty in neonates with primary omphalocele closure. *Pediatr Surg Int* 1999; 15(7): 523-4
- 9- Pinto PA, Stock JA, Hanna MK. Result of umbilicoplasty for bladder exstrophy. *J-Urol*. 2000 ; 164(6): 2055-7
- 10- Bukowski TP, Smith CA. Monfort abdominoplasty with neoumbilical modification. *J Urol*. 2000; 164(5): 1711-8