

A PROSPECTIVE STUDY OF PENETRATING CHEST TRAUMA AND EVALUATION OF ROLE OF THORACOTOMY

Mohammad Saleem Khan, Aamir Bilal

*Department of Cardiothoracic Surgery,
Postgraduate Medical Institute,
Lady Reading Hospital, Peshawar.*

ABSTRACT

Objective: To evaluate the different lines of management of penetrating chest trauma and determine the indications of thoracotomy in patients sustaining penetrating chest trauma.

Material and Methods: A prospective study was conducted at the Department of Cardiothoracic Surgery; Postgraduate Medical Institute Lady Reading Hospital, Peshawar from May 1996 to April 1997.

One hundred and twenty patients presenting with penetrating chest trauma were included. Those patients who had blunt chest trauma or associated injuries to the spine, abdominal viscera, head and neck and extremities were excluded from the study. All these patients were resuscitated and evaluated on arrival to the hospital. The patients were individualized on the basis of clinical parameters and grouped as stable and unstable. After haemodynamic stabilization decision regarding surgical intervention was made on the basis of clinical feature and radiological examination. In this manner patient were grouped as those requiring conservative management or surgical intervention.

Results: Out of 120 patients, conservative management was adopted in 12 patients (10%). Thoracostomy tube was placed in 110 patients (91.66%). Only 12 patients (10%) underwent early Thoracotomy, 3 for massive hemothorax and lung laceration, 4 for evacuation of clotted hemothorax, 2 for removal of foreign body (bullet) in the lung parenchyma, and one each for empyema, chylothorax and diaphragmatic laceration. Two patients out of three died after emergency thoracotomy. Over all mortality was 2.5% (3 patient out of 110).

Conclusion: Early thoracotomy has a definite role both in emergency situations and for various complications resulting from penetrating chest

trauma. Adequate initial line of management of penetrating chest injuries will minimize life threatening complications.

Key words: Chest trauma penetrating thoracotomy complication.

INTRODUCTION

The problem of dealing with penetrating chest injuries is one of the oldest. Hippocrates stated that all wounds of the heart were deadly. Pausanias in 1846 very poetically described the venting of pericardial tamponade (Wall et al; 1996)¹. In 1906 Spandaro described left anterolateral thoracotomy; today the incision of choice for emergency access to the heart and left hemithoracic cavity. Prior to the 20th century the mortality rate from penetrating chest trauma was more than 50%. Over the last century there has been considerable improvement in management due to availability of positive pressure ventilation, proliferation and introduction of broad spectrum antibiotics; advent of radiologic techniques, introduction of emergency thoracotomy and the development of post operative surgical intensive care units (Richardson et al; 1996)².

Penetrating chest injuries continue to be associated with high mortality reflecting the importance of intra thoracic viscera which are at risk following penetrating chest trauma. Management ranges from observation, tube thoracostomy, to early Thoracotomy.³

Trauma deaths result from chest injuries in 25% of cases.³ Penetrating chest injury occurs when there is communication between intra thoracic viscera and the environment.¹ After initial clinical evaluation, the insertion of tube thoracostomy, monitoring of blood loss, and evaluation of chest roentgenograms, one should be able to select 10-15% of patients who require urgent thoracotomy.^{4,5,6} The main indications for

emergency thoracotomy are life threatening conditions which must be diagnosed or excluded. These include massive hemothorax, cardiac tamponade, and tracheobronchial injuries.⁷ Emergency thoracotomy in massive hemothorax is considered in patients having initial output in excess of 1500 ml after chest intubation or more than 200 ml per hour for consecutive three hours, accompanied with hemodynamic compromise.^{8,9}

Almost all patients who reach hospital alive should survive if managed appropriately. Early recognition and timely treatment of various life threatening injury; better resuscitative measures, perioperative care and skillful surgical procedures can significantly affect the outcome of these patients.¹⁰ Moreover the key to improved outcome lies in rapid transportation to adequate emergency care by the quickest available measures.¹¹

There is still a group of patients who will need early surgical intervention either for missed injuries or complications. These include clotted hemothorax, chylothorax, diaphragmatic tear and empyema.^{12,13}

The purpose of this study was to analyze and evaluate the role of thoracotomy both in emergent situations and for later complications.

MATERIAL AND METHODS

A prospective study was carried out from May 1996 to April 1997 at Cardiothoracic Surgery Department Lady Reading Hospital Peshawar.

The aim was to analyze the management, to know the role of early thoracotomy, and

outcome in our circumstances. This study included only patients having penetrating chest injury, irrespective of age and sex of individual, but excluded those with blunt chest injuries, or associated injuries to head and neck, abdomen or extremities.

All the patients were admitted through accident and emergency department at Lady Reading Hospital Peshawar and managed in the general ward and intensive care unit of cardiothoracic department.

All these patients were resuscitated and evaluated in the form of primary and secondary survey. Every hemodynamically stable patient was exposed to radiological examination of the chest which frequently showed the nature of injury such as hemothorax or hemopneumothorax. In 8 patients the site of injury, trajectory of the missile and hemodynamic condition guided us to do echo cardiography to exclude cardiac injuries.

The initial line of treatment of every symptomatic patient due to pleural collection was in the form of chest intubation. They were closely monitored, recording their vital signs (Pulse, Blood Pressure and respiratory rate), and the drainage in the tube along with the clinical condition was used as a guide line, whether to observe the patient or proceed to thoracotomy.

Thoracotomy was indicated in 12 cases. Three patients were diagnosed as massive hemothorax and underwent emergency thoracotomy. After endotracheal intubation and establishment of large bore venous line, left anterolateral thoracotomy was performed through the fifth intercostal space for suspicion of cardiac tamponade while posterolateral thoracotomy through sixth intercostal space was performed for lacerated lung, tracheobronchial or esophageal injuries. Pleural cavity was evacuated of collection and the nature of injury identified. Prophylactic antibiotics were administered.

The cause of massive hemothorax continuous bleeding were usually intercostals vessels injury or pulmonary parenchymal bleeding and air leak. Hemostasis was secured with over running sutures.

Four cases were diagnosed as clotted hemothorax and confirmed by CT Scans; evacuation of clotted hemothorax and decortications were done. Two symptomatic patients underwent thoracotomy for removal of foreign body (bullet) in the lung parenchyma. Diaphragmatic injury was suspected in those who had penetrating chest trauma in close proximity to the diaphragm. Proximity to the diaphragm was assessed when the penetrating injury was located at the level of fourth inter costal space anteriorly and sixth rib posterolaterally. One case underwent thoracotomy for diaphragmatic injury, one each for chylothorax, empyema drainage and decortication. Two layer closure of diaphragmatic tear was performed using non absorbable sutures while thickened parietal and visceral peel was removed for full expansion of trapped lung during decortications.

RESULTS

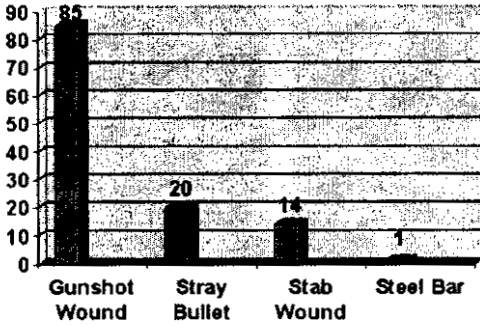
This study included 120 patients. There were 95(20.83%) males and 25(20.82%) females with male to female ratio of 3.8:1. All patients were adult. Their mean age was 28 years. Analysis of data revealed that gunshot wounds were more common than stab wounds. There were 105 patients with missile injury (85 gunshot wound and 20 straybullets) 4 stab wounds while 1 patient required admission for steel bar injury. (Table 1)

Right chest injury was more common than left (76:39), while there were three transmediastinal and 2 bilateral chest injuries. Out of 39 left sided injuries 20 were with GSW, 8 with stray bullet; 10 with stab injuries and one with steel bar injury. Right

MECHANISM

I	MECHANISM	No.	Percentage
A	a. Gunshot wound	85	(70.82%)
	b. Stray bullet	20	(16.60%)
B	Stab Wound	14	(11.66%)
C	Steel Bar	1	(0.83%)

TABLE - 1



side chest injuries included 60 GSW; 12 due to stray bullets and 4 stab wounds. Two bilateral and 3 transmediastinal were gunshot wounds (GSW) (Table 2)

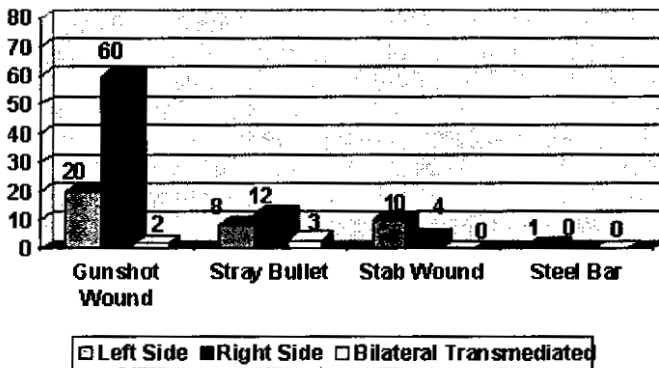
Clinical examination and radiologic investigations showed 78 patients with hemothorax, 25 with hemopneumothorax, 5 lung contusions, 4 chest wall injuries and only 1 having chylothorax. (Table 3)

These patients were individualized depending upon the clinical condition and type of injury. One hundred and ten patients were initially treated with tube thoracostomy who presented with variable clinical conditions including 78(65%) hemothorax; 25(20.83%) hemopneumothorax; 5(4.16%) pneumothorax and 1(0.83%) chylothorax. Three patients who continued to bleed after placement of tube thoracostomy and were hemodynamically unstable (tachycardia; hypotension and/or respiratory distress) proceeded to emergency thoracotomy. Two patients out of three died after emergency thoracotomy. Surgical exploration revealed extensive laceration of left lower lobe, left dome of diaphragm and spleen. In one patient who survived emergency thoracotomy, intercostals

LOCATION OF INJURY

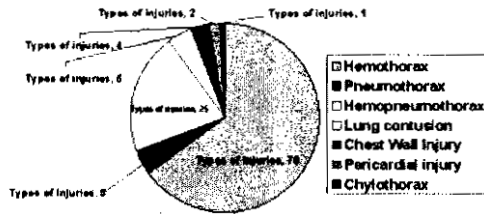
MECHANISM	LEFTSIDE	RIGHT SIDE	BILATERAL/TRANSMEDIATED
Gunshot wound (GSW)	20 (23.5%)	60 (70%)	2 Bilateral
Stray Bullet	8 (40%)	12 (60%)	3 transmediated
Stab Wound	10 (71.4%)	4 (28.5)	0
Steel Bar	1 (100%)	0	0
Total	39 (32.5%)	76 (63.3%)	5 (4.16%)

TABLE - 2



TYPES OF INJURIES	NO/PERCENTAGE
Hemothorax	78 (65)
Pneumothorax	5 (4.16)
Hemopneumothorax	25 (20.83)
Lung contusion	5 (4.16)
Chest Wall Injury	4 (3.33)
Pericardial injury	2
Chylothorax	1 (.83)

TABLE - 3



vessels were profusely bleeding. Over sewing sutures controlled bleeding. Nine patients underwent thoracotomy who developed various complications or had missed injuries (Table 3 & 4)

Three patients who continued to bleed after chest intubations and were hemodynamically unstable proceeded to emergency thoracotomy. Early thoracotomy was also performed in 9 patients who developed various complications or had missed injuries.

DISCUSSION

Chest trauma is one of the most common causes of major injury leading to death. Very few studies site specific incidence and epidemiology of penetrating chest injuries.²

Stab and gunshot wounds are responsible for majority of the patients with penetrating thoracic wounds. In our series gunshot wounds (GSW) were observed in 87.5% and stab injuries in 12.44% of patients. Hanif et al²¹ reported an equal incidence for gunshot and stab injuries. The high inci-

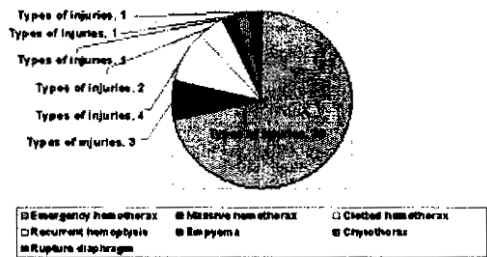
dence of gunshot wounds in our study is because of the easy availability and indiscriminate use of weapons on various occasions, cultural and tribal traditions. Males are more often involved in penetrating chest injuries. In our series male to female ratio was 3.8:1(95/25). Other studies^{18,20} have reported the same incidence.

Right sided wounds were more common (63.33%) than those on the left side particularly wounds due to missiles injuries, the reason being the fatal nature of these injuries where most of the patients, died before reaching hospital. Other series^{19,22} noted a higher incidence of left sided penetrating chest injuries. In these series it is observed that the victims are equally inflicted by gunshot and stab wounds irrespective of side of the chest. Unavailabil-

DIFFERENT LINES OF MANAGEMENT

GROUP OF PATIENTS	NO
Expectant (conservative)	10
Tube thoracostomy	110
Thoracotomy	
a. Emergency massive hemothorax	30
b. Massive hemothorax	3
c. Clotted hemothorax	4
d. Recurrent hemoptysis (foreign body; bullet)	2
e. Empyema	1
f. Chylothorax	1
g. Rupture diaphragm	1

TABLE - 4



ity of trained medical services at the scene and failure of prompt transportation in our circumstances are the factors resulting in death of critically left sided chest injuries before reaching hospital.

Hishberg et al¹⁸ have stressed upon the reliability of meticulous clinical and physical examination of the patients to establish diagnosis and institution of treatment. Others²¹ have stressed upon the role of chest radiography, fluoroscopy and echocardiography. All patients in our study were exposed to radiological examination and in only eight patients echocardiography was performed because of increased clinical and radiological suspicion of cardiac injuries. Demetriades et al¹⁵ and other investigators^{14,16} recommend tube thoracostomy as the initial line of management apart from resuscitation and hemodynamic stabilization. They reported 85% of patients being treated initially by tube thoracostomy. Our results are comparable to their observation. One hundred and ten patients (91.6%) were intubated resuscitated and observed.

In small number of patients with hemothorax, continued haemorrhage after tube thoracostomy will occur^{4,6,7,10}. Thoracotomy is required to provide hemostasis. Many formulas have been suggested but surgery is usually recommended if bleeding continues in amount that exceeds 200 ml/hour for more than 4 hours, accompanied with hemodynamic compromise. Out of one hundred and twenty patients; in our study; three (2.5%) were converted to emergency thoracotomy. Mansoor et al²³ and other studies^{7,9} reported higher (10-15%) incidence of emergency thoracotomy. The lower incidence of emergency thoracotomy in our study might be due to lack of on scene medical facilities and prompt transportation of seriously injured patients requiring emergency thoracostomy, who die on their way to hospital. In two of our patients continued haemorrhage was secondary to intercostals

artery injury while one also had splenic and diaphragmatic injury. Suture ligation and diathermy successfully arrested bleeding.

Thoracotomy is also required for complications or missed injuries. These include clotted hemothorax, empyema, chylothorax and rupture diaphragm. Smith et al²⁴ found that 18% hemothorax initially treated with tube thoracostomy developed clotted hemothorax and 39% of these patients eventually required decortications. They believe that early evacuation of hemothorax is of paramount importance in the prevention of empyema. This was done in 4 of our cases. Empyema occurs in 2% to 5% of thoracic injuries^{11,14,19} and residual hemothorax is thought to be a contributing factor. In our series one patient required decortication for empyema. Two symptomatic patients who had hemoptysis one with chylothorax and one rupture diaphragm also required thoracotomy. In summary our experience suggests, that majority of patients sustaining penetrating chest trauma can be managed by initial resuscitation and tube thoracostomy. Moreover thoracotomy has a definite role in a group of patients who continue to bleed after tube thoracostomy or later present with missed injuries or complications.

CONCLUSION

Penetrating thoracic trauma is a major cause of morbidity and mortality. Reduction in morbidity and mortality depends on avoidance of complications as well as early diagnosis of major injuries. Early thoracotomy is indicated for severely lacerated lung, clotted hemothorax, empyema, chylothorax and diaphragmatic injury.

REFERENCES

1. Wall; MJ Granchi, T; Linscum, K; Mathox; L Penetrating thoracic vascular injuries Surg-Clin-North-Am 1996; 76(4): 749-761.

2. Richardson, JD; Miller, FB; Carrillo, EH; Spain, DA. Complex thoracic injuries. *Surg Clin-North-Am.* 1996; 76: 725-748.
3. Ashraf S.S. - Grotte G. Penetrating chest injury in recent advances in surgery 18 by Taylor I and Johnson 1995; 69.
4. Washington B, Wilson RF, Striger Z. Emergency thoracotomy a four year review. *Ann of thoracic surgery* 40: 188; 1985.
5. Demetridides D Rabinowitz, Markides M. Indications for thoracotomy in stab wounds of the chest. A prospective study of 543 patients *B. J. Surg* 1996; 73: 888.
6. Rooney, SJ; Hyde, JAJ; Graham, TR; Toracic trauma. *Surgery.* 1996; 9-14.
7. Jurkovich, GJ; Esposito, TJ, Maier, R.V. Resuscitative thoracotomy performed in the operating room. *Am J Surgery* 1992, 163: 464-468.
8. Brown; SE; Gomez, GA; Jacobson, LE; Scheret; McMillan, RA Penetrating chest trauma: should indications for emergency room thoracotomy be limited. *Am J Surg* 1996; 62(7): 530-534.
9. Durhams, LA; Richardson, RJ; Wall, MJ; Emergency centre thoracotomy impact of prehospital resuscitation. *J trauma.* 1992; 32: 775.
10. Lewis, G; Knottenbelt, JD. Should emergency room thoracotomy be reserved for cases of cardiac tamponade *Injury* 1991; 22: 5-6.
11. Eddy AC, Luna GK, Gopass M Empyema thoracic in patients undergoing emergent closed tube thoracostomy for thoracic trauma *Am J Surg* ; 157: 494, 1989.
12. Worthington MG degroot, M; Funning, AJ; Von Oppelluo. Isolated thoracic duct injury after penetrating chest trauma. *Ann thorac Surg* 1995; 60(2): 272-274.
13. Jones K.W. Thoracic trauma *Surg Clinic North America* 1980; 60: 957.
14. Fallon, WF JR, Wears, R.L. Prophylactic antibiotics for the prevention of infectious complications including empyema following tube thoracostomy for trauma. *J trauma* 1992; 33: 110-117.
15. Smith RS; Fry, WR; Morabito DJ Preliminary report on video thoracoscopy in the evaluation and treatment of thoracic injury. *Am J Surg* 1993; 166: 690.
16. Graham, J.M; Mattox, KL and Beall, AC, Penetrating trauma of the lung. *J. Trauma* 1979; 19: 665.
17. Mattox KL. Thoracic trauma Glenn's thoracic and cardiovascular *Surg*, 5th edition, Appleton and lange 1991; P 91.
18. Hishberg A; Thomas, SR; Bade PG; Haizinga, WK. Pitfalls in the management of patients with penetrating chest trauma *Am J Surg* 1989; 157(4); 372.
19. O' Brien etal Cohen, M: Solit, R: et al Thorascopic drainage and decortication as definitive treatment for empyema thoracis following penetrating chest trauma. *J Trauma* 1994; 36: 536.
20. Bhopal FG, Khan MJS. Iqbal M. Penetrating chest injuries. *Pak Armed F Med J* 2000; 50(1): 29-31.
21. Hanif F, Mirza SM Chaudhary AM Reappraisal of thoracic trauma Pakistan *J Surg* 2000; 16(3-4): 25-8.
22. Mahmood T, Gondal KM, Abid KJ. Management of penetrating wounds of the power chest *Ann KE Med Coll* 2000; 6(1) (23-6)
23. Mansoor, MA, Moore, FE, Moore, F; Read, RR exigent post injury thoracotomy analysis of blunt versus penetrating trauma. *Surgery* 1992; 175: 97-101.
24. Smith, RS; Fry, WR; Tsoi EKM; Morabito, DJ; Kochper, RH; Preliminary report on videothoracoscopy in the evaluation and treatment of thoracic injury. *Am-J-Surg* 1993; 166: 690-695.

Address for Correspondence:

Dr. Mohammad Saleem Khan,
 Department of Cardiothoracic Surgery,
 Lady Reading Hospital,
 Peshawar.