

Disseminated cutaneous leiomyoma in a young male: A case report

Umer Mushtaq, Huma Saleem, Shahnawaz Hashmi

Department of Dermatology, Mayo Hospital, Lahore, Pakistan

Abstract Leiomyomas are rare benign tumours, arising most commonly from the arrector pili muscles (pilar leiomyomas), from tunica media of blood vessels (angioleiomyomas) or from genital skin muscles (dartoic leiomyomas). We report a case of disseminated cutaneous leiomyoma in a 26-year-old Asian male who presented with multiple red and dusty brown coloured firm nodules on his upper chest, left arm, left leg and upper back. The case was diagnosed on dermatopathology and with immunohistochemical studies. Considering the widespread disease, surgical excision was not possible. Patient improved symptomatically with pregablin and is under regular follow-up. We report this case because cutaneous leiomyoma is a rare disease and it usually does not present in a disseminated pattern.

Key words

Leiomyomas, nodules, disseminated pattern.

Introduction

Cutaneous leiomyomas are rare, benign tumours arising from the arrector pili muscle of hair follicles. According to the site of the origin, they are of three types: i) piloleiomyomas ii) angioleiomyomas iii) dartoic leiomyomas. Piloleiomyomas arise from the arrector pili muscle, angioleiomyomas arise from the vascular smooth muscles and dartoic arise from the smooth muscles of the genital skin.¹ These lesions may occur sporadically or as a part of an autosomal dominant cancer syndrome called 'Hereditary Leiomyomatosis and Renal Cell Cancer (HLRCC)'. Prior to the discovery of the association with RCC, the co-occurrence of uterine and cutaneous leiomyomas were known under several different eponyms like Reed syndrome, multiple cutaneous leiomyomas

(MCL), and multiple cutaneous and uterine leiomyomatosis syndrome (MCUL-1), leading to potential confusion regarding the associated cancer risk.²

Case Report

We are describing a case of a 23-year-old male, presented in the Dermatology department of Mayo Hospital, with a ten year history of multiple erythematous papules and nodules that started from his chest region, just below his left nipple. In a few days, they started growing in size and became painful. Then, they spread to involve his left arm, left leg and his back. They were associated with burning sensations and there was no history of pus or bloody discharge. The pain was aggravated with external pressure and in response to cold temperature. There were no alleviating factors and the mucosae were not involved. On systemic review, abdominal pain, gastroesophageal reflux disease, dyschezia and constipation were reported. There was no significant family history and past medical or surgical history.

Address for correspondence

Dr. Umar Mushtaq
Dermatology Department,
King Edward Medical University/Mayo Hospital,
Lahore
Email: umermushtaq16@yahoo.com

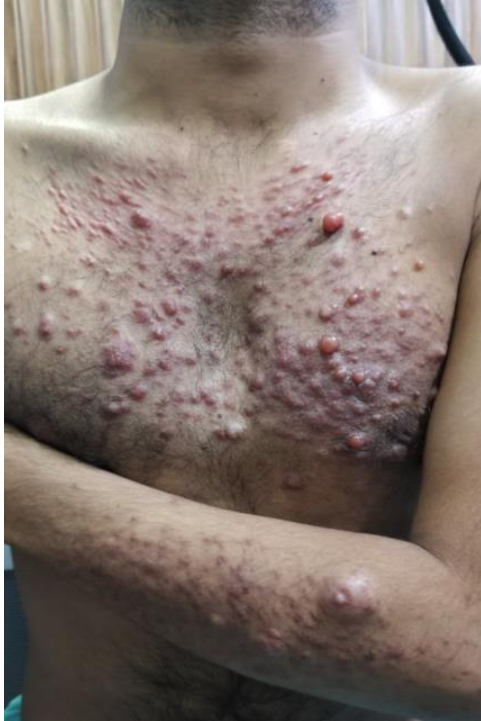

Figure 1 Multiple erythematous papules and nodules On chest and left forearm.

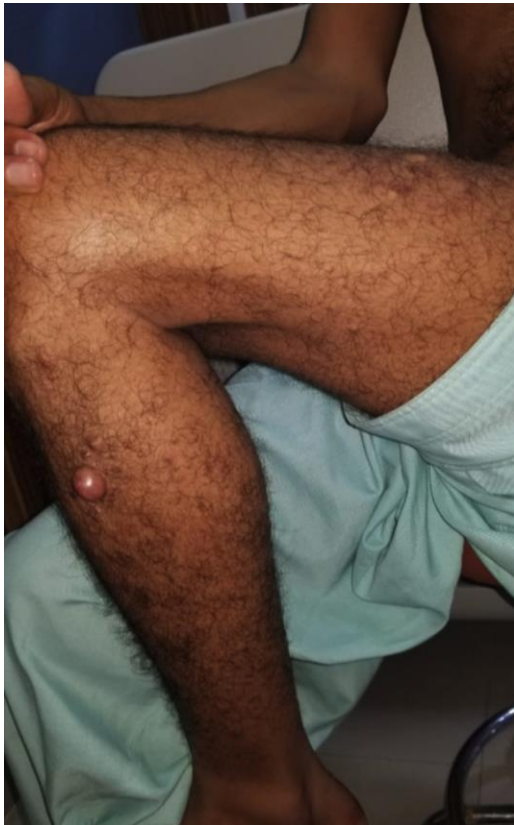

Figure 2 Large nodule (2x2 cm) on the lateral aspect of left lower leg.

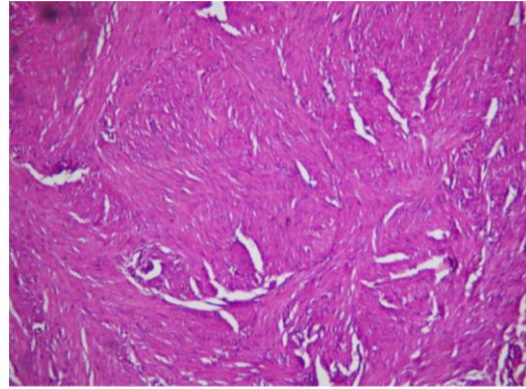


Figure 3 Uniform interlacing bundles of elongated cells in the dermis (Hematoxylin-eosin staining 40X).

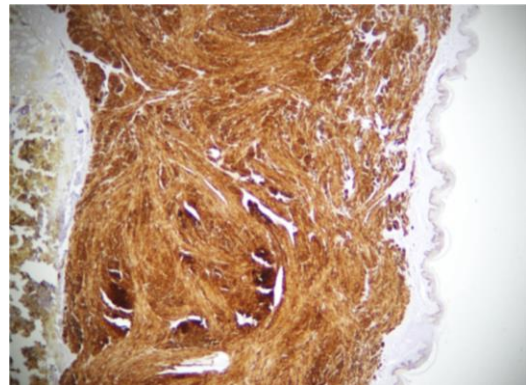


Figure 4 Immunohistochemistry showing positive staining for desmin.

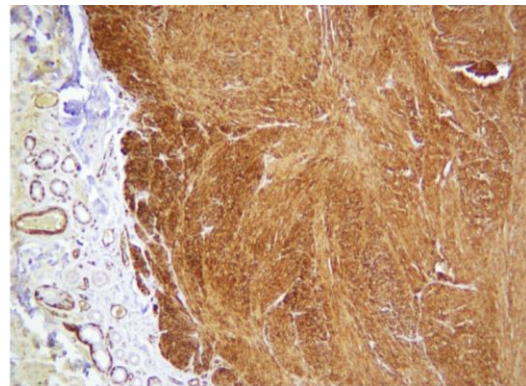


Figure 5 Immunohistochemistry showing positive staining for smooth muscle antigen.

On clinical examination, multiple erythematous papules and nodules were observed on upper chest, of which some had coalesced to form larger nodules. Few of them were bright red in colour, having prominent telangiectasias (**Figure 1**). Left upper back, left leg and left arm had similar multiple erythematous papules and

nodules which were firm in consistency, extremely tender and freely mobile over the underlying surface. There was one large nodule (2x2 cm) on the lateral aspect of left lower leg (**Figure 2**). Similarly, one large skin-coloured nodule (2.5x2 cm) was present on left arm, close to the elbow.

We performed a punch biopsy which, under microscopy on hematoxylin-eosin staining, showed uniform interlacing bundles of elongated cells in the dermis (**Figure 3**). These cells showed bright eosinophilic cytoplasm and cigar-shaped nuclei. There was no inflammation, mitotic activity or any pleomorphism. On immunohistochemical studies, the cells stained strongly positive for desmin (**Figure 4**) and smooth muscle actin (SMA) (**Figure 5**). All of these findings confirmed the diagnosis of leiomyoma.

Considering the widespread disease, surgical excision was not a feasible option. Patient improved symptomatically with pregabalin 100mg/day and is under regular follow-up

Discussion

Cutaneous leiomyomas are usually caused by mutations in the gene located on chromosome 1q42.2 that encodes "Fumarate Hydratase", a Krebs cycle enzyme responsible for the conversion of fumarate to malate.³ Pilar leiomyomas are the most common type of leiomyomas and range from 2-20mm in diameter. When multiple leiomyomas exist, they typically consist of red-brown grouped papules, commonly located on the trunk or the extremities.⁴ The hallmark clinical symptom of cutaneous leiomyomas is pain, reported in approximately 90% of patients. This may be provoked by ambient cold or ice provocation, light touch, pressure or incidental contact and may be sharp, shooting discomfort, or may have

an aching quality. Although pain is a consistent feature, its intensity may vary. A history of episodic pain upon cold exposure, rubbing or pressure is a classic sign. The mechanism of pain is poorly understood, but it may be related to neuropeptide release, pressure on nerve fibres within lesions or contraction of the arrector pili muscle.⁵ The diagnosis may be accomplished histopathology of the papule or nodule. They are usually characterised by interlacing bundles of smooth muscle cells in the upper dermis. Increased nerve density has been described with cutaneous leiomyoma lesions compared with the surrounding dermis.⁶ Surgical excision is the treatment of choice of solitary lesions. For patients having multiple lesions for which surgery cannot be attempted, several alternative ablative, topical or systemic treatments have been attempted. However, evidence of their efficacy is limited.⁷

In case report by Dilek *et al.*⁸ in Turkey, similar lesions of pilar leiomyoma were found on the back of a 10-year-old child but there was no limb involvement in that case. In another case report from Saudi Arabia by Bari,⁹ skin coloured, painful pilar leiomyoma lesions were reported in a zosteriform pattern on the back of a 23-year-old male.⁹ In India, Bandyopadhyay *et al.*,¹⁰ reported a case of a 32-year-old male who had segmental distribution of similar lesions bilaterally on his back.¹⁰

Piloleiomyoma is a rare type of cutaneous benign tumour. We reported this case because of some unique features we found in this case. Although pain is a characteristic of this case, our patient reported burning sensation as the predominant symptom, the papules on his back were in a dermatomal pattern and there was involvement of the limbs, as well. We considered excision of the disseminated nodules an impractical option. Patient improved

symptomatically with oral pregablin and is being followed up regularly.

References

1. Badaloe S, Van Geel M, Van Steensel MA, Bastida J, Ferrando J, Ferris LK *et al*. Diffuse and segmental variants of cutaneous leiomyomatosis: novel mutations in the fumarate hydratase gene and review of the literature. *Exp Dermatol*. 2006;**15**:735-41.
2. Lehtonen HJ. Hereditary leiomyomatosis and renal cell cancer: update on clinical and molecular characteristics. *Fam Cancer*. 2011;**10**:397.
3. Tomlinson IP, Alam NA, Rowan AJ, Barclay E, Jaeger EE, Kelsell D *et al*. Germline mutations in FH predispose to dominantly inherited uterine fibroids, skin leiomyomata and papillary renal cell cancer. *Nat Genet*. 2002;**30**:406.
4. Matthews JH, Pichardo RO, Hitchcock MG, Leshin B. Cutaneous leiomyoma with cytologic atypia, akin to uterine symplastic leiomyoma. *Dermatol Surg*. 2004;**30**:1249-51.
5. Pissoat L, Megahed M. Disseminated cutaneous leiomyomas. *Hautarzt*. 2012;**63**:363-5.
6. Raj S, Calonje E, Kraus M, et al. Cutaneous pilar leiomyoma: clinicopathologic analysis of 53 lesions in 45 patients. *Am J Dermatopathol*. 1997;**19**:2.
7. Christenson LJ, Smith K, Arpey CJ. Treatment of multiple cutaneous leiomyomas with CO2 laser ablation. *Dermatol Surg*. 2000;**26**:319-22.
8. Dilek N, Yuksel D, Sehitoglu I Saral Y. Cutaneous leiomyoma in a child: A case report. *Oncol Lett*. 2013;**5**:1163-4.
9. Bari AU. Zosteriform Cutaneous Leiomyoma: A Rare Cutaneous Neoplasm. *J Coll Physicians Surg*. 2012;**23**:586-7.
10. Bandyopadhyay D, Saha A, Bhattacharya S. Bilateral Multisegmental Zosteriform Leiomyoma Cutis: A Rare Entity. *Indian J Dermatol*. 2015;**60**:293-5.