

Case Report

Multiple eccrine hidrocystomas on face: a report of two cases

Mohammad Abid Keen

Dermatologist, Jammu and Kashmir Health Services, Anantnag, Jammu and Kashmir

Abstract Eccrine hidrocystomas are rare, benign, cystic lesions with a lining that resembles that of the eccrine sweat gland and may be solitary or multiple. Multiple eccrine hidrocystomas occur predominantly on the face as asymptomatic, skin-colored to bluish lesions associated with a chronic course and seasonal variability. Herein, two cases of eccrine hidrocystomas on face are reported in view of the rarity of this clinical condition.

Key words

Eccrine hidrocystomas, benign, sweat gland

Introduction

Eccrine hidrocystomas are benign cystic lesions which originate from eccrine gland ducts¹ predominantly located on the face - eyelid and cheek regions.^{2,3} They are classified into two types, namely apocrine and eccrine hidrocystomas according to their histological and presumed histogenetic derivation. These lesions are more frequent in females than males.⁴ They present as a 1-3 mm translucent yellowish to slightly blue cysts. Multiple cysts frequently present in periorbital, forehead and malar regions and progress under high temperature and excessive sweating. Therapeutic options include medical and surgical modalities. Surgical excisions, electrocutery, dermabrasion, topical and oral anticholinergic agents, botulinum toxin and pulsed-dye laser have been reported as treatment options in these cases.

Case reports

Case 1

A 54-year-old lady presented with multiple small, asymptomatic, translucent discrete lesions on her face for last one year, increasing in summer and reducing in winter. Cutaneous examination revealed multiple skin-coloured, shiny, papulovesicles present over the malar area of face, nose, around the eyes and mouth, ranging in size from 2-3mm (**Figure 1**). On puncturing with a disposable needle, clear watery fluid came out. A skin biopsy stained with haematoxylin and eosin showed dilated cystic spaces in upper dermis (**Figure 2**), which were unilocular and lined by flattened cuboidal cells in two layers. On the basis of clinical features and histopathology, a diagnosis of multiple eccrine hidrocystomas was made and the patient was treated with topical 1% atropine cream twice a day for two weeks.

Case 2

A 14-year old boy presented with multiple asymptomatic translucent papular lesions over nose, evolving over a period of one year, with an

Address for correspondence

Dr. Mohammad Abid Keen
Medical Officer and Dermatologist, Jammu and Kashmir Health Services, Anantnag, Jammu and Kashmir, India
E mail: keenabid31@gmail.com

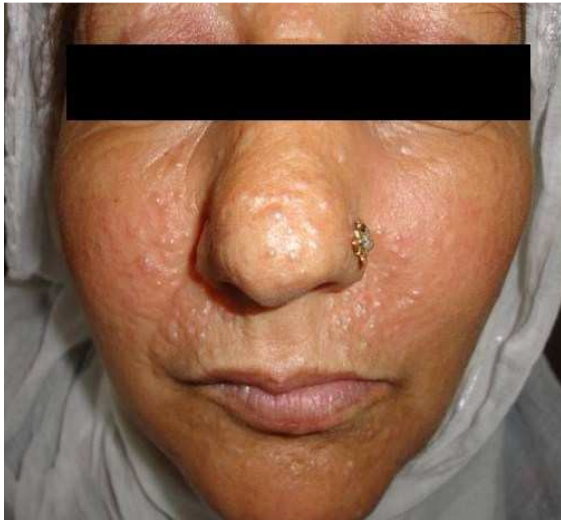

Figure 1 Multiple skin-coloured, shiny, papulovesicles present over the malar area of face, nose, around the eyes and mouth, ranging in size from 2-3mm.

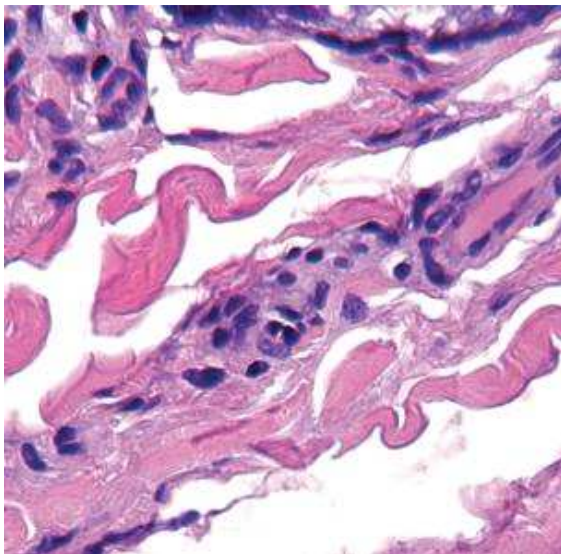


Figure 2 Haematoxylin and eosin stain (40x), showing dilated unilocular cystic spaces in upper dermis, lined by flattened cuboidal cells in two layers.

increase in size in summer and physical exercise, improving in winter. His review of systems, personal and family histories were all normal or noncontributory. Cutaneous examination revealed multiple shiny, translucent papules of 2-3 mm in diameter on the centofacial area [Figure 3]. On puncturing with a disposable needle, clear watery fluid came out.

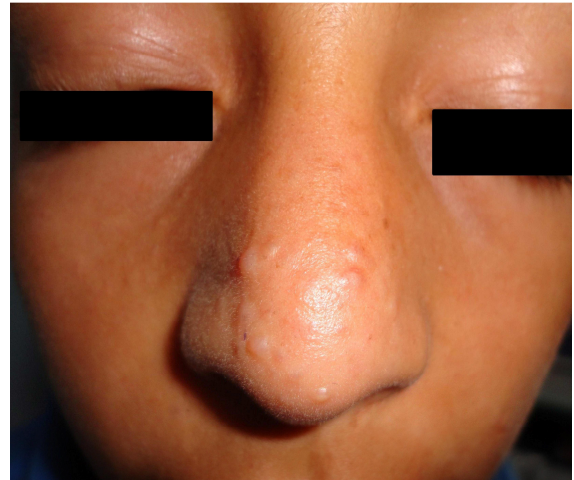

Figure 3 Multiple, shiny, translucent papules, 2-3 mm in diameter on the centofacial area.

Parents of the patient did not approve of any intervention in the form of excision for histopathology.

Discussion

Multiple eccrine hidrocystomas are rare, benign, cystic lesions occurring predominantly on the face, and associated with a chronic course and seasonal variation. Eccrine hidrocystomas are classified into 2 major groups: the Smith type, which is the most prevalent solitary type, and the Robinson, or multiple, type.^{5,6} They are typically dome-shaped, have an amber, brown, or bluish tint, and range from 1 to 6 mm in diameter. During hot or humid weather, these lesions will grow in size and/ or multiply in number. Eccrine hidrocystomas usually do not involve the eyelid margin but rather are distributed around the eyelid skin; this, along with a lighter color presentation, typically differentiates it from the apocrine type.⁷

The aetiopathogenesis is still debatable. Electron microscopy has established that the cyst wall is composed of ductal cells. It is likely that obstruction of eccrine duct leads to retention of sweat causing flattening of the lining cells and cystic dilatation.

Differentiation from apocrine hidrocystomas poses a problem both clinically and histologically. Apocrine hidrocystomas are often larger, darker blue in color and less likely to be periorbital. Histopathologically, eccrine hidrocystomas are lined by ductal cells which significantly differ from apocrine hidrocystomas. Eccrine hidrocystomas are usually unilocular, whereas apocrine hidrocystomas are multilocular. In contrast to apocrine hidrocystomas, decapitation secretion, periodic acid Schiff-positive and diastase-resistant granules in secretory cells and myoepithelial cells are absent in eccrine hidrocystomas. It is also important to differentiate eccrine hidrocystomas from sebaceous and epidermal inclusion cysts, cystic pigmented type of basal cell carcinoma, and milia.⁸

Treatment of eccrine hidrocystomas is recommended for cosmetic reasons. There is no definitive treatment of eccrine hidrocystomas. Avoidance of a hot and humid environment may prevent worsening of the condition. Different modalities have been proposed with variable results, which include puncture and drainage of the cyst that gives transient improvement with an early recurrence, surgical excision,⁹ microdermabrasion and electrodesiccation with high risk of scarring, pulse dye laser,¹⁰ topical atropine,¹¹ glycopyrrrolate¹² and scopolamine.¹³ Recently EH has been treated with botulinum toxin (injectable) with good results.¹⁴

References

1. Armstrong DK, Walsh MY, Corbett JR. Multiple facial eccrine hidrocystomas: Effective topical therapy with atropine. *Br J Dermatol.* 1998;**139**: 558-9.
2. Berke A, Grant-Kels JM. Eccrine sweat gland disorders: Part I - Neoplasms. *Int J Dermatol.* 1994;**33**:79-85.
3. Murayama N, Tsuboi R, Unno K, Ogawa H. Multiple eccrine hidrocystomas. *Br J Dermatol.* 1994;**131**:585-6.
4. Hashimoto K, Lever WF. Tumors of Skin Appendages. In: Fitzpatrick TB, Eisen AZ, Wolff K *et al.*, editors.). *Dermatology in General Medicine*, 4th edn. New York: McGraw-Hill; 1983. P. 550-1.
5. Robinson AR. Hidrocystoma. *J Cutan Genitourin Dis.* 1893;**11**:292-303. Cited in: Alfadley A, Aboud KA, Tulba A, Mourad MM. Multiple eccrine hidrocystomas of the face. *Int J Dermatol.* 2001;**40**:125-30.
6. Smith JD, Chernoskey ME. Hidrocystomas. *Arch Dermatol.* 1973;**108**:676-9.
7. Alfadley A, Aboud KA, Tulba A, Mourad MM. Multiple eccrine hidrocystomas of the face. *Int J Dermatol.* 2001;**40**:125-30.
8. Kaur C, Sarkar R, Kanwar AJ, Mohan H. Multiple eccrine hidrocystomas. *J Eur Acad Dermatol Venereol.* 2002;**16**:288-90.
9. Fariña MC, Piqué E, Olivares M *et al.* Multiple hidrocystomas of face; three cases. *Clin Exp Dermatol.* 1995;**20**:323-7.
10. Tanzi E, Alster TS. Pulsed dye laser treatment of multiple eccrine hidrocystomas: A novel approach. *Dermatol Surg.* 2001;**27**:898-900.
11. Khunger N, Mishra S, Jain RK, Saxena S. Multiple eccrine hidrocystomas. Report of 2 cases treated unsuccessfully with atropine ointment. *Indian J Dermatol Venereol Leprol.* 2004;**70**:367-9.
12. Smith DR, Mathias CG, Mutasim DF. Multiple eccrine hidrocystomas treated with glycopyrrrolate. *J Am Acad Dermatol.* 2008;**59**:S122-3.
13. Clever HW, Shal WJ. Multiple eccrine Hidrocystomas: A nonsurgical treatment. *Arch Dermatol.* 1991;**127**:422-4.
14. Correia O, Duarte A, Barros A, Rocha N. Multiple eccrine hidrocystomas - from diagnosis to treatment: the role of dermatoscopy and botulinum toxin. *Dermatology.* 2009;**219**:77-9.