

Neutral lipid storage disease-a case report

Ghazala Butt, Asia Bano, Sabrina Suhail Pal, Khawar Khurshid, Faria Asad, Zahida Rani

Department of Dermatology, Unit II, King Edward Medical University/Mayo Hospital, Lahore

Abstract Neutral lipid storage disease is a rare autosomal recessive disorder characterized by non-bullous ichthyosiform erythroderma, liver steatosis, hepatosplenomegaly, cataracts, ataxia, bilateral sensorineural hearing loss, skeletal and cardiomyopathy, growth and mental retardation. We report a case of neutral lipid storage disease in a 14 months old child.

Key words

Neutral lipid storage disease, non-bullous ichthyosiform erythroderma, Jordan's anomaly.

Introduction

Neutral lipid storage disease (NLSD) is an autosomal recessive disorder in which there are lipid droplets in almost all tissues.¹ It is caused by mutations in Adipose Triglyceride Lipase (ATGL) / PNPLA2 or Comparative Gene Identification (CG1-58) /ABHD5.²

CG1-58 mutations are always associated with ichthyosis.³ Neutral lipid storage disease was first described by Rosenszajn *et al.*⁴ in 1966 in two siblings who developed ichthyosiform erythroderma as the only abnormality. A total of 43 cases have been reported world wide till October 2010. We report a case of 14 months old child with congenital ichthyosis, organomegaly and lipid vacuoles in leukocytes.

Case Report

A 14-month-old male presented to us with erythroderma. Baby was born prematurely at 34 weeks of gestation. His skin was normal at birth. He developed jaundice at the age of 4 days for

which he received phototherapy. In the following week, the boy developed erythema and scaling which progressively led to erythroderma within days. The skin condition was slightly improved with emollients. When the baby was 10 months of age, he presented to pediatric emergency with watery diarrhea and abdominal distention. Investigations revealed hepatomegaly, for which a liver biopsy was performed which showed non-alcoholic steatohepatitis. When the diarrhea settled they referred the patient to skin department for the management of erythroderma. Significant in history was that the parents were first cousins. The child's milestone and intellect were normal.

Cutaneous examination revealed generalized erythema with scaling. On the trunk, the scales were small and yellowish white in colour while on the limbs they were large, polygonal and dirty yellow in colour. Ectropion was present. Nails and teeth were normal. The only finding on systemic examination was hepatomegaly.

Peripheral blood film showed fat vacuolization in neutrophils and eosinophils with positive Sudan Black staining. Liver function tests were deranged with bilirubin 2.9 mg/dl, aminotransferase 127 U/L, alanine transferase 98 U/L and alkaline phosphatase was 421 U/L.

Address for correspondence

Dr. Ghazala Butt
Department of Dermatology, Unit II,
King Edward Medical University/
Mayo Hospital, Lahore
E-mail: ghazalakashmiri@gmail.com

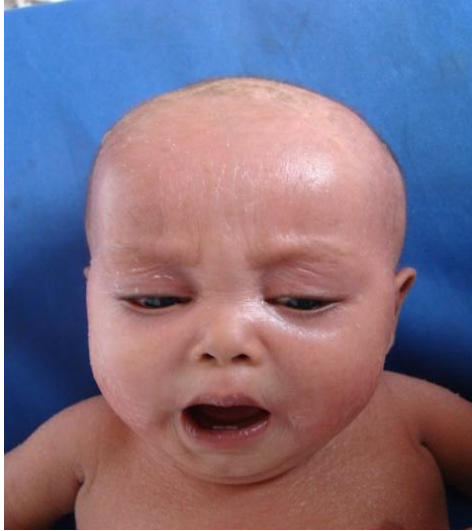

Figure 1 Erythema and scaling on face and scalp with ectropion.

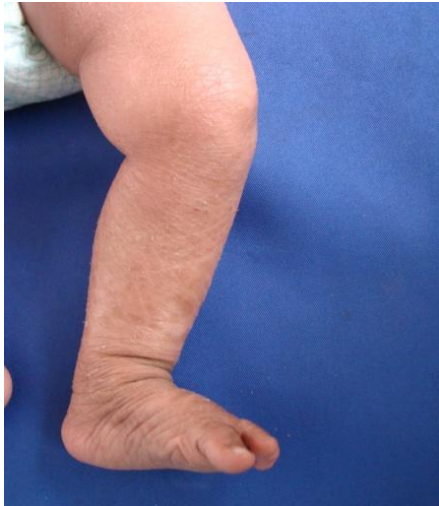

Figure 2 Ichthyosiform scaling on left leg and foot.

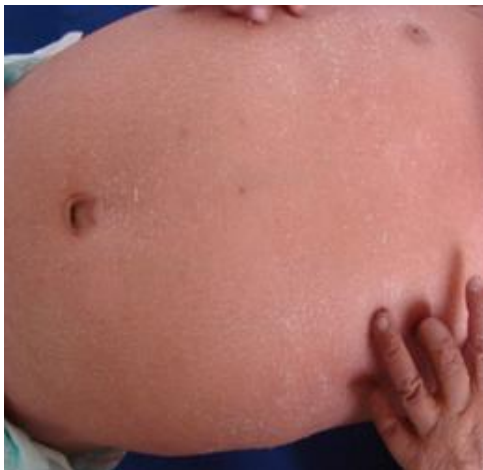

Figure 3 Abdominal distension with erythema and scaling.

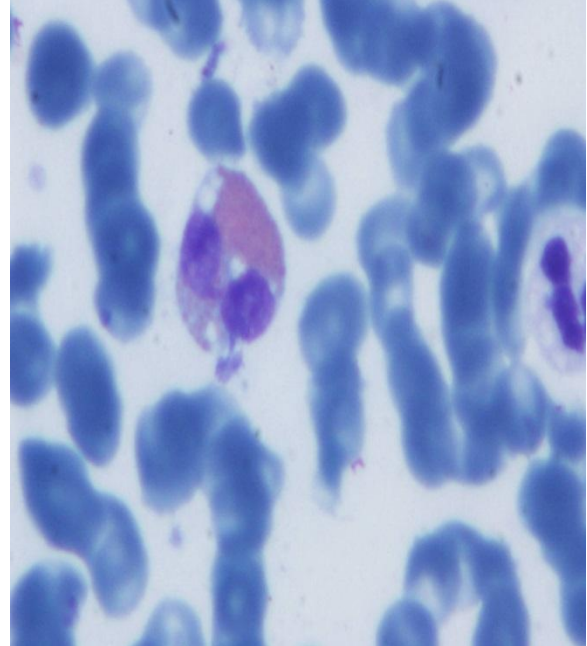


Figure 4: Peripheral blood smear stained with hematoxylin and eosin showing vacuolization in eosinophil and neutrophils.

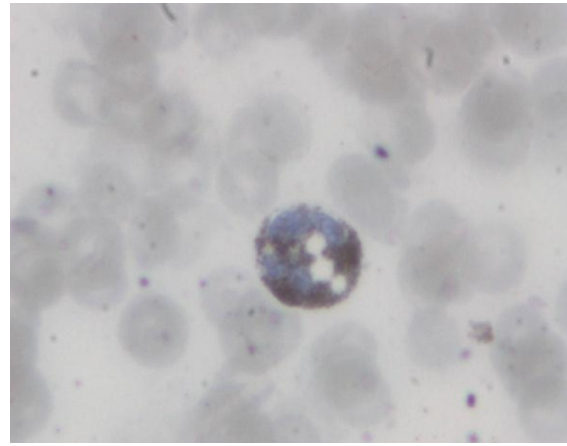


Figure 5 Peripheral blood smear stained with Sudan Black showing vacuolization in neutrophil.

urine complete, renal function tests, muscle enzymes (Aldolase, CPK, LDH), X-ray chest, prothrombin time, thromboplastin time and bone marrow tests were within normal limit. On abdominal ultrasound, focal fatty vacuolization in the liver and grade III renal parenchymal disease was present.

Skin histopathology was unremarkable except epidermal basal layer vacuolization.

Discussion

Neutral lipid storage disease (Chanarin-Dorfman syndrome) is a rare autosomal recessive lipid storage disease which is characterized by the deposition of triacylglycerol in multiple tissues including liver, skin, muscle, central nervous system and blood leukocytes.⁵ The majority of cases reported to date are from the Middle East.⁶

Clinical features are variable and include non-bullous ichthyosiform erythroderma, liver steatosis, hepatosplenomegaly, cataracts, ataxia, bilateral sensorineural hearing loss, skeletal and cardiomyopathy, growth and mental retardation.⁵

One of the diagnostic features is the presence of lipid containing vacuoles in leukocytes, which was originally discovered by Jordan *et al.*⁷ (Jordan's anomaly). Many reports stress the importance of visualizing leukocytes in every case of ichthyosis. The earliest report was in 1953 by Jordan.⁷ Reports by Rozenszajn *et al.*⁴ in 1966 and Elias and Williams⁸ in 1985 attracted attention to this syndrome. Elevation of muscle and hepatic enzymes along with lipid droplets in muscle and liver biopsy are also seen.⁹

The extent to which the vacuoles are seen in leukocytes and the degree to which deposition of fatty tissue occurs do not correlate with the severity of clinical presentation. In our case, patient showed steatohepatitis and grade III renal parenchymal disease which is a rare finding in patients of neutral lipid storage disease.

Chanarin-Dorfman syndrome mostly present as congenital ichthyosiform erythroderma but can also manifest as lamellar ichthyosis and erythrokeratoderma variabilis like picture.¹⁰ Our

patient presented with nonbullous ichthyosiform erythroderma.

The liver is affected in 64% of cases and mostly manifests as hepatomegaly with most common pathology being steatohepatitis,⁵ which was present in our patient.

Emollients and dietary modification remain the mainstay of treatment. Reduced long-chain fatty acids, increased medium-chain fatty acids, low protein and high carbohydrate diet are beneficial.

Ursodeoxycholic and vitamin E are given in steatohepatitis because of their cytoprotective and antioxidant effects. Our patient is using emollients, antioxidant along with dietary modification and is being followed up regularly.

References

1. Igal RA, Coleman RA. Neutral lipid storage disease: a genetic disorder with abnormalities in the regulation of phospholipid metabolism. *J Lipid Res.* 1998;**39**:31-43.
2. Schweiger M, Lass A, Zimmermann R *et al.* Neutral lipid storage disease: genetic disorders caused by mutations in adipose triglyceride lipase/PNPLA2 or CGI-58/ABHD5. *Am J Physiol Endocrinol Metab.* 2009;**29**:289-96.
3. Akiyama M, Sawamura D, Nomura Y *et al.* Truncation of CGI-58 protein causes malformation of lamellar granules resulting in ichthyosis in Dorfman-Chanarin syndrome. *J Invest Dermatol.* 2003;**121**:1029-34.
4. Rozenszajn L, Klajman A, Yaffe D, Efrati P. Jordan's anomaly in white blood cells: Report of case. *Blood.* 1966; **28**: 258-265.
5. Selimoglu MA, Esrefoglu M, Gul M *et al.* Chanarin Dorfman Syndrome: Clinical features of a rare lipid metabolism disorder. *Pediatr Dermatol.* 2009;**26**:40-3.
6. Pena-Penabad C, Almagro M, Martinez W *et al.* Dorfman-Chanarin Syndrome (neutral

- lipid storage disease): new clinical features. *Br J Dermatol.* 2001;**144**:445-8.
7. Jordans GH. The familial occurrence of fat containing vacuoles in the leukocytes diagnosed in two brothers suffering from dystrophia musculorum progressive. *Acta Med Scand.* 1953;**146**:419-26.
 8. Elias PM, Williams ML. Neutral lipid storage disease with ichthyosis: defective lamellar body contents and intracellular dispersion. *Arch Dermatol.* 1985;**121**:1000-8.
 9. Chanarin I, Patel A, Slavin G *et al.* Neutral lipid storage disease: A new disorder of lipid metabolism. *Br Med J* 1975;**1**:553-5.
 10. Pujol RM, Gilaberte M, Toll A *et al.* Erythrokeratoderma variabilis-like ichthyosis in Chanarin-Dorfman Syndrome. *Br J Dermatol.* 2005;**153**:838-41.