



Complete Clearance of Resistant Granuloma Faciale With Pulsed Dye Laser After Pre-treatment With Mometasone and Tacrolimus

Daniel Micallef^{1*}, Michael J Boffa²

¹Higher Specialist Trainee in Dermatology, Sir Paul Boffa Hospital, Harper Lane, Floriana FLR1940, Malta

²Consultant Dermatologist and Senior Lecturer in Dermatology, Sir Paul Boffa Hospital, Harper Lane, Floriana FLR1940, Malta

*Correspondence to

Daniel Micallef, M.D; Higher Specialist Trainee in Dermatology, Sir Paul Boffa Hospital, Harper Lane, Floriana FLR1940, Malta.
Tel: +35621234491;
Email: daniel.b.micallef@gov.mt

Published online 28 March 2017



Abstract

Introduction: Granuloma faciale is an uncommon inflammatory dermatosis which usually affects the face and is often resistant to treatment.

Case Report: A 39-year-old English lady with Fitzpatrick skin phototype II presented with typical lesions of granuloma faciale, confirmed on biopsy, on her cheeks and nose. Treatment with ScleroPlus pulsed dye laser (Candela Corporation, Wayland, Mass) produced no visible improvement. The patient re-presented 5 years later with the same lesions, now more prominent. No improvement was noted with topical mometasone, however addition of topical tacrolimus caused significant flattening. Since the erythema and telangiectases persisted, treatment with ScleroPlus pulsed dye laser was re-attempted. Treatments were performed with a wavelength of 595 nm, pulse duration of 1.5 ms and 7 mm spot at a fluence of 8.5 J/cm² in the first session and 9.5 J/cm² in the subsequent 2 sessions. This resulted in complete resolution without scarring or pigmentary change. There was no recurrence at follow-up one year later.

Conclusion: Our observation supports the use of combination therapy in resistant cases of granuloma faciale. One such combination would be the application of a topical corticosteroid and tacrolimus followed by pulsed dye laser.

Keywords: Lasers; Dye pulsed; Granuloma; Tacrolimus; Mometasone.

Introduction

Granuloma faciale is an uncommon, idiopathic, inflammatory dermatosis that usually affects the face.¹ Despite its benign nature, the condition tends to be persistent, can be cosmetically distressing and is notoriously difficult to eradicate completely.² We report a case of successful treatment of granuloma faciale using 595-nm pulsed dye laser following topical mometasone and tacrolimus.

Case Presentation

A 39-year-old English lady with Fitzpatrick skin phototype II, presented to our Dermatology Department with 3 sharply-demarcated, reddish-brown, indurated plaques with accentuated follicular openings and few superficial telangiectases. These were present on both cheeks and the tip of the nose. The patient had been previously diagnosed with granuloma faciale in the United Kingdom 6 months previously and was started on dapsone 50 mg daily, to which there was no visible response.

The patient then moved to Malta where dapsone was

stopped and the lesion on the right cheek biopsied. The biopsy showed a dense neutrophilic and eosinophilic infiltrate within the papillary and reticular dermis, with a prominent Grenz zone, confirming the diagnosis of granuloma faciale.

At this point, treatment with pulsed dye laser was attempted. A test area in the right cheek lesion underwent two treatments with a ScleroPlus pulsed dye laser (Candela Corporation, Wayland, Mass) with cryogen-spray dynamic cooling. A wavelength of 595 nm and pulse duration of 1.5 ms were used, with a 7 mm spot at a fluence of 8.5 J/cm² for the first session and 9.5 J/cm² for the second session, carried out after an interval of 8 weeks. There was no visible improvement with this treatment.

The patient was lost to follow-up but re-presented 5 years later with the same lesions, which by then had become more prominent. She was prescribed mometasone 0.1% ointment once daily for 2 months, with no visible improvement. Tacrolimus 0.1% ointment twice daily was then added to the mometasone ointment for another 2

months. This caused significant flattening of the lesions but the erythema and telangiectases persisted (Figure 1A and 1B). At this point, treatment with ScleroPlus pulsed dye laser with cryogen-spray dynamic cooling was re-attempted. Treatments were performed with a wavelength of 595 nm, pulse duration of 1.5 ms and a 7 mm spot at a fluence of 8.5 J/cm² in the first session and 9.5 J/cm² in the subsequent 2 sessions, after intervals of 8 weeks.

There was an impressive response to pulsed dye laser, with complete resolution of the lesions without scarring or pigmentary change (Figures 1 and 2). There was no recurrence at follow-up one year later.

Discussion

Granuloma faciale is an uncommon dermatosis characterized by one or more well-demarcated, infiltrated red-brown nodules or plaques, most commonly in adult Caucasian men.¹ Sites of predilection are the sides and tip of the nose (37%), the pre-auricular area (22%), cheeks (22%), forehead (15%) and helix of the ear (4%).³ Extra-facial involvement has been rarely reported. The condition may be difficult to diagnose clinically and in one study of 66 patients with histologically-confirmed granuloma faciale, it was suspected clinically in only 10 cases; the commonest differential diagnoses were sarcoidosis, lymphocytic infiltrates, lymphomas, basal cell carcinoma, fixed drug eruption, lupus erythematosus and erythema elevatum diutinum.⁴

Histological features of granuloma faciale include a dense inflammatory infiltrate in the upper two thirds of the dermis with a characteristic uninvolved Grenz zone beneath the epidermis and often around the pilosebaceous follicles.⁵ Blood vessels in the upper dermis are usually dilated and extravasation of erythrocytes and hemosiderin deposition is common.⁵

Several treatment options have been proposed for granuloma faciale; however, no modality has been shown to be consistently effective.³ Some degree of success has been reported with topical or intralesional corticosteroids, however, they rarely yield satisfactory long-term results.⁶ In addition, potential side effects particularly skin atrophy limit their prolonged use.³ Topical tacrolimus as monotherapy may also be helpful.⁷ It has been suggested that the accumulation of the inflammatory infiltrate in granuloma faciale is mediated by interferon- γ .⁸ Tacrolimus is thought to be useful, since it inhibits the release of this inflammatory mediator.⁸ While it has a favorable side-effect profile, most reports demonstrate incomplete resolution with this agent.⁸⁻¹⁰

There are isolated case reports on the use of systemic agents such as dapsone, colchicine, anti-malarials, isoniazid and clofazimine; however, they are neither consistently effective nor without risks of adverse effects.^{2,3}

Various lasers have been used to treat granuloma faciale, with variable efficacy. The carbon dioxide laser was one of the first lasers used.³ This laser causes non-selective vaporization of tissue with significant hypopigmentation and scarring.³ The more recent use of a scanning-

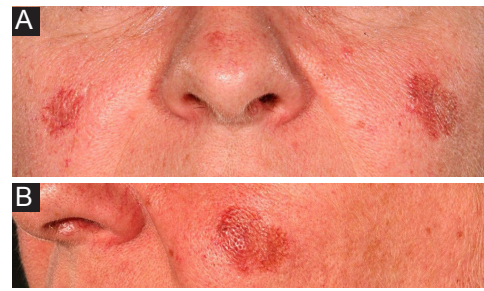


Figure 1. Photographs of the Lesions After Application of Topical Mometasone and Tacrolimus, Before Treatment With Pulsed Dye Laser.

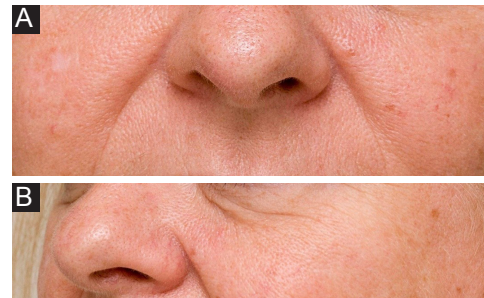

Figure 2. Photographs After 3 Treatment Sessions With Pulsed Dye Laser.

assisted CO₂ laser can however, reduce these adverse effects.¹¹ There are a few cases in which the argon laser was effective,¹² however, this benefit was limited by the development of collagenous scars.^{1,2} The 532 nm potassium titanyl phosphate (KTP) laser has also been reported to be useful, but only isolated case reports are available.²

The reddish-brown hue and telangiectases of granuloma faciale suggest that pulsed dye laser could be effective via selective photothermolysis affecting the microvasculature and immunologic activation of the treated skin.^{1,3} Short-term pain and bruising are common adverse effects of pulsed dye laser, but long-term side effects are minimal or absent.¹ The first 2 reported cases of granuloma faciale successfully treated with pulsed dye laser involved an 11-year-old child and a 41-year-old man.^{3,13} There are at least 8 other cases reporting a good response and 3 cases reporting a poor response to pulsed dye laser; however, complete resolution is unusual. In some cases, partial improvement was noted with potent topical corticosteroids used prior to laser therapy.¹ However, there are no case reports in which topical tacrolimus, with or without topical corticosteroids, was used prior to laser therapy.

Cutaneous vascular lesions that are thick, deep or raised above the skin surface may respond poorly to pulsed dye laser.¹⁴ In our case, pulsed dye laser was ineffective when the lesions were still raised and indurated. However, pre-treatment with topical mometasone and tacrolimus, which both target the inflammatory cascades, resulted in flattening of the lesions, which subsequently were fully eradicated with pulsed dye laser. To our knowledge, this is

the first reported case of such a combination being used prior to pulsed dye laser therapy.

Conclusion

While monotherapy is sometimes effective in granuloma faciale, complete clearance is unusual. Our observation supports using combination therapy, particularly in resistant cases. One such combination would be the application of topical anti-inflammatory agents (corticosteroid and tacrolimus), followed by treatment with pulsed dye laser.

Ethical Considerations

Written informed consent was obtained from the patient prior to treatment.

Conflict of Interests

The authors have no conflict of interest to declare.

References

1. Fikrle T, Pizinger K. Granuloma faciale treated with 595-nm pulsed dye laser. *Dermatol Surg*. 2011;37(1):102-104. doi:10.1111/j.1524-4725.2010.01823.x.
2. Ludwig E, Allam JP, Bieber T, Novak N. New treatment modalities for granuloma faciale. *Br J Dermatol*. 2003;149:634-637.
3. Ammirati CT, Hruza GJ. Treatment of granuloma faciale with the 585-nm pulsed dye laser. *Arch Dermatol*. 1999;135:903-905.
4. Ortonne N, Wechsler J, Bagot M, Grosshans E, Cribier B. Granuloma faciale: a clinicopathologic study of 66 patients. *J Am Acad Dermatol*. 2005;53:1002-1009.
5. Patterson JW. Granuloma Faciale. In: Patterson JW, ed. *Weedon's Skin Pathology*. Elsevier: Philadelphia; 2015:241-242.
6. Patterson C, Coutts I. Granuloma faciale successfully treated with topical tacrolimus. *Australas J Dermatol*. 2009;50:217-9.
7. Tomson N, Sterling JC, Salvary I. Granuloma faciale treated successfully with topical tacrolimus. *Clin Exp Dermatol*. 2009;34:424-425. doi:10.1159/000341196.
8. Jedlicková H, Feit J, Semrádová V. Granuloma faciale successfully treated with topical tacrolimus: a case report. *Acta Dermatovenerol Alp Pannonica Adriat*. 2008;17:34-36.
9. Tojo G, Fujimura T, Kambayashi Y, Kikuchi K, Aiba S. Successful treatment of granuloma faciale with topical tacrolimus: a case report and immunohistochemical study. *Case Rep Dermatol*. 2012;4(2):158-162. doi:10.1159/000341196.
10. Michajłowski I, Sobjanek M, Kozicka D, Dobosz M, Włodarkiewicz A. Granuloma faciale – analysis of 5 cases. *Post Dermatol Alergol*. 2011;28:36-40.
11. Madan V. Recurrent granuloma faciale successfully treated with the carbon dioxide laser. *J Cutan Aesthet Surg*. 2001;4:156-157.
12. Apfelberg DB, Druker D, Maser MR, Lash H, Spence B Jr, Deneau D. Granuloma faciale. Treatment with the argon laser. *Arch Dermatol*. 1983;119:573-576.
13. Welsh JH, Schroeder TL, Levy ML. Granuloma faciale in a child successfully treated with the pulsed dye laser. *J Am Acad Dermatol*. 1999;41:351-353.
14. Boffa MJ. Pulsed dye laser treatment of thick/raised vascular lesions using compression with clear plastic. *J Am Acad Dermatol*. 2003;49:879-881.