

What's Your Diagnosis?

Behrooz Barikbin^{1,2}, Azin Ayatollahi¹, Somayeh Hejazi¹, Hamid Reza Abaei¹

¹Laser Application in Medical Sciences Research Center, Shahid Beheshti University of Medical Sciences, Tehran, Iran

²Skin Research Center, Shahid Beheshti University of Medical Sciences, Tehran, Iran

Please cite this article as follows:

Barikbin B, Ayatollahi A, Hejazi S, Abaei HR. What is your diagnosis? J Lasers Med Sci. 2011;2 (3):129-30

*Corresponding Author: Somayeh Hejazi, MD, Resident of Dermatology, Department of Dermatology, Skin Research Center, Shahid Beheshti University of Medical Sciences, Tehran, Iran. Tel: +98-21 22741507; E-mail: dr.s.hejazi@gmail.com

A 52-year-old man with the complaint of telangiectasia on his nose from 6 years before presented at our clinic. Figure 1 shows his preoperative image.

After one session of one of the procedures, the lesion faded away nearly completely, as shown in Figure 2.

Which procedure do you think has been used for this patient?

The answer is that the Intense Pulsed Light (IPL) was used for removing this telangiectasia.

Our system is a fourth generation of IPL technology that is a long pulse system. The IPL

used in our case has a wavelength of 572 nm and pulse duration of 55 milliseconds. The energy used for this patient was 36J/cm², and the procedure was performed in 3 consecutive pulses. After one treatment session, the telangiectasia faded away nearly completely.

Generally, telangiectasias is classified into four types: linear, arborizing, spider and punctiform, or papular. Linear and arborizing telangiectasias with the size of 0.1-1.0 mm in diameter, frequently occur on the face, particularly the nose, cheeks and the chin. Factors such as chronic sun exposure, hormones (in particular estrogen), pregnancy, physical stress and (rarely) genetic disorders are among the causes of telangiectasia (1).

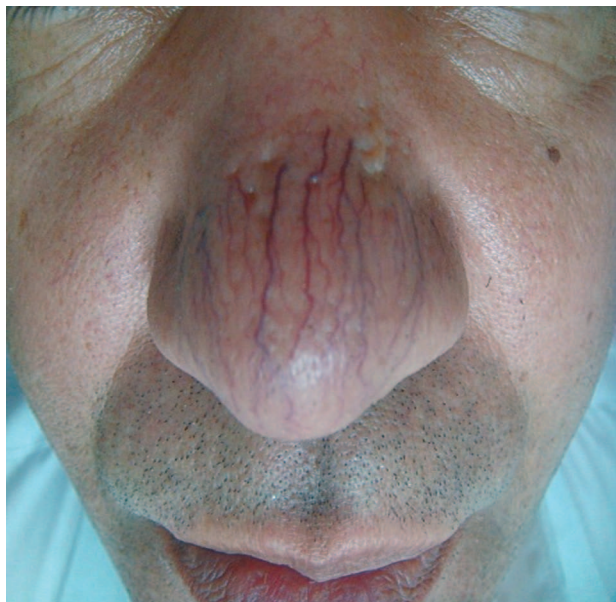


Figure 1. Nose telangiectasia before treatment

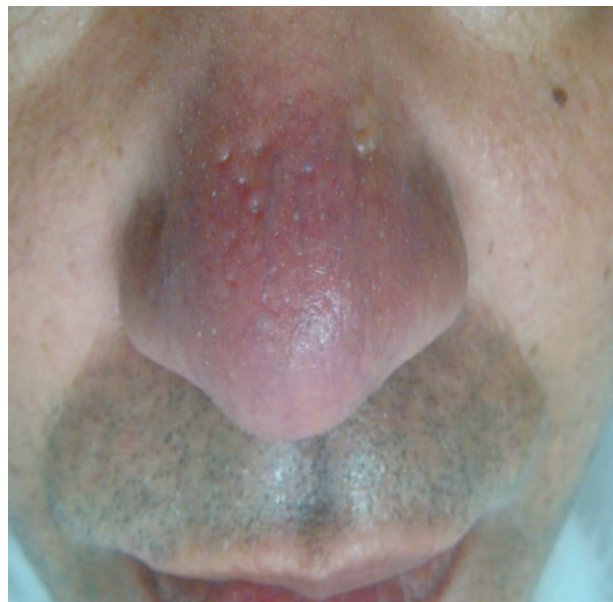


Figure 2. Nose telangiectasia after treatment

Intense Pulsed Light (IPL) is a high energy broad spectrum light source that is very effective in treating facial telangiectasia. It acts like a laser, causing internal damage to the blood vessels which then gets blocked off by selective photothermolysis (2). It has many advantages over treatment with lasers.

IPL treatment is well tolerated by adults and the treatment time is short. Anesthesia is not needed usually. The treated area will be erythematous, but clears by 48 hours. Sometimes, there is some bruising, but it remains only for a short time. Another advantage of IPL is the availability of a choice of filters which allows us to use different wave lengths to affect blood vessels at varying skin depths. Lightening of skin due to some absorption of the IPL light by melanin in skin is beneficial, but it would be dangerous for dark skin types. With shorter wavelengths, the risk of skin burn would be higher. In our case, we chose 572 nm rather than 535 nm for reducing the risk of burning.

As it has been mentioned in different studies, IPL is an effective and safe treatment protocol for facial telangiectasias (3-6).

Although there are studies which have found PDL treatment to be advantageous compared with IPL (7), in our experience IPL is a very effective and safe method for treating telangiectasia; we have also the advantage of lacking purpura. So, the risk of post inflammatory Hyperpigmentation will be decreased in dark skin patients.

PDL causes vessel rupture; thus, some purpuric lesions may appear at the treatment site (8,9). In contrast, IPL can deliver light energy over longer pulse durations, which may lead to more uniform heating and coagulation throughout the vessel in its entirety (2), so the vessel will be occluded and there is no purpura at the site of treatment. When there is no purpura, the risk of post inflammatory dyspigmentation is reduced and this is very

important in skin types such as types III and IV of Fitzpatrick.

After one treatment session, our patient's telangiectasia disappeared.

No side effects such as purpura or erythema and bruising were seen.

References

1. Alexiades-Armenakas MR, Dover JS, Arndt KA. Laser Therapy. In: Bologna JL, Jorizzo JL, Rapini RP, Horn TD, Mascaró JM, Mancini AJ, et al (eds). *Dermatology*. Edinberg: Mosby; 2008:2104-5.
2. Lennox KP, Goldberg DJ, Pozner JN. Intense Pulsed Light. In: Dibernardo BE, Pozner JN, Codner MA. *Laser and Non-surgical rejuvenation*. Saunders:Elsevier;2009:47-56.
3. Bjerring P, Christiansen K, Troilius A. Intense pulsed light source for treatment of facial telangiectasias. *J Cosmet Laser Ther* 2001; 3(4):169-73.
4. Acarturk TO, Stofman GM. Treatment of the vascular lesions of the face and neck using selective vascular photothermolysis with intense pulse light. *Eur J Plast Surg* 2003;26:319-23.
5. Schroeter CA, Haaf-von Below S, Neumann HA. Effective treatment of rosacea using intense pulsed light systems. *Dermatol Surg* 2005; 31(10):1285-9.
6. Clementoni MT, Gilardino P, Muti GF, Signorini M, Pistorale A, Morselli PG, Cavina C. Facial teleangeectasias: our experience in treatment with IPL. *Lasers Surg Med* 2005;37(1):9-13.
7. Nymann P, Hedelund L, Haedersdal M. Long-pulsed dye laser vs. intense pulsed light for the treatment of facial telangiectasias:a randomized controlled trial. *J Eur Acad Dermatol Venereol* 2010;24(2):143-6.
8. Svaasand LO, Aguilar G, Viator JA, Randeberg LL, Kimel S, Nelson JS. Increase of dermal blood volume fraction reduces the threshold for laser-induced purpura: implications for port wine stain laser treatment. *Lasers Surg Med* 2004; 34(2):182-8.
9. Burns JA, Kobler JB, Heaton JT, Anderson RR, Zeitels SM. Predicting clinical efficacy of photoangiolytic and cutting/ablating lasers using the chick chorioallantoic membrane model: implications for endoscopic voice surgery. *Laryngoscope* 2008; 118(6):1109-24.