

# Direct Vision Internal Urethrotomy with Application of Holmium: YAG Laser

Mohammad Reza Razaghi, Mohammad Mohsen Mazloomfard, Babak Javanmard, Reza Mohammadi, Anahita Ansari Jafari

Laser Application in Medical Sciences Research Center, Shahid Beheshti University of Medical Sciences, Tehran, Iran

## Abstract

**Introduction:** Male urethral stricture is a complicated urologic disease that could be successfully treated using internal urethrotomy. Laser internal urethrotomy has been used in many cases with favorable outcome in many studies. Holmium: YAG laser with its incisional properties on tissue is one of the laser types applied for internal urethrotomy.

**Methods:** We present a 19 year-old male with history of aortic valve stenosis and metallic aortic valvoplasty on prescription of oral anti-coagulant therapy (Warfarin) who was a candidate for internal urethrotomy due to bulbar urethral stricture. Holmium laser core-through urethrotomy was performed for him.

**Results:** Internal urethrotomy was done using the ablative 50-watt Holmium: YAG laser 2140 nm (manufactured by the Atomic Energy Organization of Iran [AEOI]). No complication was observed intra- and post-operatively. After 6 months of follow-up no evidence of urethral stricture was observed.

**Conclusion:** According to our study, Ho-YAG laser core through urethrotomy is a safe and effective procedure. It is a less invasive alternative to more complex urethroplasty procedures for patients with post-traumatic urethral stricture with high risk of urethral bleeding due to anti-coagulant therapy.

**Keywords:** urethra; urethral strictures; holmium-YAG lasers; lasers, solid-state

---

Please cite this article as follows:

Razaghi MR, Mazloomfard MM, Javanmard B, Mohammadi R, Ansari Jafari A. Direct vision internal urethrotomy with application of holmium: YAG laser: J Lasers Med Sci 2011;2(3):126-8

---

\*Corresponding Author: Mohammad Mohsen Mazloomfard, M.D; Shohada-e-Tajrish Medical Center, Tajrish Sq, Tehran, Iran. Tel: +98-2122718001; Fax: +98-2188526901; Email: mazloomfard@yahoo.com.

## Introduction

Any process that injures the urethral epithelium or the underlying spongiosum to the point that healing results in a scar can cause a urethral stricture. Iatrogenic trauma, any inflammatory process like gonorrhoea or Lichen Sclerosus (BXO) and other reasons can cause urethral stricture (1). The patient with urethral stricture most often presents with obstructive voiding symptoms. The treatment of urethral stricture diseases includes numerous reconstructive surgical techniques (2).

Male urethral stricture can be successfully treated using internal urethrotomy (IU), which is fast and simple to perform, and is associated with a short convalescence (3). The procedure involves single cold-knife incision at the 12-o'clock position through the scar to healthy tissue to allow the scar to expand, and the lumen to heal with enlarged lumen. The goal is for the resultant larger luminal caliber to be maintained after healing (4). Modifications of this technique aimed at increasing its efficacy and safety include substituting the cold knife for a hook electrode; laser urethrotomy using argon,

neodymium-doped yttrium aluminium garnet (Nd: YAG), KTP 532 nm or diode lasers; and targeted incision of dorsal or ventral fibrosis, as demonstrated by ultrasound (5,6).

Laser energy has been used as an alternative to electrocautery to incise the urethral stricture during recent years. Laser energy vaporizes the tissue resulting in an incision. The ideal type of laser is the one that totally vaporizes tissue, exhibits negligible peripheral tissue destruction, is not absorbed by water, and is easily propagated along a fiber (1). Holmium: YAG laser with its incisional properties on tissue is one of the laser types applied for internal urethrotomy (7).

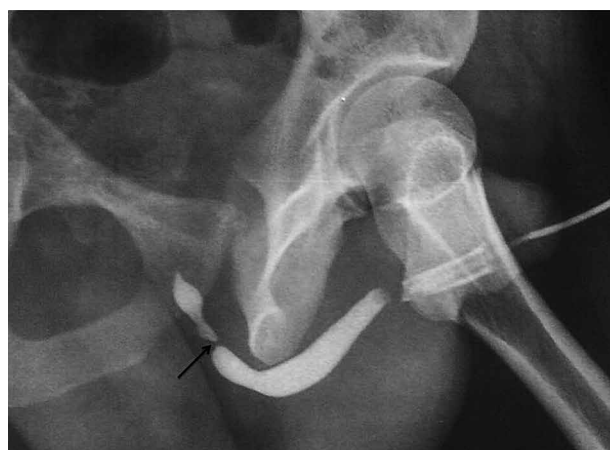### Case Report

The patient is a 19-year old male with history of aortic valve stenosis who underwent three major procedures of valvoplasty. Due to metallic aortic valve, anti-coagulant therapy (Warfarin) was prescribed. He suffered from urinary retention after every operation; so he had to undergo clean intermittent catheterization (CIC) for a long time. Gradually, urinary obstructive symptoms presented, and urethral stricture was established. He had undergone internal urethrotomy 2 years before in another center, but it had been unsuccessful.

Renal function tests were normal, and there was no evidence of urinary infection, pyuria, or microscopic hematuria in urine analysis and culture. Simultaneously, retrograde urethrography (RUG) and voiding cystourethrography (VCUG) was performed for him that revealed stricture at bulbar urethra (Figure 1). Due to the high risk of bleeding, the patient was a candidate for direct vision internal urethrotomy with the application of Ho: YAG laser.

### Surgical Technique

Oral anti-coagulant was changed to IV heparin 2 days before surgery; moreover, heparin was stopped 6 hours preoperatively. The patient underwent intravenous (IV) sedation in the operating room, and rigid cystoscopy with video camera was performed for him. When the cystoscope reached the stricture, flexible tip of guide-wire was introduced per urethra and advanced from the pinpoint lumen with a kind steady force under



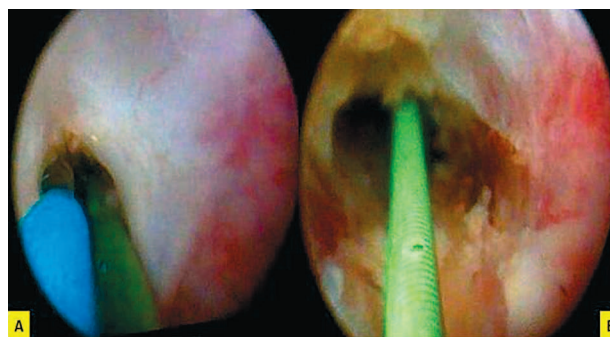
**Figure 1.** The patient's retrograde urethrography revealing a bulbar stricture (black arrow)

direct vision (Figure 2A).

Internal urethrotomy was done using the ablative 50-watt Holmium: YAG laser 2140 nm (manufactured by the Atomic Energy Organization of Iran [AEOI]). All the fibrotic tissues were cut around the guide-wire in order to pass a 17 Fr rigid cystoscope (Figure 2B). After the procedure, an 18Fr siliconized Foley catheter was inserted for the patient. He was discharged from the hospital on the same day of operation without any complications, such as perineal hematoma, extravasation of irrigation fluid into the perispongiosal tissues and impotency.

The Foley catheter was removed 7 days post urethrotomy, and CIC was advised according to our protocol. CIC protocol was tapered over a 6-month period. He was visited regularly in the clinic and no evidence of relapse was observed after 6 months of follow-up.

### Discussion



**Figure 2.** Endoscopic appearance of urethral stricture A: Guide-wire laser fiber tightly passed through the urethra before operation. B: Opening of urethral lumen post urethrotomy.

Urethral stricture is a complicated disease representing a therapeutic challenge. The choice of reconstructive technique depends on the stricture length, degree of spongio fibrosis, and surgeon's preference and experience. However, minimally invasive methods are performed more commonly than any open urethroplasty technique. Altogether, in the treatment of urethral stricture disease, both the patient and the physician must have a good understanding of the goal of treatment before the treatment choice is made (8-10). The most common methods used for urethral strictures in United States were dilation (92.8%), IU (85.6%), endourethral stent (23.4%), and laser urethrotomy (19%), according to Bullock's study (11).

Laser internal urethrotomy has been used in many cases with a good outcome in many studies. Dogra et al had conducted core through urethrotomy with Ho: YAG laser for 8 patients with post traumatic stricture of bulbomembranous urethra. 7 cases revealed stricture-free urethra in cystourethroscopy follow-ups (1). Also, Hossain et al used Ho: YAG laser for the treatment of 30 male patients with short segment anterior urethral stricture (less than 2cm) and after 3 months, 27 patients showed good flow of urine (Qmax more than 16 ml/sec) and adequate urethral caliber in RUG (12). In another study, Futao et al by applied Ho: YAG laser in endoscopic internal urethrotomy, and achieved satisfactory results in 25 cases (of 28 patients) without complications (13).

According to our study, Ho-YAG laser core through urethrotomy is a safe and effective procedure. It is a less invasive alternative to more complex urethroplasty procedures for patients with post-traumatic urethral stricture with high risk of urethral bleeding due to anti-coagulant therapy. It can be carried out as a day care procedure in carefully selected patients, and has no complications. Using this technique in large series and clinical trials will support this theory.

## Conclusion

Core through urethrotomy with the contact Ho: YAG laser seems to be a safe and effective treatment

option for selective strictures. The hospital stay is remarkably short and complications are negligible.

## Reference

1. Dogra PN, Ansari MS, Gupta NP, Tandon S. Holmium laser core-through urethrotomy for traumatic obliterative strictures of urethra: initial experience. *Urology* 2004; 64(2):232-5.
2. Pansadoro V, Emiliozzi P. Internal urethrotomy in the management of anterior urethral strictures: long-term follow-up. *J Urol* 1996;156:73-5.
3. Naud'eAM, HeynsCF. What is the place of internal urethrotomy in the treatment of urethral stricture disease? *Nat ClinPract Urol* 2005;2(11):538-45.
4. Jordan GH, Schlossberg SM. Surgery of penis and urethra. In: Wein AJ, Kavoussi LR, Novick AC (Eds). *Campbell-Walsh urology*, 9th edn. Saunders: Philadelphia; 2007.1055-75.
5. Tomschi W, Suster G, Hörtl W. Bladder neck strictures after radical retropubic prostatectomy: still an unsolved problem. *Br J Urol* 1998;81(6):823-6.
6. Becker HC, Miller J, Nöske HD, Klask JP, Weidner W. Transurethral laser urethrotomy with argon laser-experience with 900 urethrotomies in 450 patients from 1978 to 1993. *UrolInt* 1995;55(3):150-3.
7. El-Nahas AR, Shoma AM, Eraky I, El-Enawy MR, El-Kappany HA. Prospective, randomized comparison of ureteroscopic endopyelotomy using holmium: YAG Laser and balloon catheter. *J Urol* 2006;175(2):614-8.
8. Peterson AC, Webster GD. Management of urethral stricture disease: developing options for surgical intervention. *BJU Int* 2004;94(7):971-6.
9. Berger AP, Deibl M, Bartsch G, Steiner H, Varkarakis J, Gozzi C. A comparison of one-stage procedures for post-traumatic urethral stricture repair. *BJU Int* 2005; 95(9):1299-1302.
10. Hosseini J, Tavakkoli Tabassi K. Surgical repair of posterior urethral defects. *Urol J* 2008;5(4):215-22.
11. Bullock TL, Brandes SB. Adult anterior urethral strictures: A national practice patterns survey of board certified urologists in the United States. *J Urol* 2007;177(2):685-90.
12. Hossain AZ, Khan SA, Hossain S, Salam MA. Holmium laser urethrotomy for urethral stricture. *Bangladesh Med Res Counc Bull* 2004;30(2):78-80.
13. Futao S, Wentong Z, Yan Z, Qingyu D, Aiwu L. Application of endoscopic Ho: YAG laser incision technique treating urethral strictures and urethral atresias in pediatric patients. *PediatrSurg Int* 2006;22(6):514-8.